

Introduction to Swan-Ganz catheterization

David Stultz, MD


Cardiology Fellow, PGY-IV


August 11, 2003

Internship

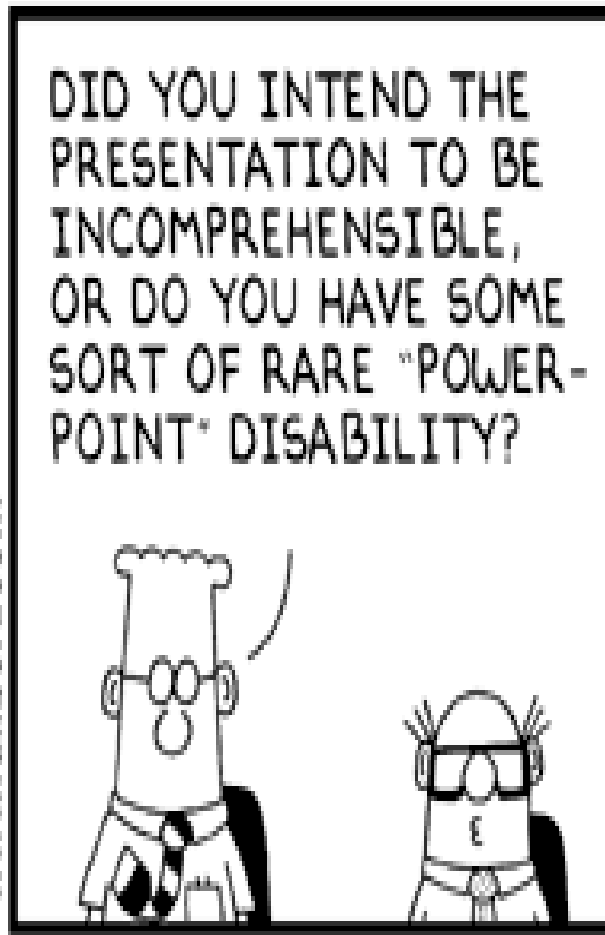
Nurstoons

by Carl Elbing

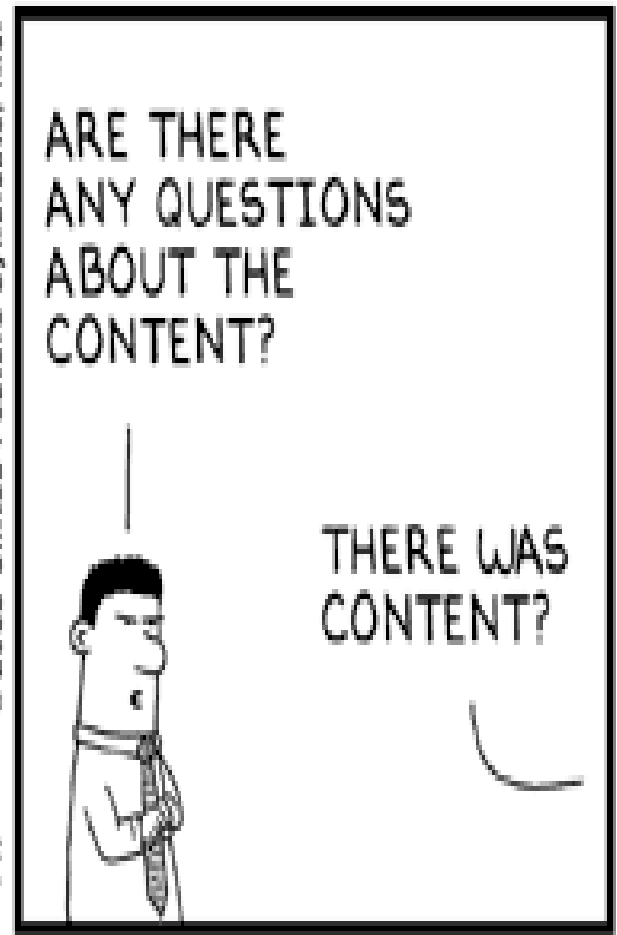




www.dilbert.com ecottadams@aol.com



8/1/03 © 2003 United Feature Syndicate, Inc.



Topics to be covered

- Should I even be using a PA catheter, and if so, in whom should I use them?
- How do I place a Swan-Ganz?
- What information do the numbers tell me?
- When can the numbers be misleading?
- What complications should I be aware of?

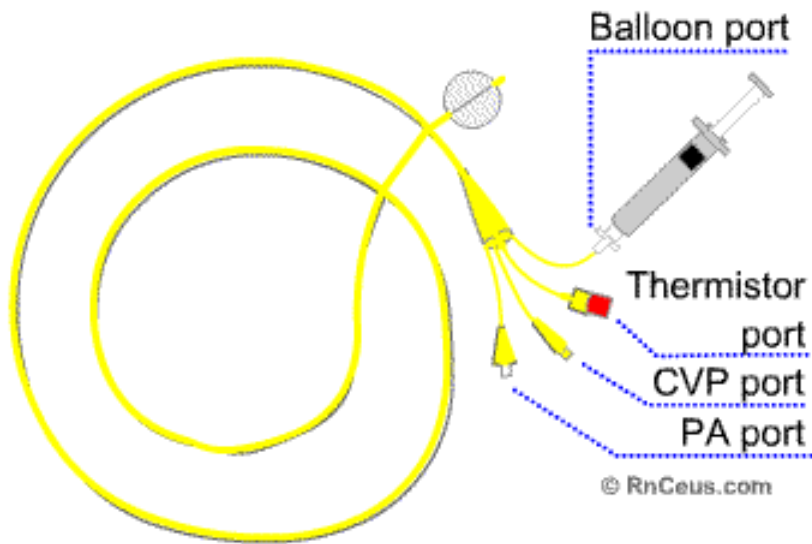
A Perspective

- 1930's Wiggers and Katz advocate application of physiological principles toward management of cardiovascular disease
- 1940-1950's Cardiac catheterization developed, applicable only in specialized labs
- 1960's ICU developed, critical care emerges
- 1970 Balloon tipped "flow directed" catheter approach used for right heart catheterization

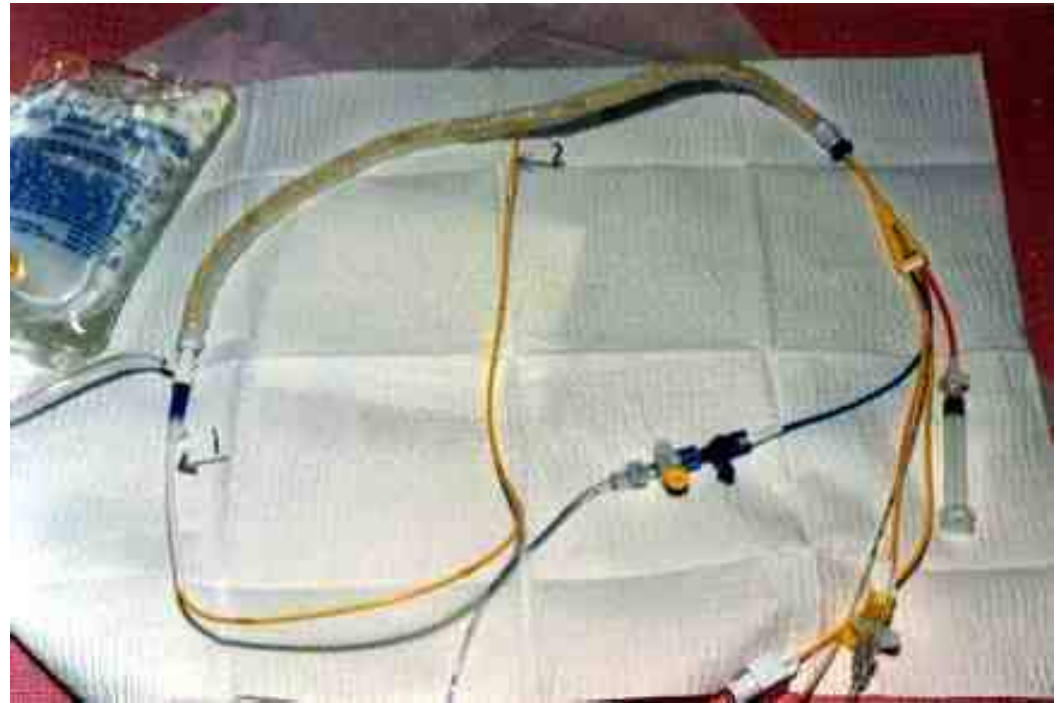
The Swan-Ganz Catheter

AKA Right Heart Catheter

AKA Pulmonary Artery Catheter



<http://www.rnceus.com/hemo/pacath.htm>



- 7.5 French (2.31 mm diameter)
- 110 cm Long
- Black rings at 10 cm intervals

Ports

- Distal
- Right Atrial (30 cm from tip)
- Venous infusion (31 cm from tip)
- Thermister Bead (5 cm from tip)

Information to be gained

- Cardiac output (thermodilution)
- Central temperature
- RA, PA, PCWP pressures
- Blood gas
- *Pacing
- *Continuous cardiac output

Should I use a PA catheter?

- In summary, studies have never demonstrated mortality benefit from the use of Swan-Ganz catheters
- Swan-Ganz use continues mainly due to criticisms of studies and perceived benefit in selected patients

Why are PA catheters used in the critical care setting?

- Aid in differentiating mechanism of shock
 - Sepsis
 - Cardiogenic
 - Hypovolemic
- Monitor fluid status
 - CHF
- Diagnose Other Cardiac Abnormalities
 - Tamponade
 - Valvular Regurgitation

Who is an appropriate candidate for a PA catheter?

- In general, use in critically ill patients when stability of their condition cannot be assessed by clinical indicators
 - Persistent hypotension despite adequate fluid resuscitation
 - Pulmonary edema not responding to diuresis
 - Pulmonary edema with hypotension or pulmonary hypertension
 - Respiratory failure with high PEEP settings



WANTED TO PLAY

Osamu!

I WAS JUST PREPPING HIM FOR SURGERY!



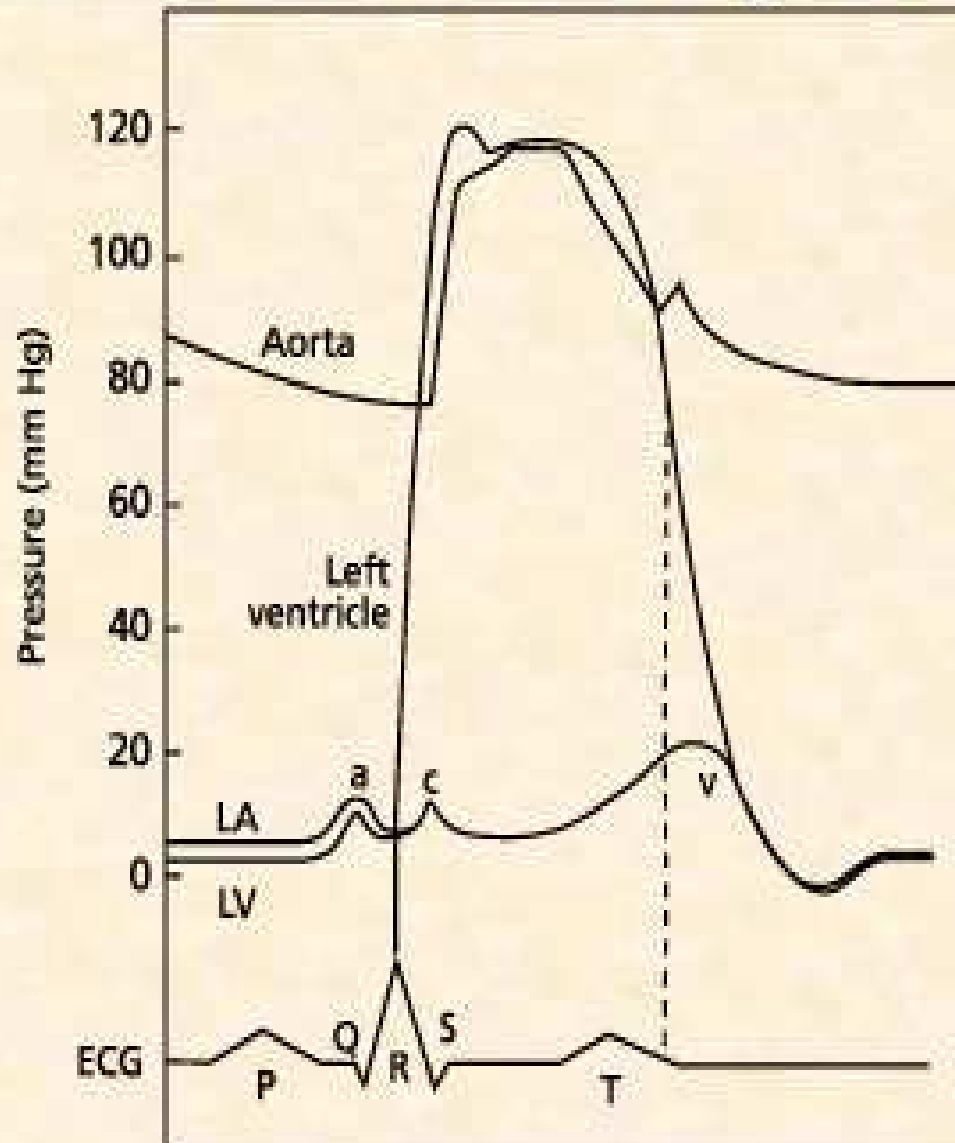
How do I place a PA Catheter?

- Acquire central venous access with an 8.5F introducer
 - Right IJ and Left Subclavian are preferred sites
 - Right Subclavian can be used
 - Left IJ is difficult without fluor
- Test balloon (1–1.5cc air)
- Flush all ports

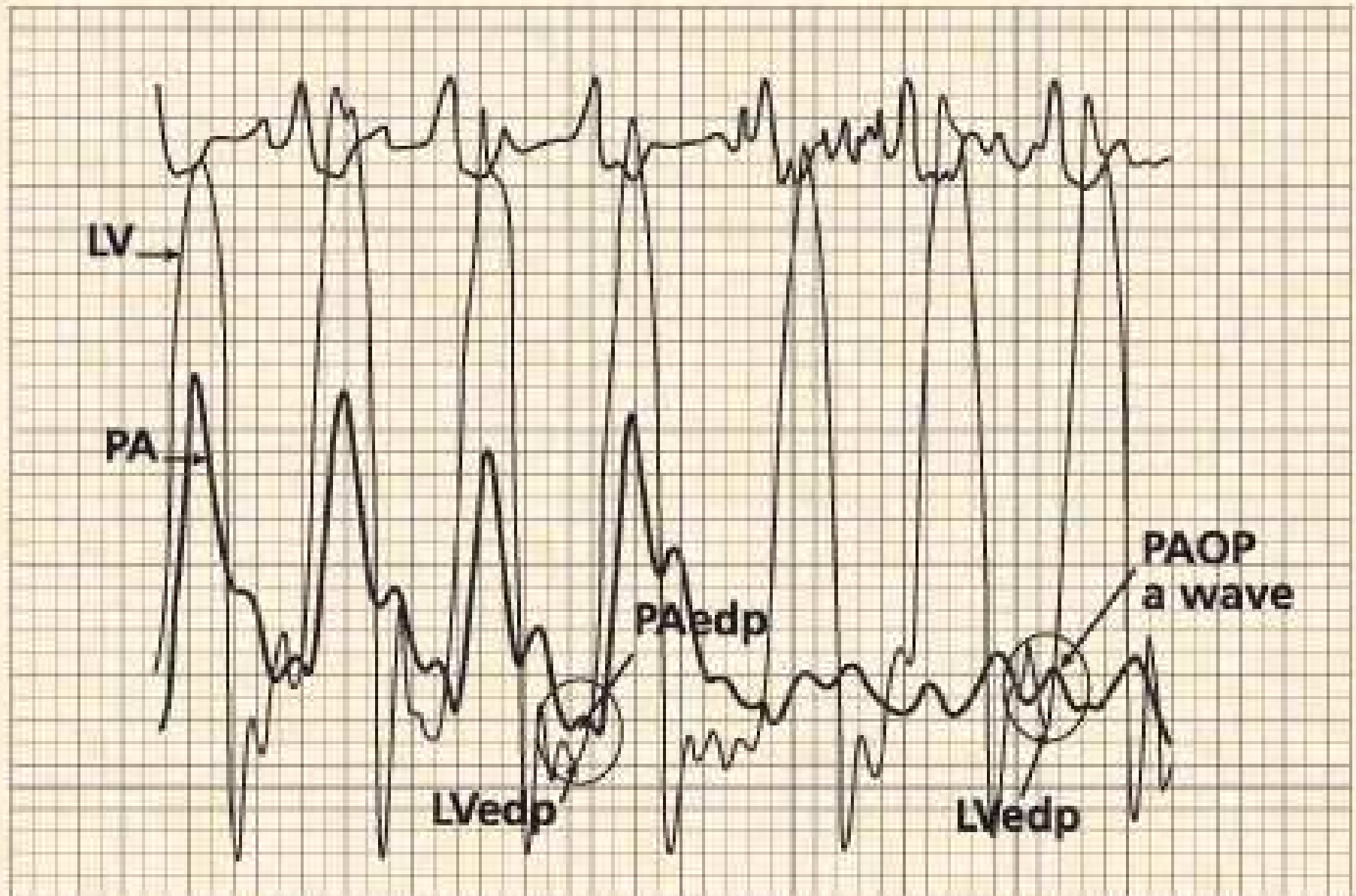
Placing a PA Catheter

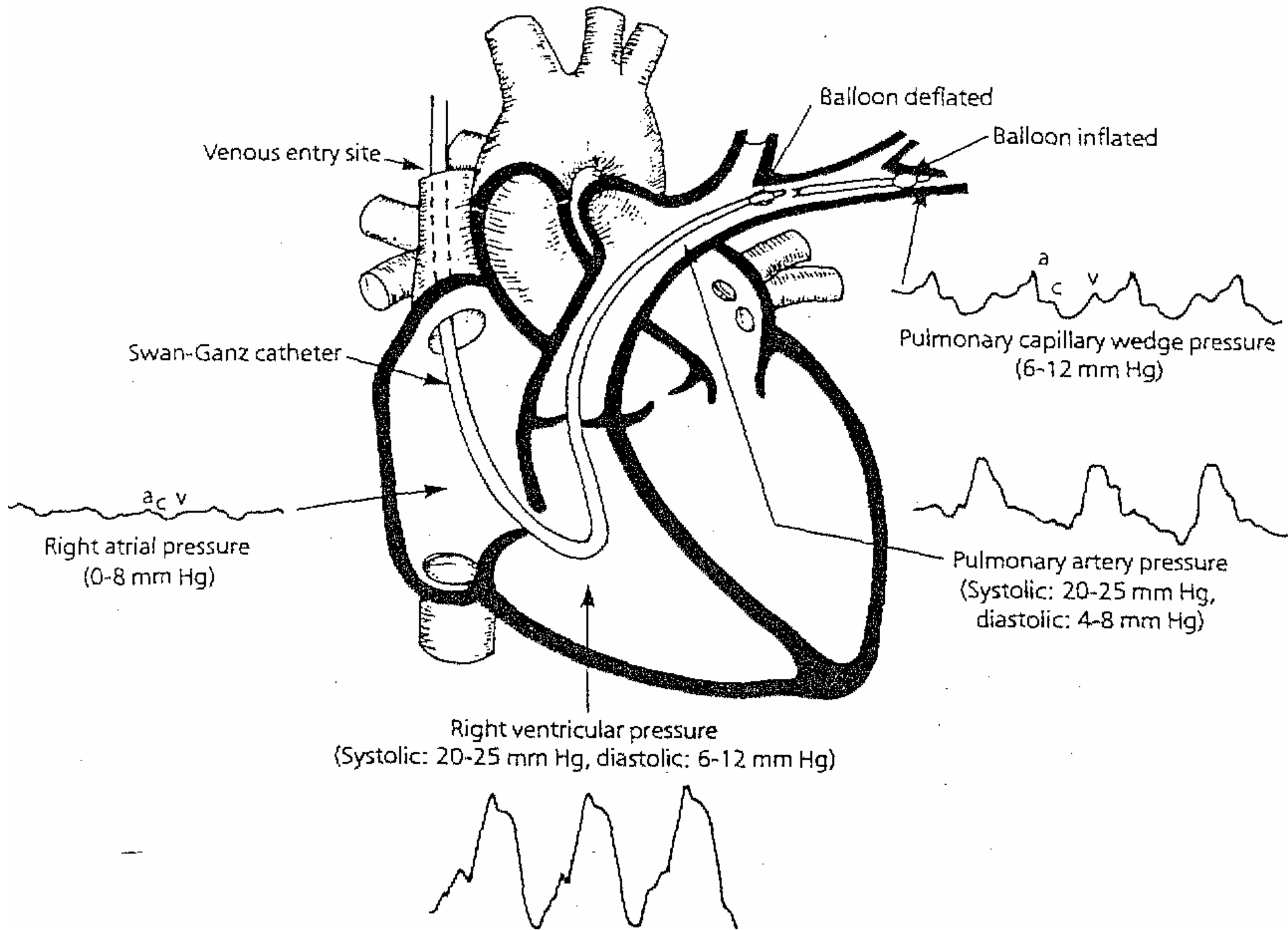
- Attach transducer
- Place protective sleeve over catheter
- Insert tip of catheter into the introducer
- Advance 15 cm, then call for “Balloon up”
 - Always advance with balloon up, withdraw with balloon down
- Watch waveforms
- In general, catheter will advance 45-55 cm

The Cardiac Cycle



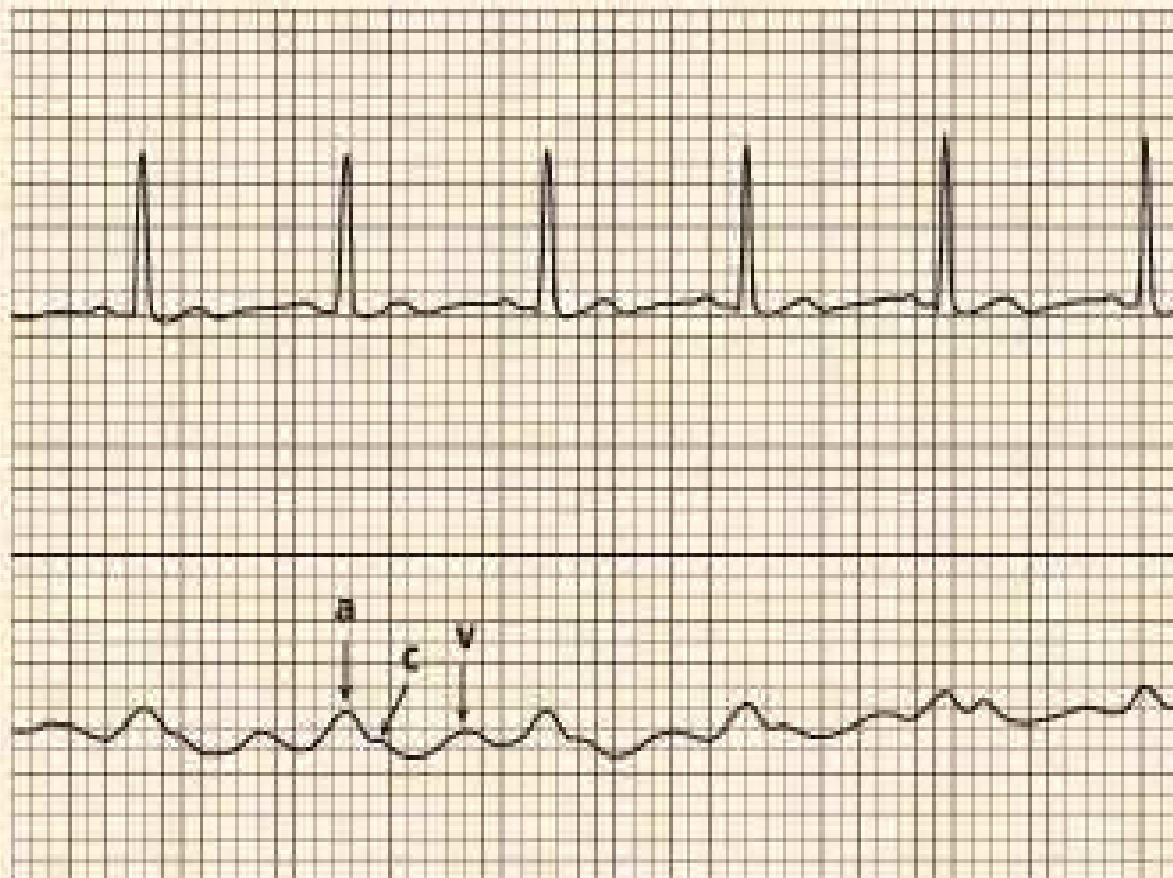
PAedp and PAOP \approx LVedp



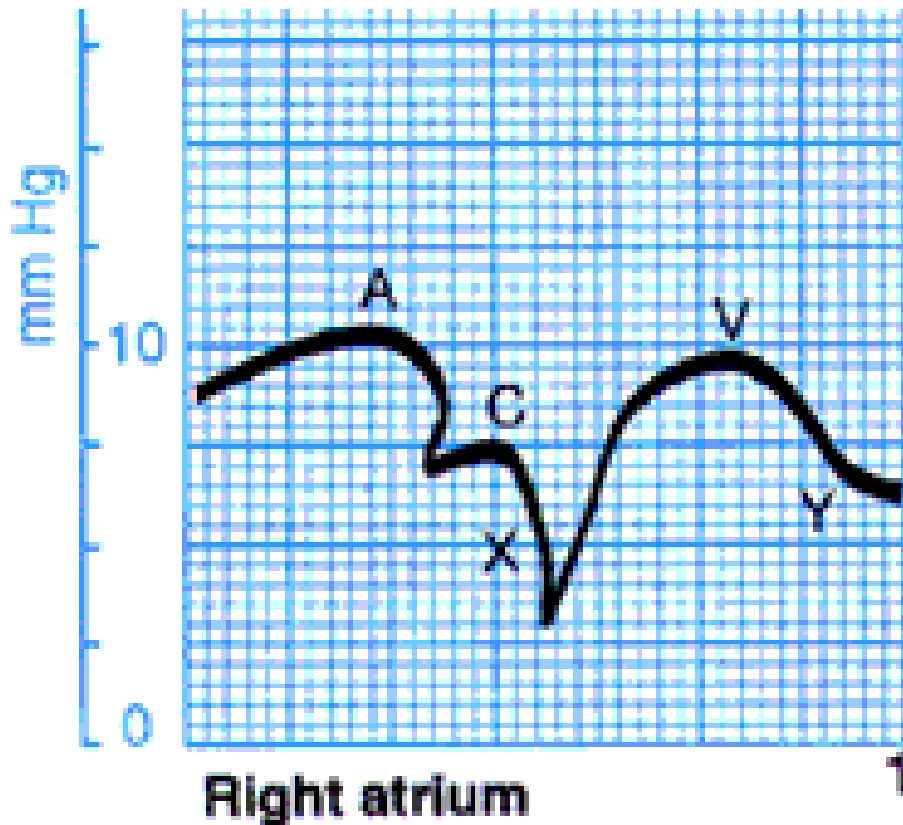


CVP/RA Waveform

- a wave - occurs with atrial contraction
- c wave - occurs with closure of tricuspid valve
- v wave - due to blood filling the atrium when the tricuspid valve is closed

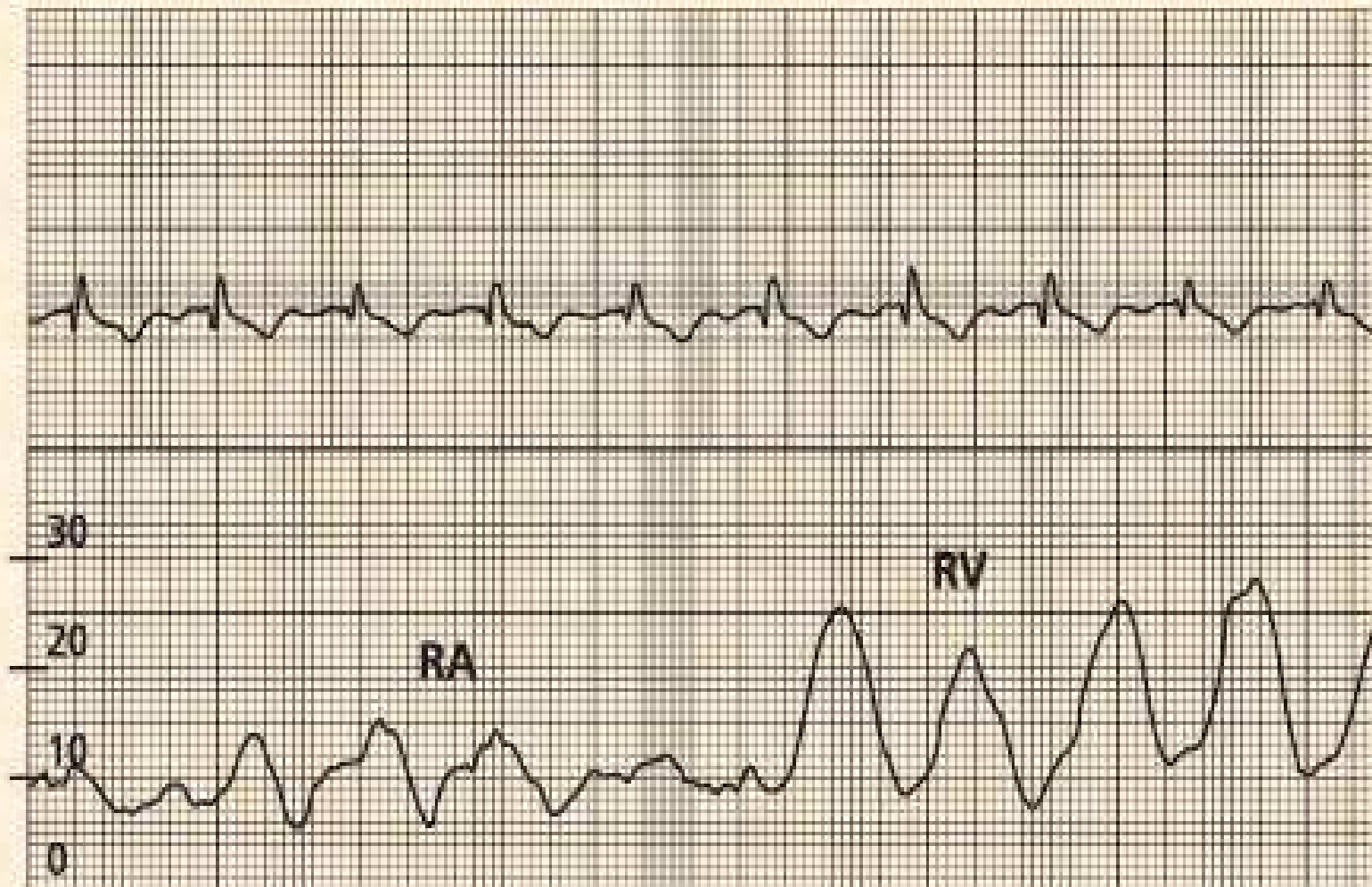


Right Atrial Waveform

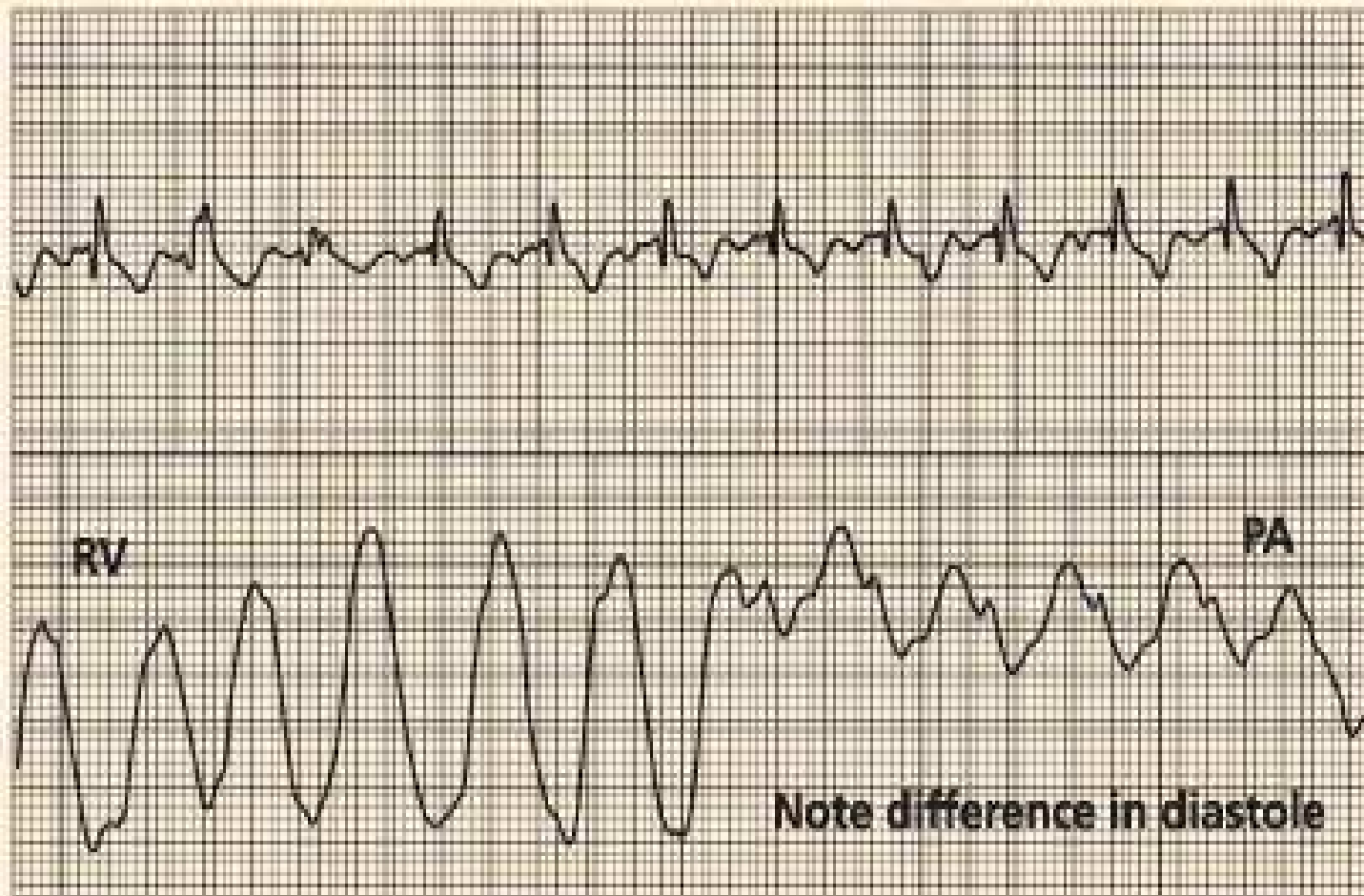


- a wave** - RA contraction
elevated in RV failure
- c wave** - tricuspid closure
- v wave** - passive filling of RA during ventricular systole = T wave on ECG
elevated in tricuspid regurgitation
- x descent** - atrial diastole
- y descent** - atrial emptying

RV Waveform

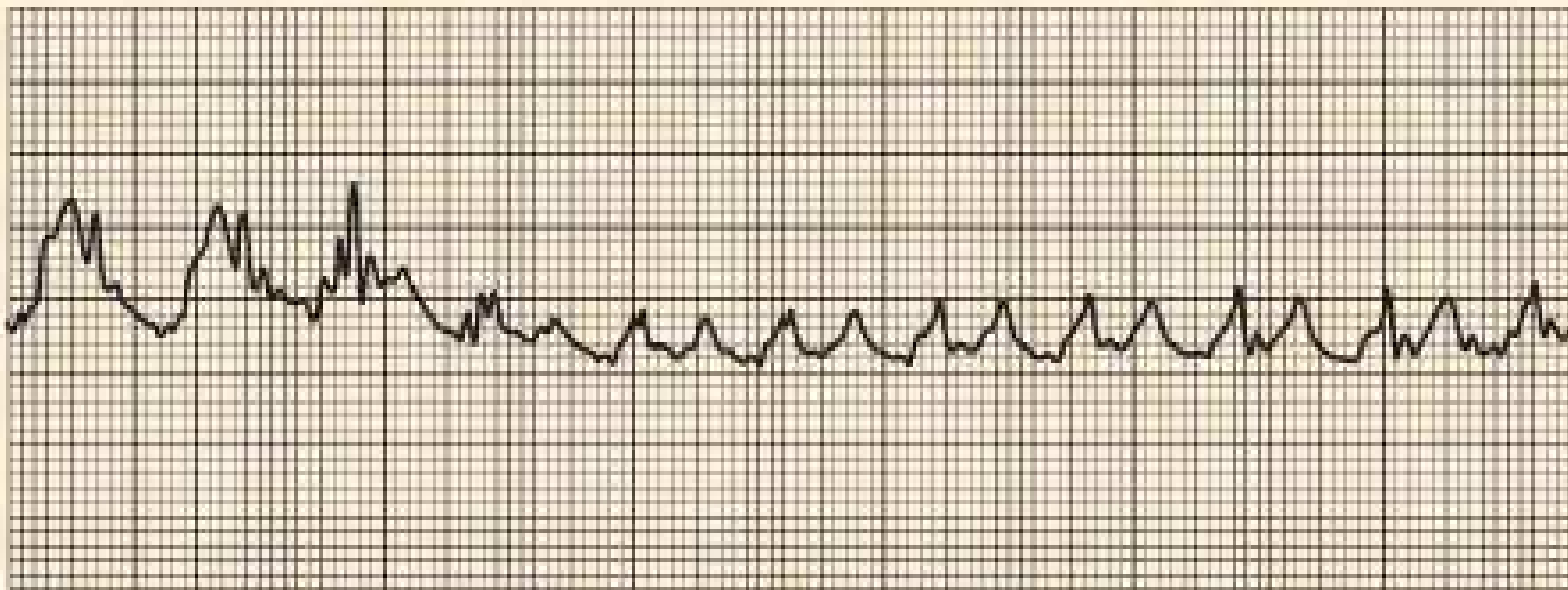


Changes in Waveform as Catheter Is Advanced From the RV to the PA



The PAOP Waveform

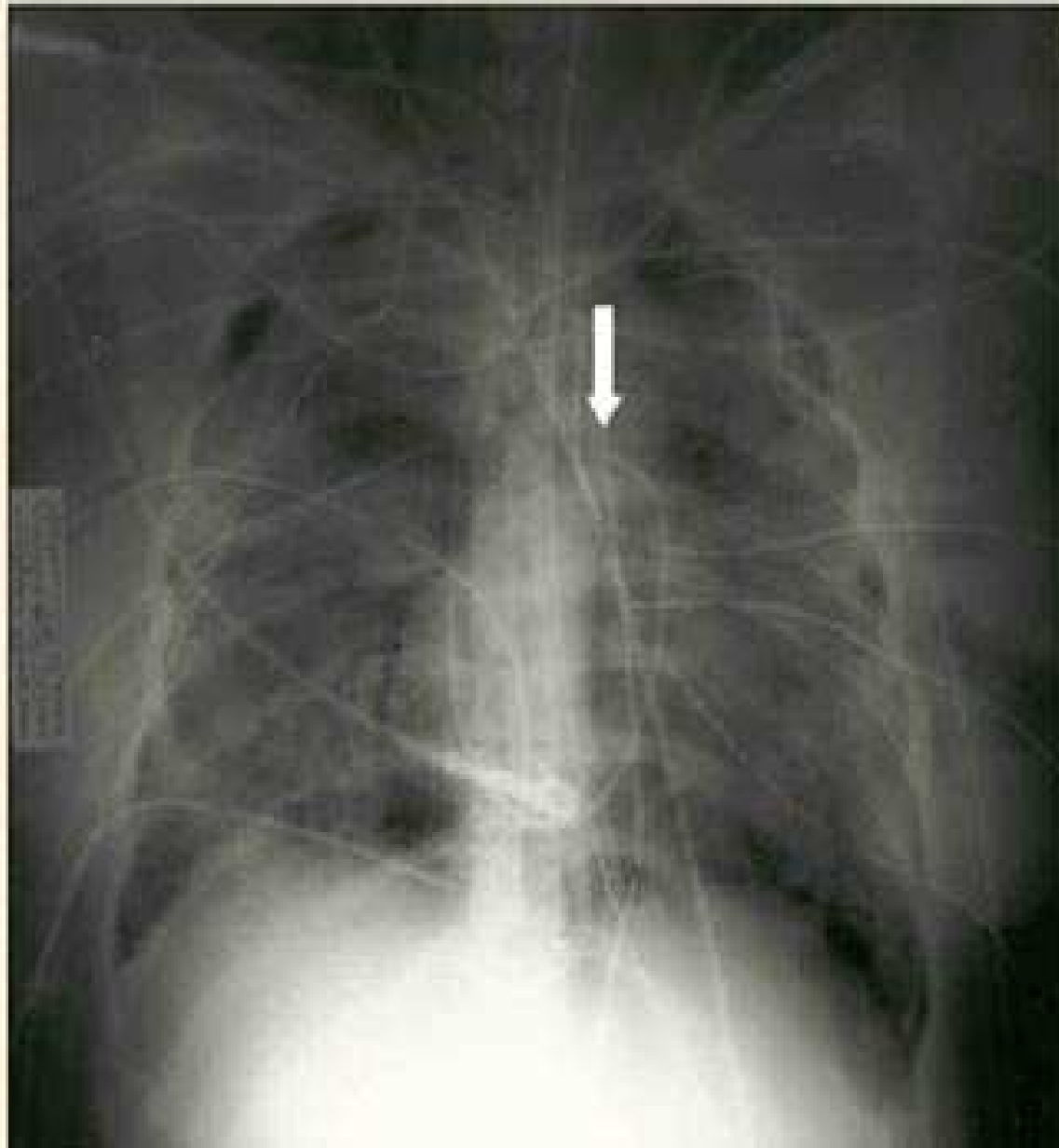
- Inflation of the balloon of the PAC stops measurement of the PA waveform
- The waveform changes to a PAOP waveform with *a* and *v* waves.
- The mean PAOP value is close to the PA diastolic value



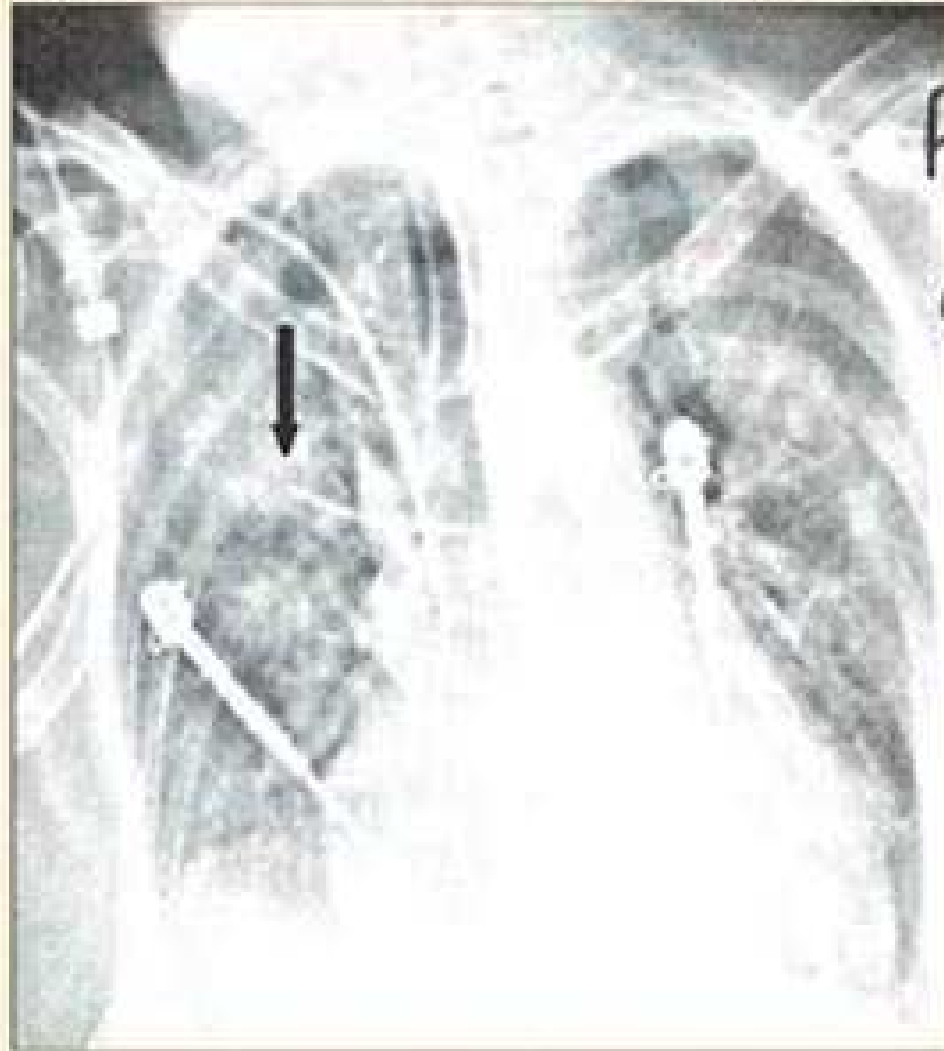Lung Zones

- Zone 1 – Upper lung
 - Essentially no capillary blood flow
- Zone 2 – Central lung
 - Alveolar pressure exceeds capillary pressure, wedging results in no flow
- *Zone 3 – Lower lung
 - PA and venous pressures exceed alveolar pressure; allows wedging

Correct PAC Position



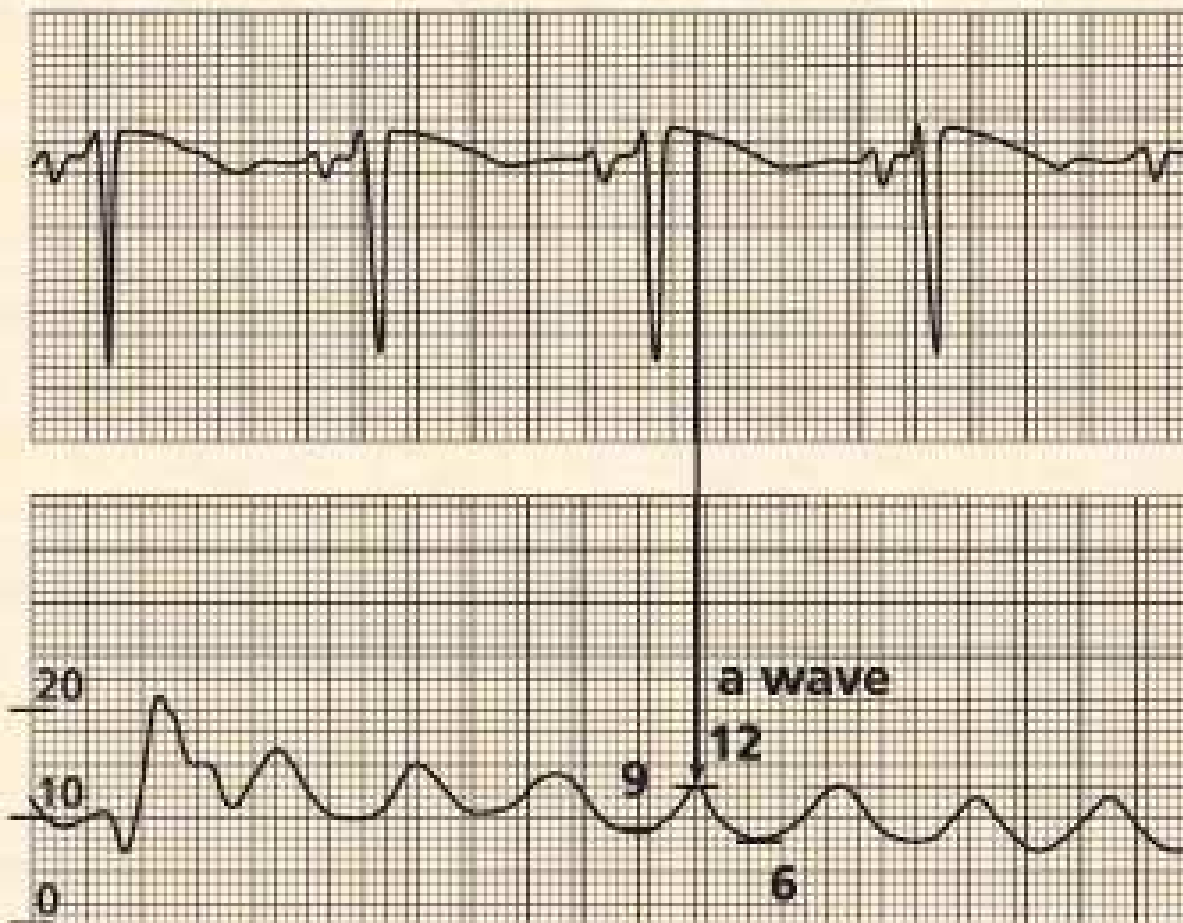
Distal PAC Position



Measuring the PCWP

To measure the mean PAOP value

- Locate the a wave near or after the QRS Complex
- Measure the top and bottom of the a wave values and average these values



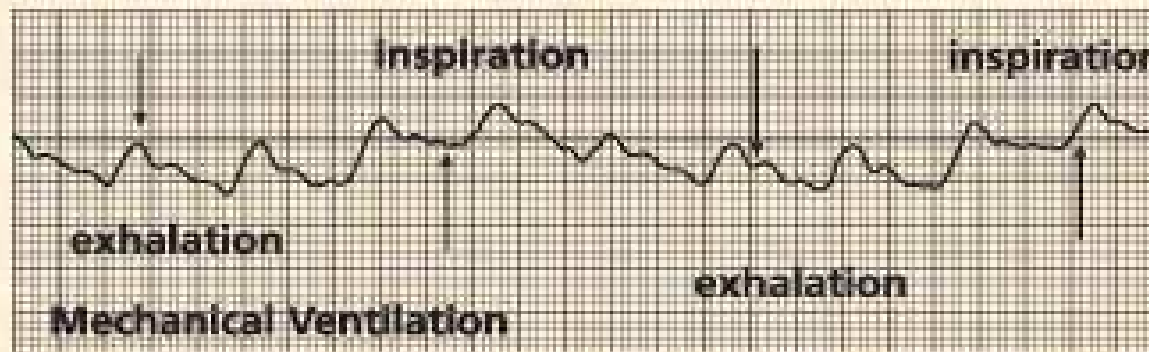
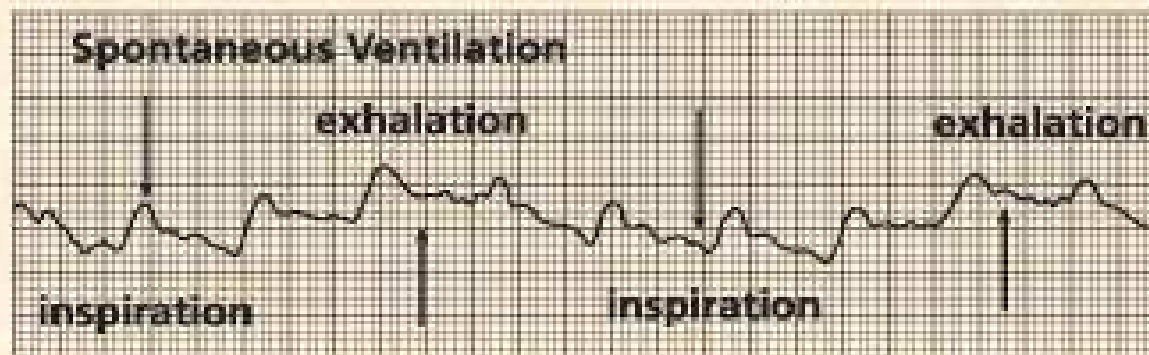
Answer

$$12+6/2=9$$

PCWP and ventilation

Effects of Respiration on Waveforms

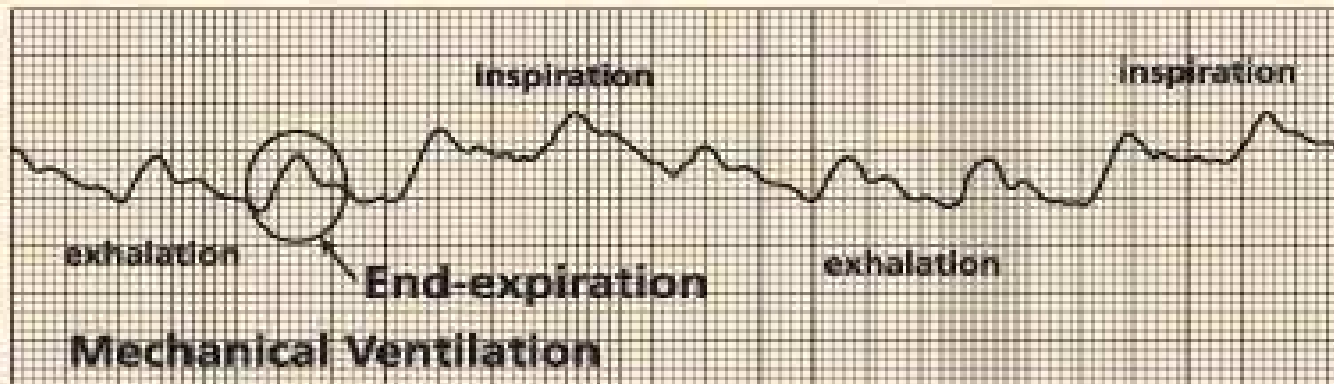
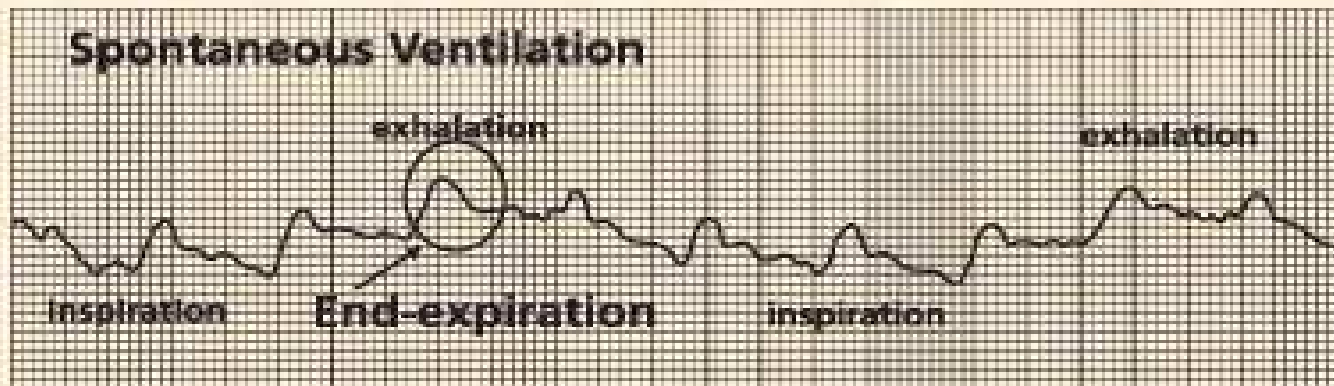
Spontaneous Ventilation



Always measure at end expiration

Spontaneous breathing is UP
Mechanical breathing is DOWN

End-Expiration



Interpretation of the numbers SvO₂ – often overlooked

- Measure of tissue oxygenation
- Less than 60% reflects poor oxygenation
 - Low Cardiac Index
 - Hypovolemia, LV failure
 - Low Hgb
 - Bleeding
 - Low SaO₂
 - Pulmonary Dysfunction
- High SvO₂ (>80%) seen in sepsis, cirrhosis, AV shunt
- Normal SvO₂ with low CI reflects adequate tissue oxygenation

Stroke Volume/Index

- Fall in stroke volume maintain a normal CO/CI if heart rate increases
 - Cardiac Causes
 - CHF
 - MI
 - Tamponade
 - PE
 - Hypovolemia

CVP

Useful for Right Sided Assessment

- Reflection of RV filling pressure
- Low CVP
 - Hypovolemia (Bleeding, third spacing)
- High CVP
 - RV failure
 - Pulmonary hypertension
 - PE
 - Tamponade
 - Constrictive pericarditis

PCWP

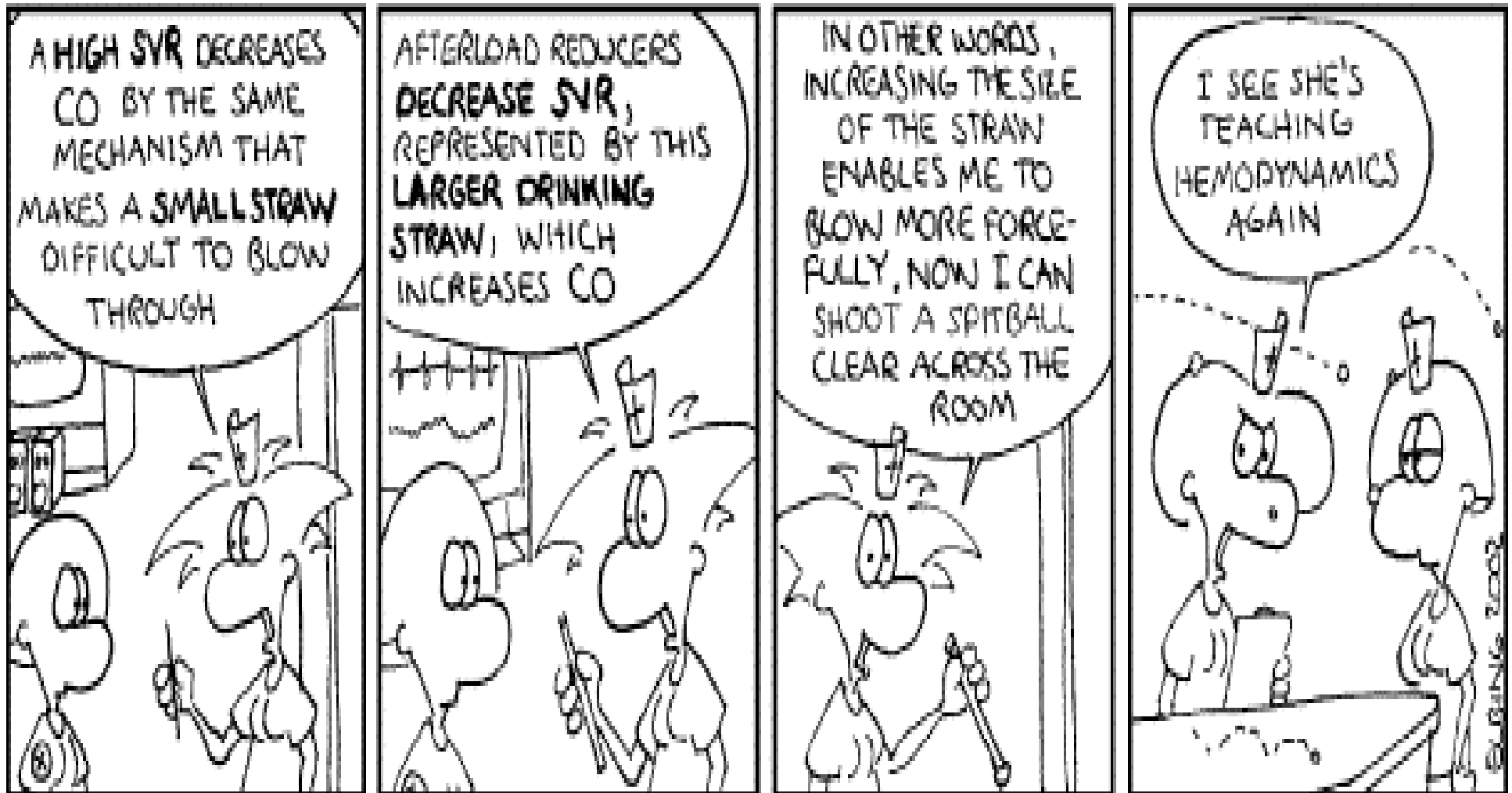
The number everyone wants

- Reflects Left Ventricular filling pressure
- Low PCWP (<10-12)
 - Hypovolemia (Bleeding, third spacing)
 - RV failure
 - PE
- High PCWP (>18)
 - LV failure
 - Hypertension
 - Constrictive pericarditis

SVR

Nurstoons

by Carl Elbing



SVR and PVR

- Useful to assess afterload
- Low SVR (<960 dynes \times sec \times cm^{-5})
 - Sepsis
- High SVR (>1500 dynes \times sec \times cm^{-5})
 - LV failure
 - Hypovolemia
- High PVR (>250 dynes \times sec \times cm^{-5})
 - PE
 - Pulmonary Hypertension

Cardiac Output/Index

- Thermodilution technique
- High CI (>4.2 L/min/m²)
 - Sepsis
- Low CI (<2.4)
 - LV/RV failure
 - Hypovolemic shock
 - PE
 - Tamponade

Tips with the numbers

- In absence of Swan, a CVP and mixed venous O₂ sat (SvO₂) can be very useful
- PAEDP should be the same as PCWP
 - Except when tachycardic or PVR is elevated
- Normal SvO₂ in the face of low CI may warrant just close followup
- Use clinical situation to guide therapies!

Common Clinical Patterns Shock

- Cardiogenic Shock
 - PCWP elevated, CI low, SVR elevated
- Hypovolemic Shock
 - PCWP low, CI low, SVR elevated
- Septic shock (early)
 - CI elevated, SVR low, PVR elevated

Common Clinical Patterns

- RV failure
 - CVP elevated, $CVP \geq PCWP$, CI low
- Tricuspid Regurgitation
 - CVP elevated, RVEDP elevated
- Acute Mitral Regurgitation
 - Elevated PCWP, prominent v waves
- Acute Ventricular Septal Defect
 - Oxygen step-up from RA to RV, RV to PA

Common Clinical Patterns

Pulmonary

- Acute Pulmonary Embolism
 - CO low, PA high, PVR high, PCWP normal
- Chronic Pulmonary Hypertension (precapillary)
 - CVP high, RV Systolic high, PA high, PVR high, PCWP normal

Common Clinical Patterns Uncommon Things

- Cardiac Tamponade
 - CVP = PCWP (“Equalization of Pressures)
 - PCWP/CVP elevated, CI low
- Constrictive/Restrictive Pericarditis
 - CVP elevated, PCWP elevated
 - Diastolic pressures equal

When can the numbers be misleading?

- Tricuspid Stenosis
 - Elevates CVP
- Tricuspid Regurgitation
 - Elevates CVP
 - Lowers CO/CI

When can the numbers be misleading?

- Mitral Regurgitation
 - Elevated LA and PCWP pressures
 - Accentuated v waves similar to PA systolic
 - V wave occurs during T wave, simultaneous EKG may be helpful
- Mitral Stenosis
 - PCWP will be artificially elevated
- Mechanical Ventilation
 - Measure PCWP at end-expiration

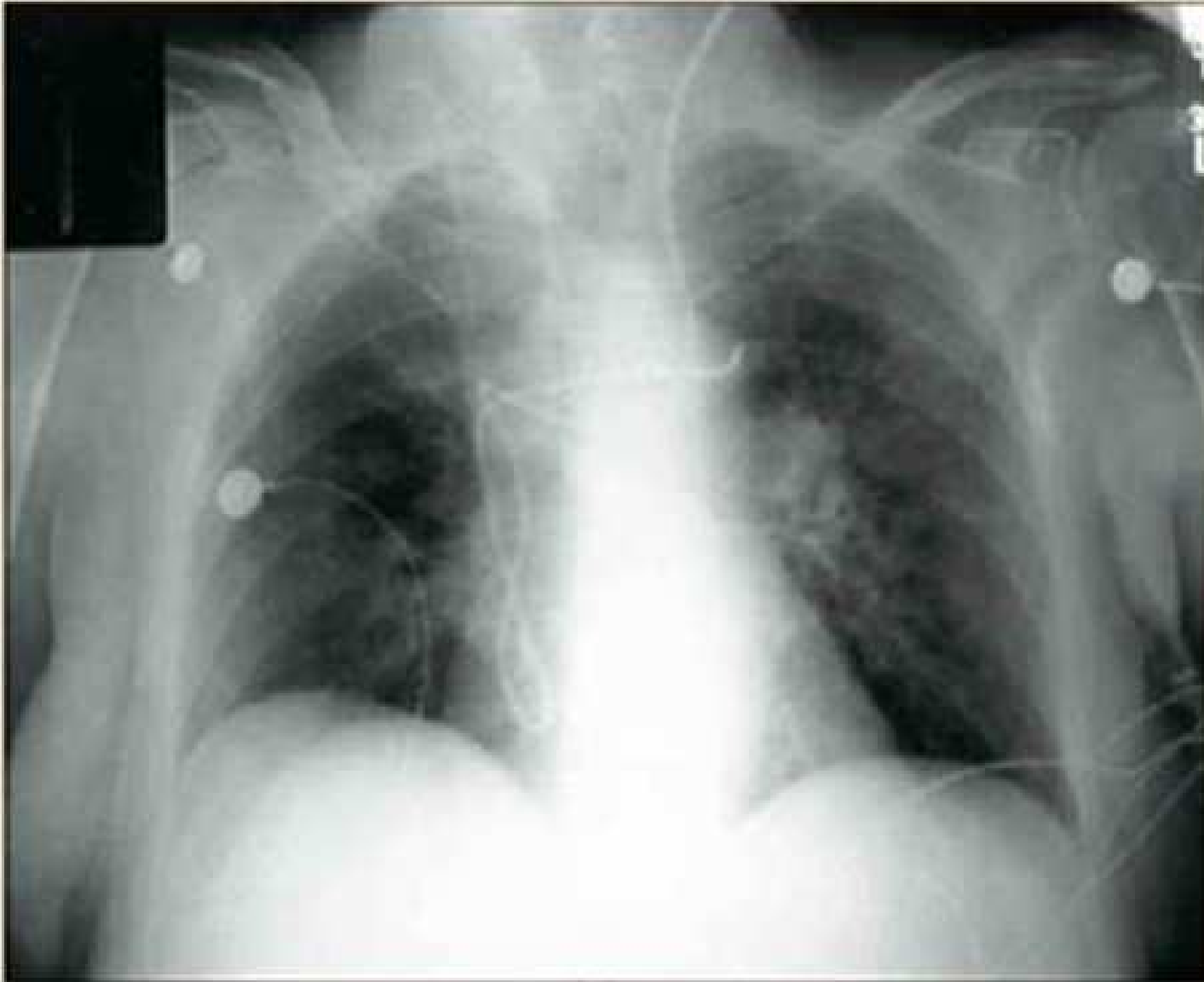
When can the numbers be misleading?

- “Overwedging” – occurs when tip is distal to optimal position, high PCWP
 - Can occur with tip migration
 - Resistance noted with inflation of balloon
 - Pull back catheter in 1/2-1 cm increments

Difficulties

- Catheter wedges in RV papillary muscles
 - No difference in ‘wedged’ and unwedged tracings
- Catheter ‘fails to wedge’
 - Mitral regurgitation?
 - Loop in RV?
 - Try refloating Swan

Difficulty – Coiled Catheter



Complications of Insertion

- Arterial Puncture
 - Use anatomic landmarks, proper technique
- Pneumothorax/Hemothorax
 - Dx by chest xray, treat with chest tube
- Air Embolism
 - Acute respiratory distress, cyanosis
 - Mill Wheel murmur
 - Left lateral decubitus, 100% FiO₂

Ventricular Arrhythmia

- Most are transient during insertion
- Keep balloon inflated, keep advancing!
- If sustained, deflate balloon and remove catheter
- Defibrillate if VF/Pulseless VT

Heart Block

- Do not place PA catheter in a patient with Left Bundle Branch Block unless you have backup pacing!
- Insertion can cause transient RBBB which would become complete heart block

Catheter loops and knots

- Avoid advancing catheter against resistance or if waveforms are not as expected
 - At 30 cm should see RV
- Do not allow loops to remain in RV
- If knot develops, use fluoroscopy for guidance

Complications during use

- Pulmonary Artery Rupture
- Pulmonary Infarction
 - High pressure wedging
 - Keep inflation duration <15 seconds
- Infection
- Ventricular Arrhythmias
- **Remove PA catheter when information is no longer useful!**

References

- <http://www.pacep.org>
- Amin DK, Shah PK, Swan HJC. The Swan-Ganz Catheter. J Crit Illness 1(4):24-45 and 1(5):40-61, 1986)