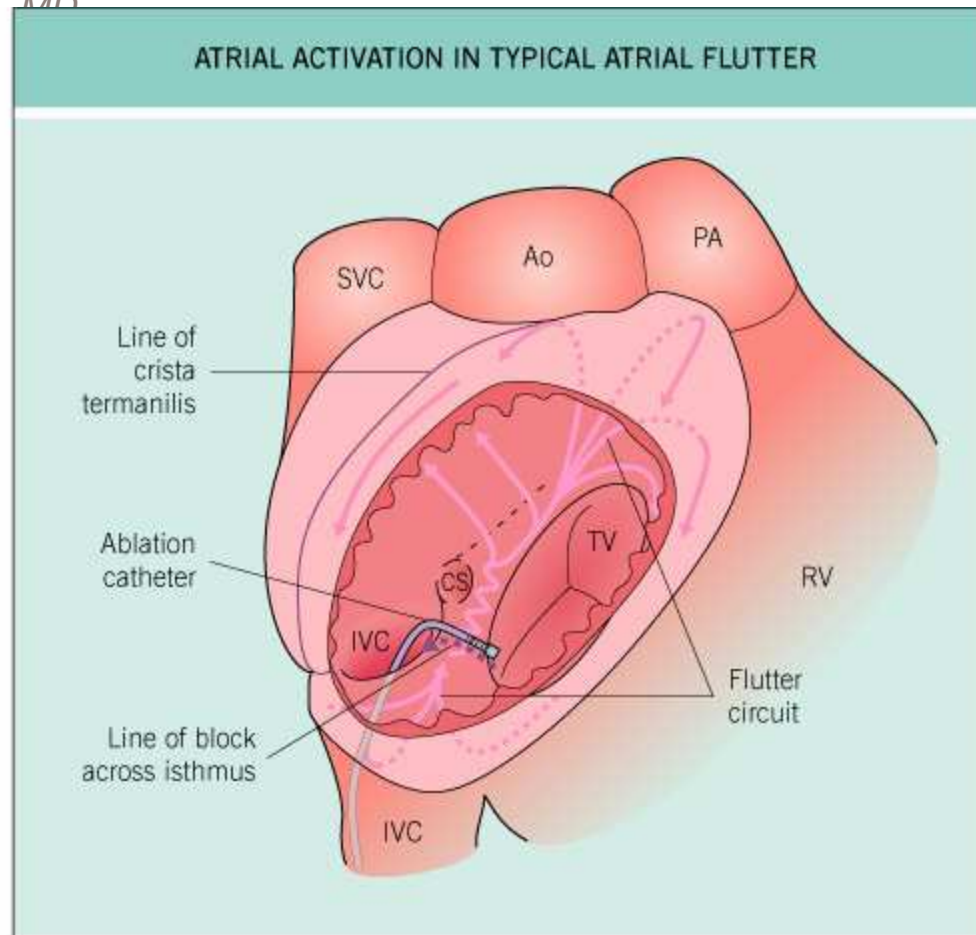


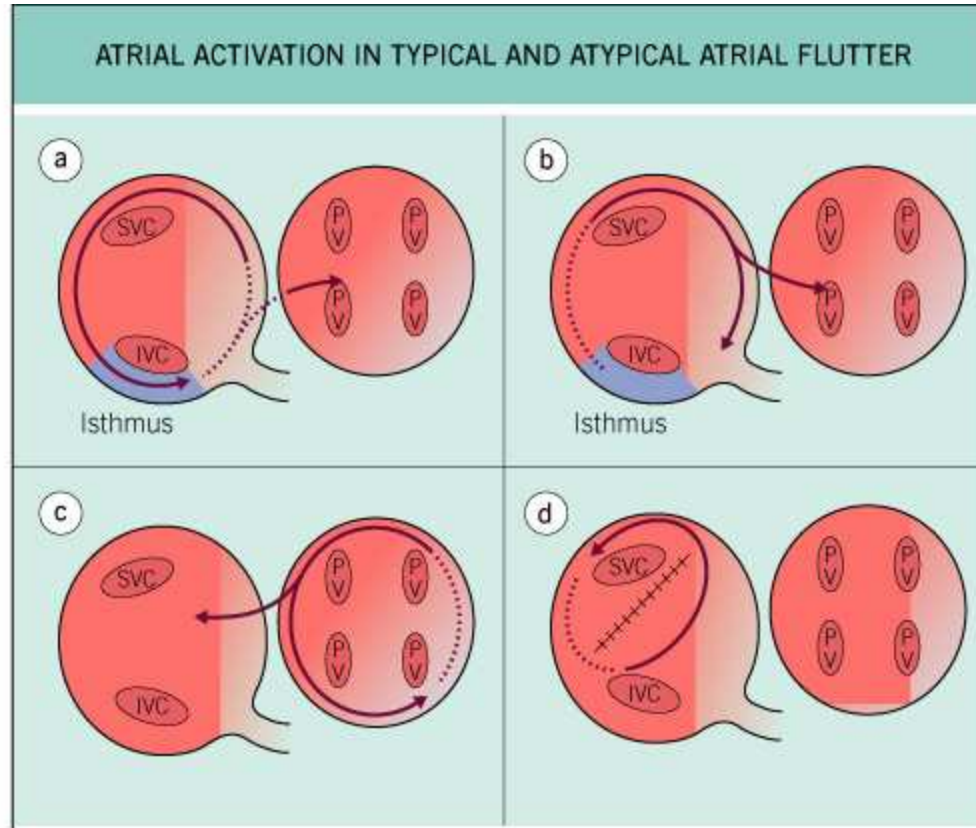
# Atrial Flutter Ablation

May 26, 2005



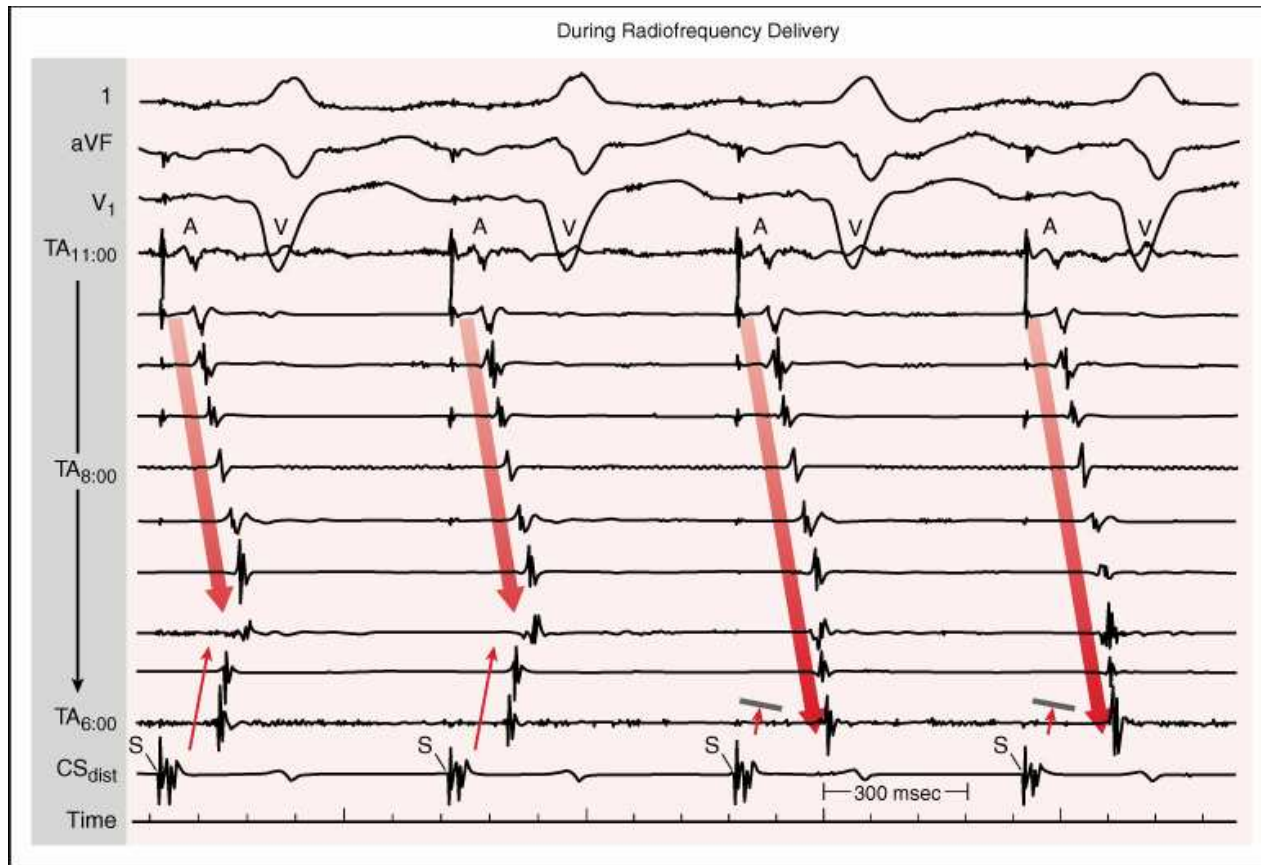
© 2004 Elsevier Ltd - Cardiology 2E, edited by Crawford, DiMarco and Paulus. All rights reserved.

The right atrium is shown with its anterior wall opened. Activation ascends the interatrial septum, and descends the free wall. It is 'funneled' by the tricuspid annulus and the crista terminalis into the subeustachian isthmus. Conduction in this area is slowed (wavy line). Catheter ablation aims to create a line of block across the isthmus, usually between the tricuspid annulus and the inferior vena cava. Ao, aortic root; CS, ostium of coronary sinus; IVC, inferior vena cava; PA, main pulmonary artery; RV, right ventricle; SVC, superior vena cava; TV, tricuspid valve.

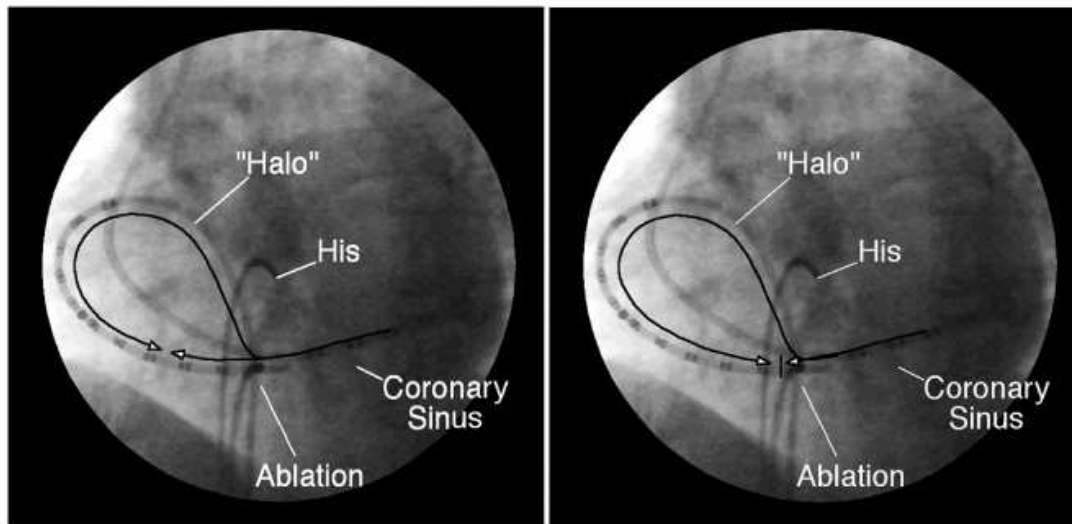


© 2004 Elsevier Ltd - Cardiology 2E, edited by Crawford, DiMarco and Paulus. All rights reserved.

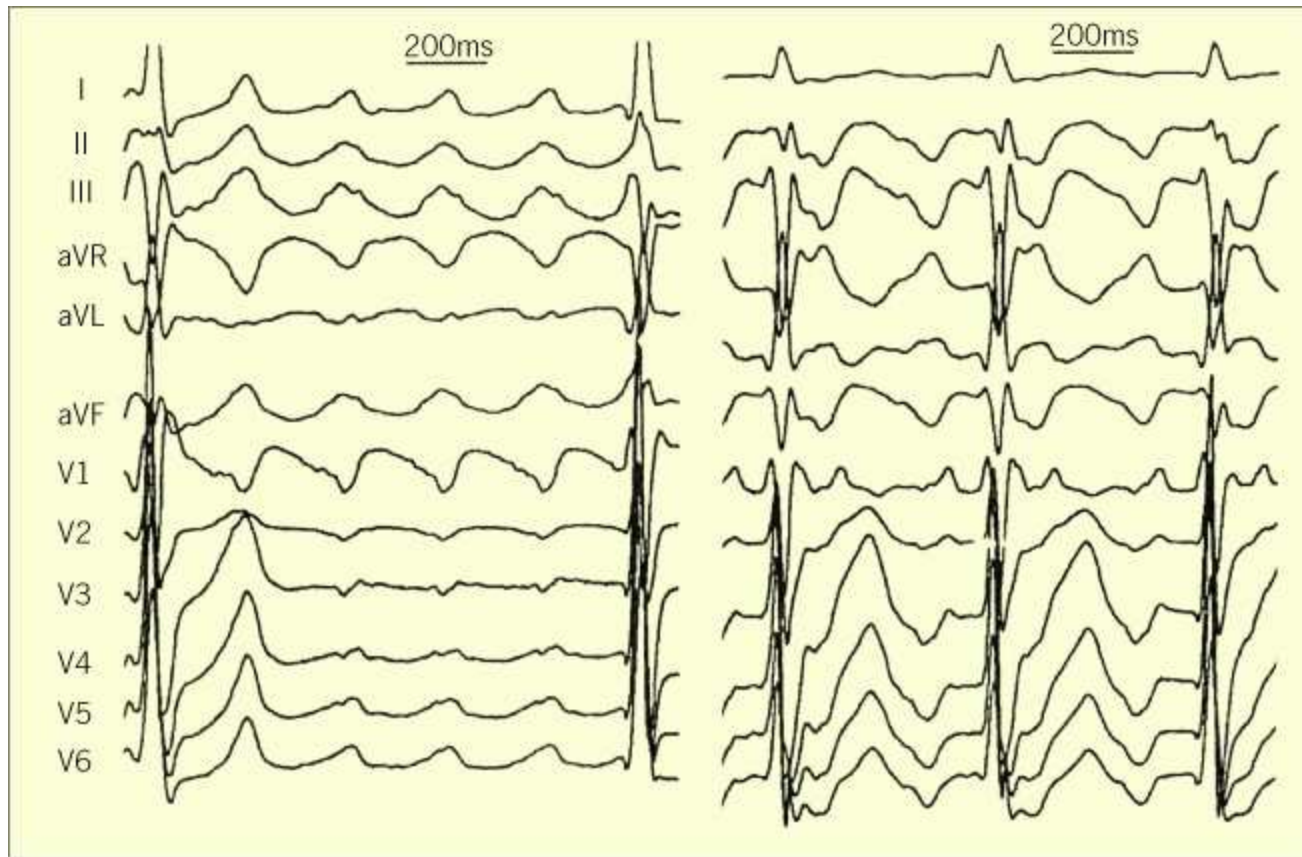
**Atrial activation in typical and atypical atrial flutter.** (a) *Typical (counterclockwise) atrial flutter.* (b) *'Clockwise' flutter.* In this form of atypical flutter, atrial activation is the exact opposite of typical atrial flutter, and the circuit is dependent on conduction through the subeustachian isthmus. (c) *Truly atypical atrial flutter.* A number of alternative macro-re-entrant circuits are possible, especially in diseased atria, probably including circuits that rotate around the pulmonary veins. (d) *Scar-related flutter* is commonly seen after surgery for congenital heart disease.



**A**, Two forms of atrial flutter in the same patient are shown. A “halo” catheter with 10 electrode pairs is situated on the atrial side of the tricuspid annulus (TA), with recording sites displayed from the top of the annulus (“12:00”) to the inferomedial aspect (“5:00”), as shown in fluoroscopic views in **B**. On the left, the wave front of atrial activation proceeds in a “clockwise” fashion (arrows) along the annulus, whereas at the right the direction of propagation is the reverse. **B**, Ablation of the isthmus of atrial tissue between the tricuspid annulus and inferior vena caval orifice for cure of atrial flutter. Recordings are displayed from the multipolar catheter around much of the circumference of the tricuspid annulus (see left anterior oblique fluoroscopy images). Ablation of this isthmus is performed during coronary sinus pacing. In the two beats on the left, atrial conduction proceeds in two directions around the tricuspid annulus, as indicated by arrows and recorded along the halo catheter. In the two beats on the right, ablation has interrupted conduction in the floor of the right atrium, eliminating one path for transmission along the tricuspid annulus. The halo catheter now records conduction proceeding all the way around the annulus. This finding demonstrates unidirectional block in the isthmus; block in the other direction may be demonstrated by pacing from one of the halo electrodes and observing a similar lack of isthmus conduction. (The bundle of His recording in the right panel is lost owing to catheter movement.)

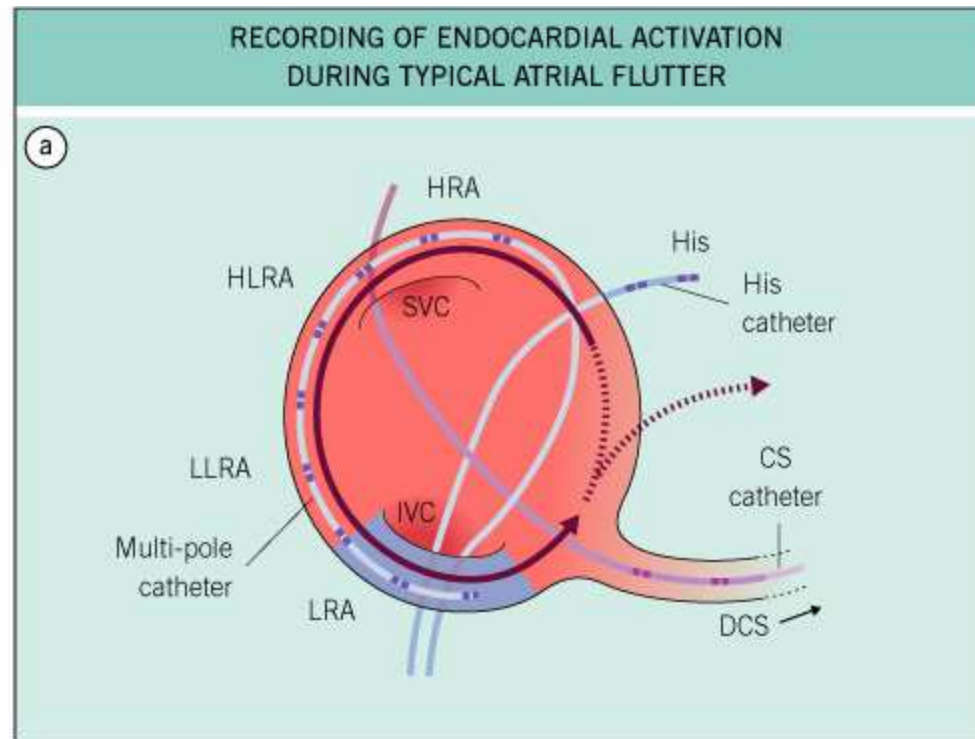






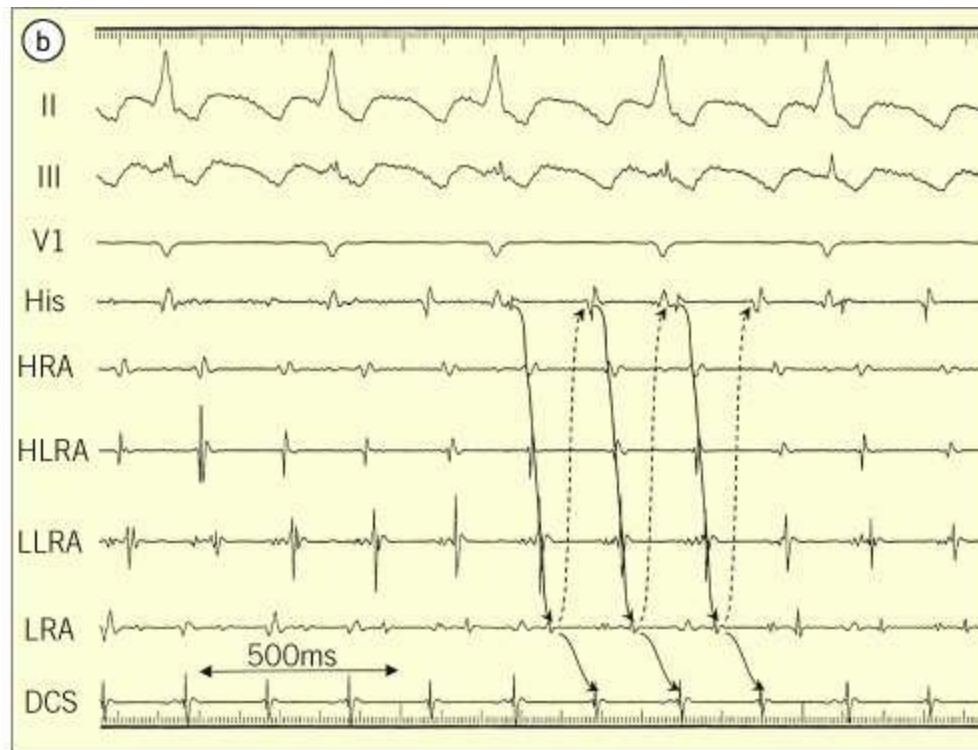
© 2004 Elsevier Ltd - Cardiology 2E, edited by Crawford, DiMarco and Paulus. All rights reserved.

The typical appearance of clockwise flutter (left) is contrasted with typical flutter (right). In clockwise flutter, the morphology is predominantly upright and may show notching in the inferior limb leads. In V1, the morphology is inverted, but it becomes positive by V6. In typical flutter, the morphology is predominantly negative in the inferior leads and positive in V1.



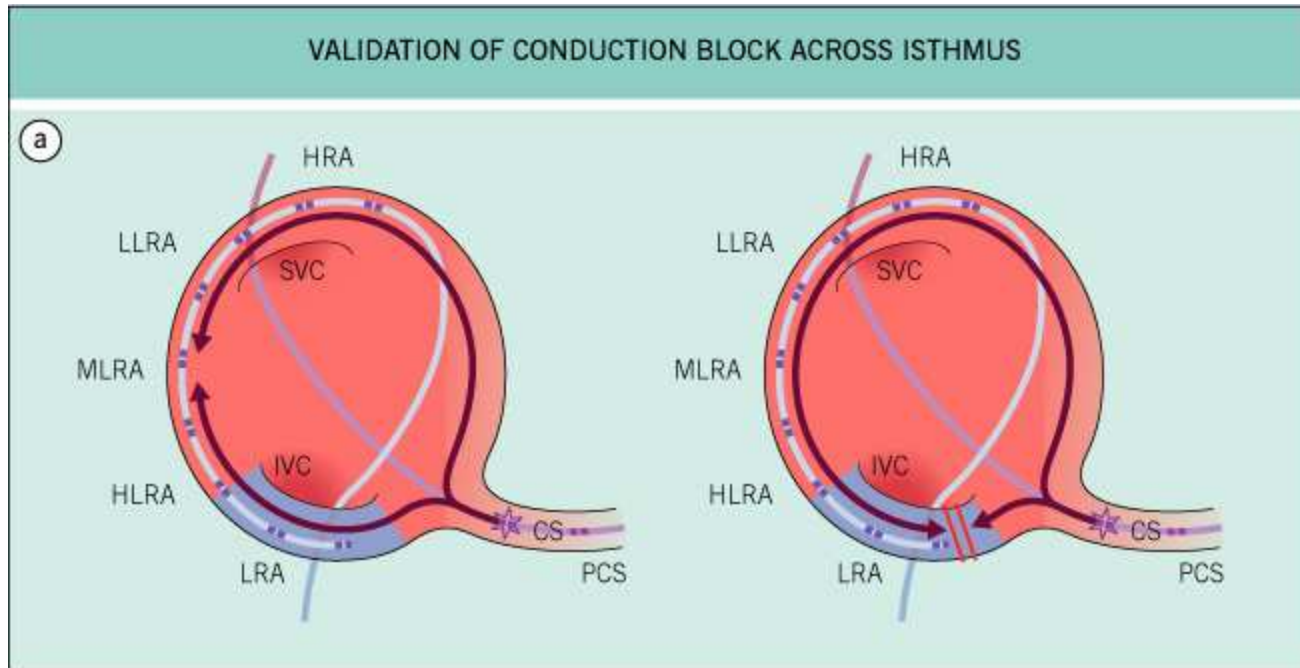
© 2004 Elsevier Ltd - Cardiology 2E, edited by Crawford, DiMarco and Paulus. All rights reserved.

**Recording of endocardial activation during typical atrial flutter.** (a) Electrode catheters used for mapping atrial flutter. Viewed from below, atrial activation courses round the tricuspid annulus in a counterclockwise direction, and the left atrium is activated passively (arrows). This pattern of activation is recorded by a multipolar catheter placed along the lateral wall of the right atrium, a catheter at the location of the bundle of His, and a catheter in the coronary sinus.



© 2004 Elsevier Ltd - Cardiology 2E, edited by Crawford, DiMarco and Paulus. All rights reserved.

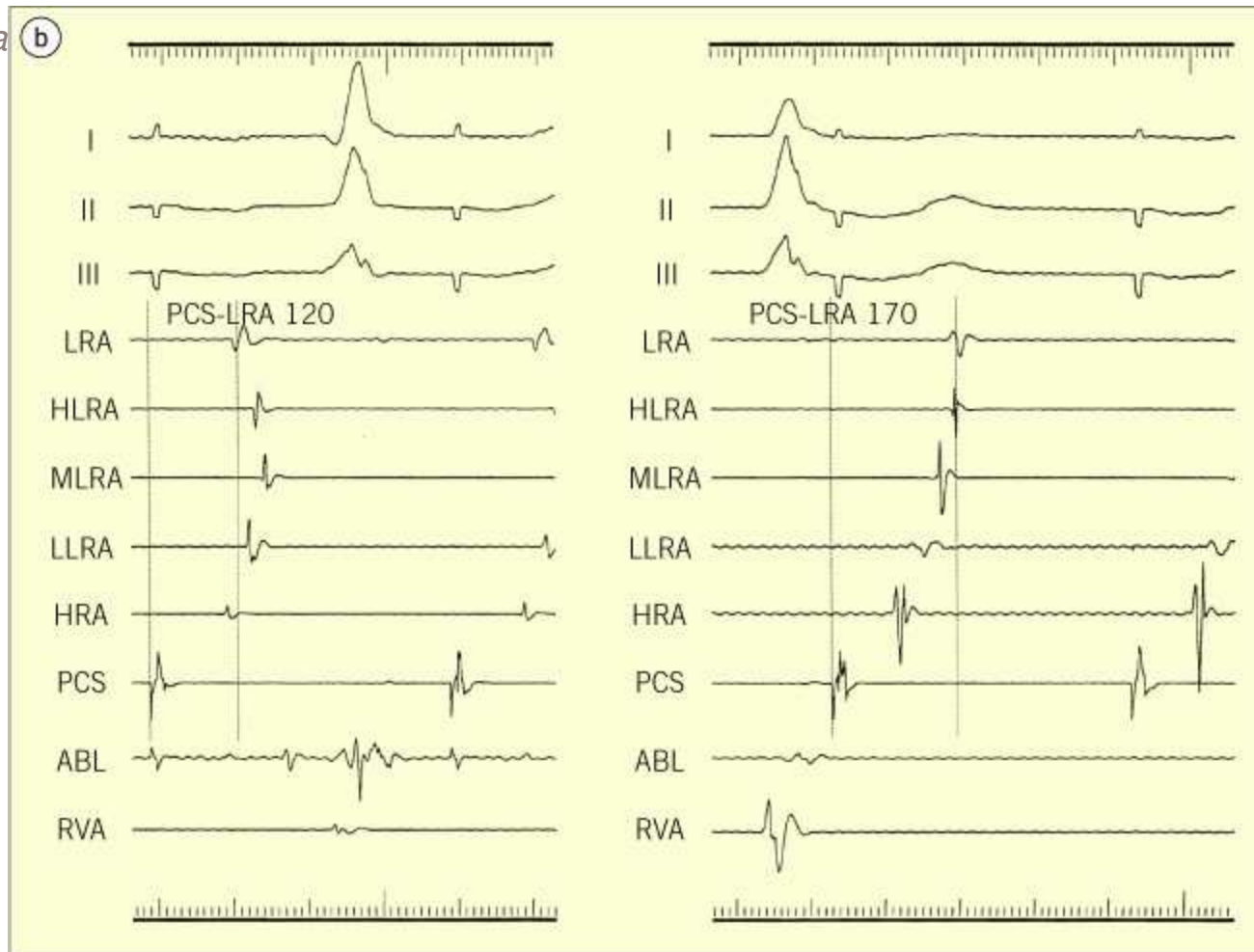
**Recording of endocardial activation during typical atrial flutter.**(b) Electrograms recorded from these catheters. His, bundle of His electrogram; HRA, high right atrium; HLRA, high lateral right atrium; LLRA, low lateral right atrium; LRA, low right atrium; DCS, distal coronary sinus.



© 2004 Elsevier Ltd - Cardiology 2E, edited by Crawford, DiMarco and Paulus. All rights reserved.

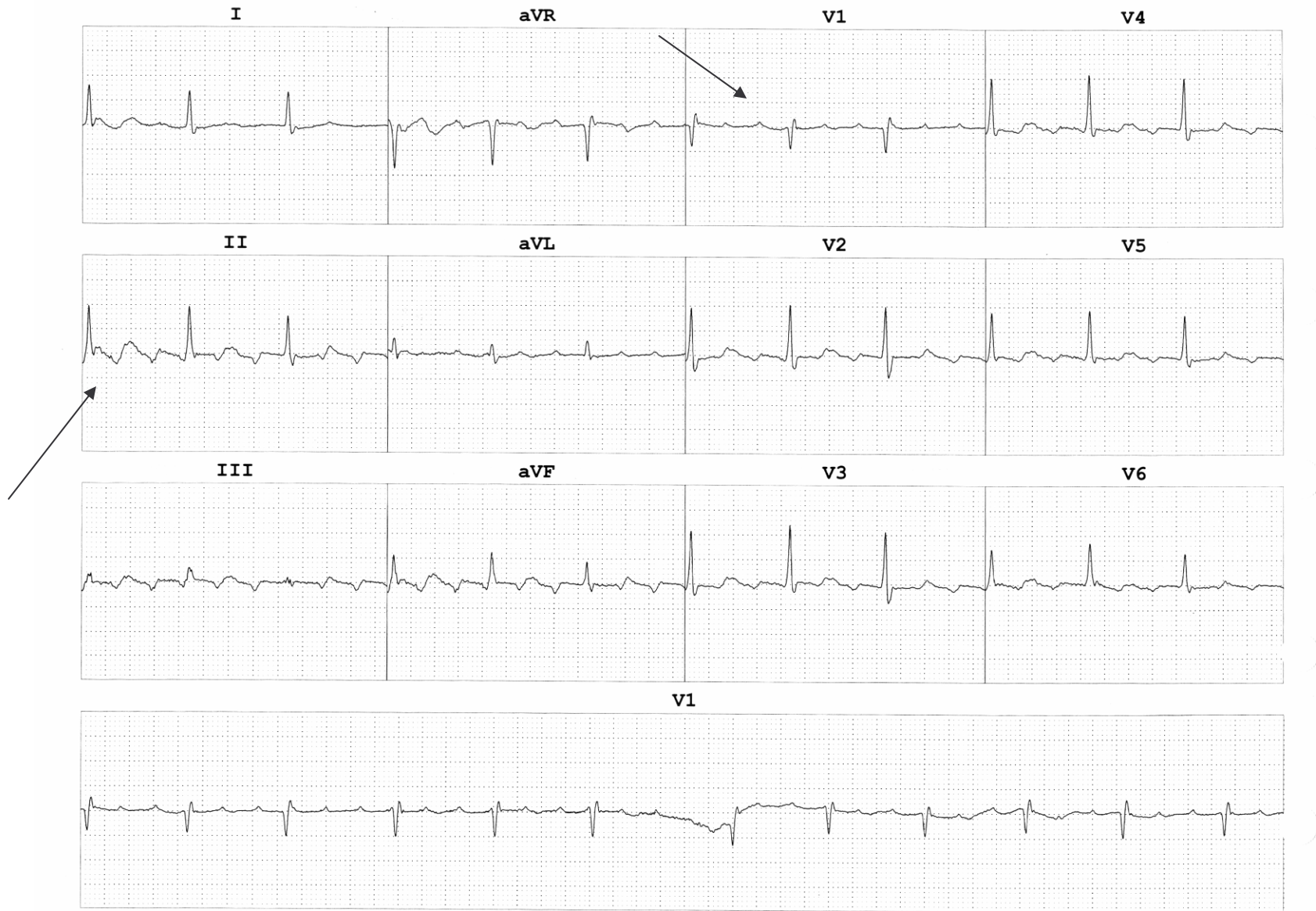Atrial activation during coronary sinus pacing before and after catheter ablation to create a line of conduction block across the subeustachian isthmus. (a) Diagrammatic representation of atrial activation.



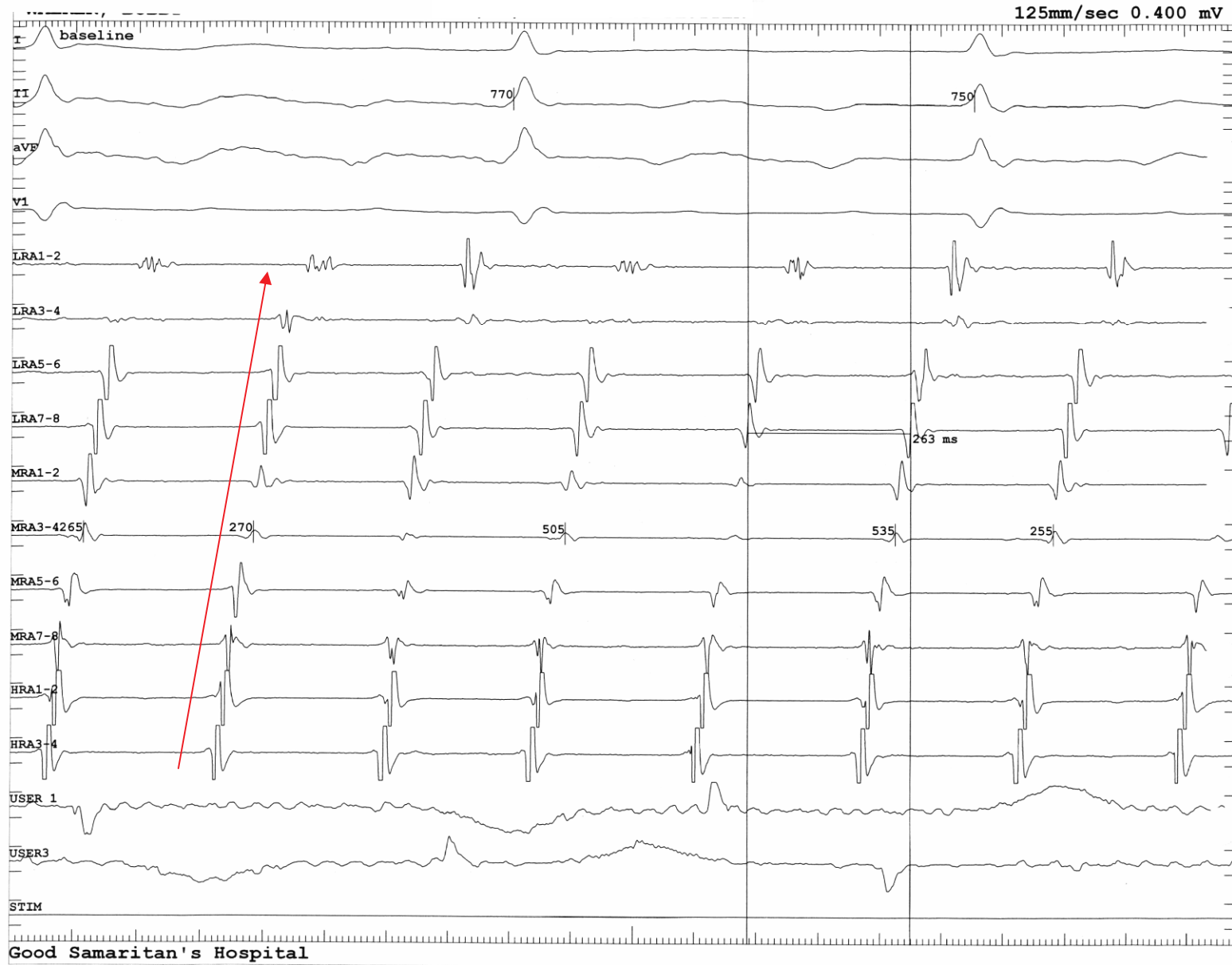


© 2004 Elsevier Ltd - Cardiology 2E, edited by Crawford, DiMarco and Paulus. All rights reserved.

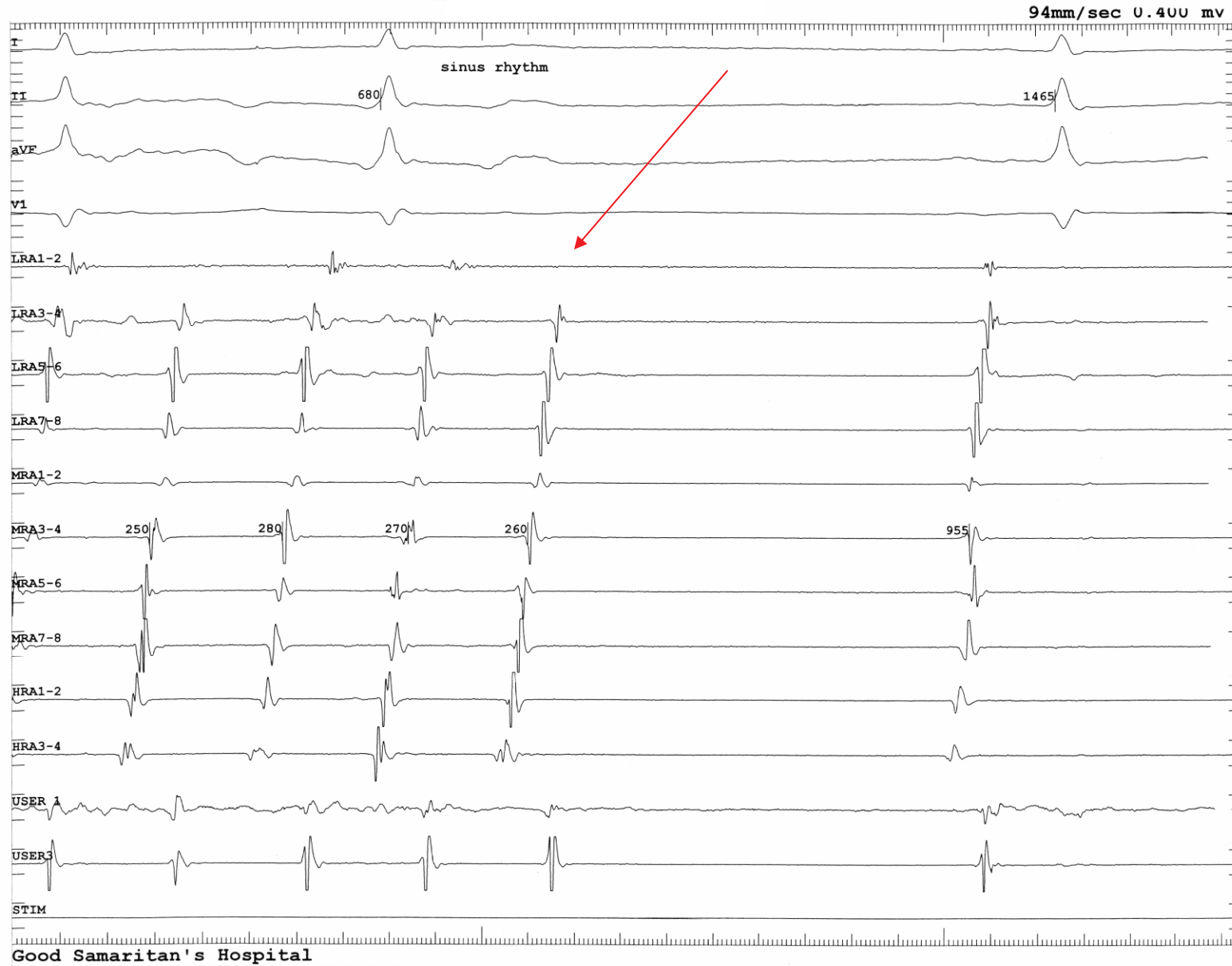
**Validation of conduction block across isthmus.** Atrial activation during coronary sinus pacing before and after catheter ablation to create a line of conduction block across the subeustachian isthmus. (b) Intracardiac electrograms. Before ablation (left, a and b), the right atrium is activated from the coronary sinus in both the clockwise and counterclockwise directions, and the mid-lateral right atrium is activated last. After ablation (right, a and b), clockwise activation through the isthmus is blocked, and the lateral right atrium is activated entirely in the counterclockwise direction, from above to below. Counterclockwise block in the isthmus can similarly be demonstrated by pacing the low right atrium and observing the timing of activation in the proximal coronary sinus. HRA, high right atrium; HLRA, high lateral right atrium; MLRA, mid lateral right atrium; LLRA, low lateral right atrium; LRA, low right atrium; PCS, proximal coronary sinus.



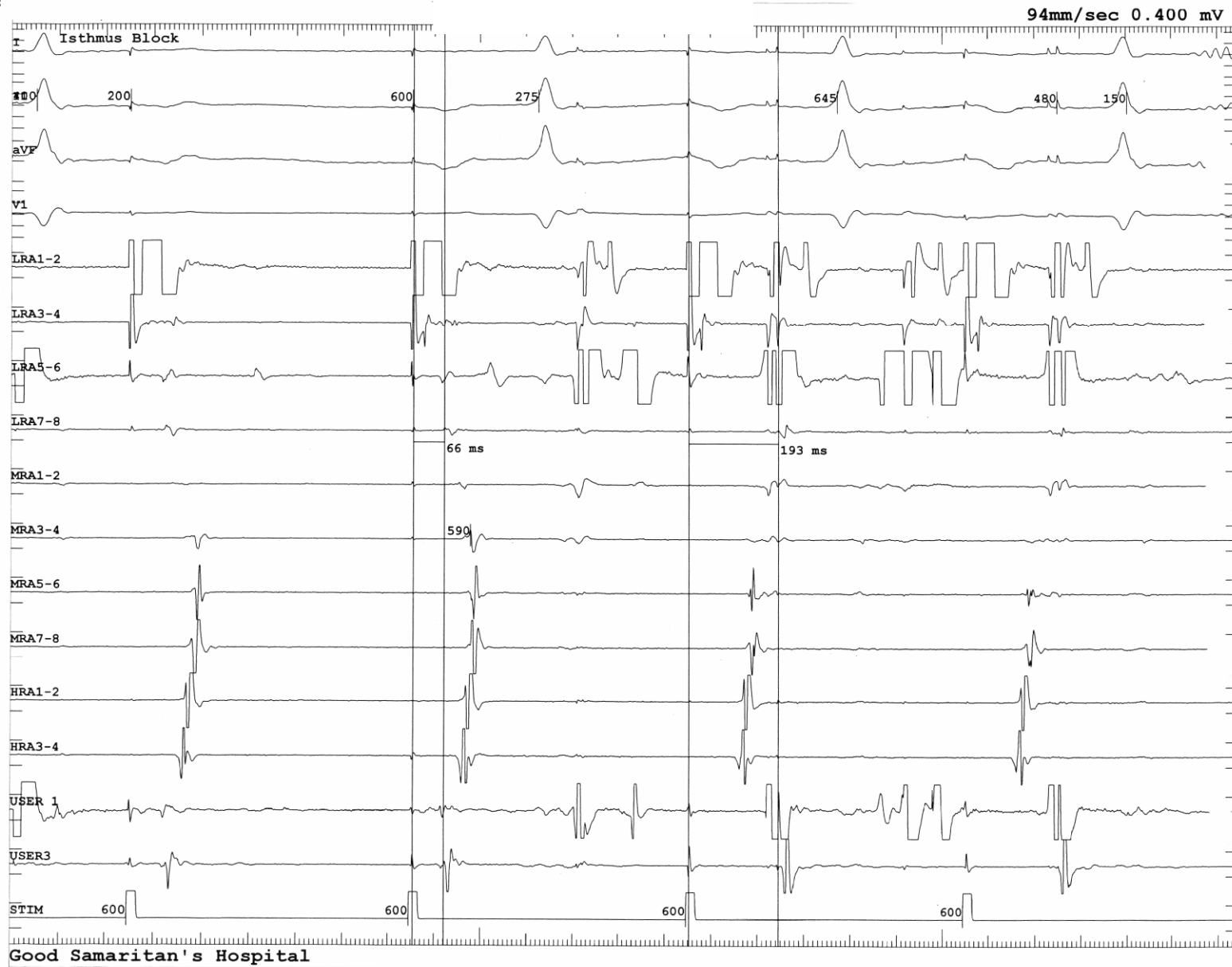
Typical Atrial Flutter – F waves negative in II and positive in V1



Intracardiac Electrogram of Typical Atrial Flutter (Counterclockwise)

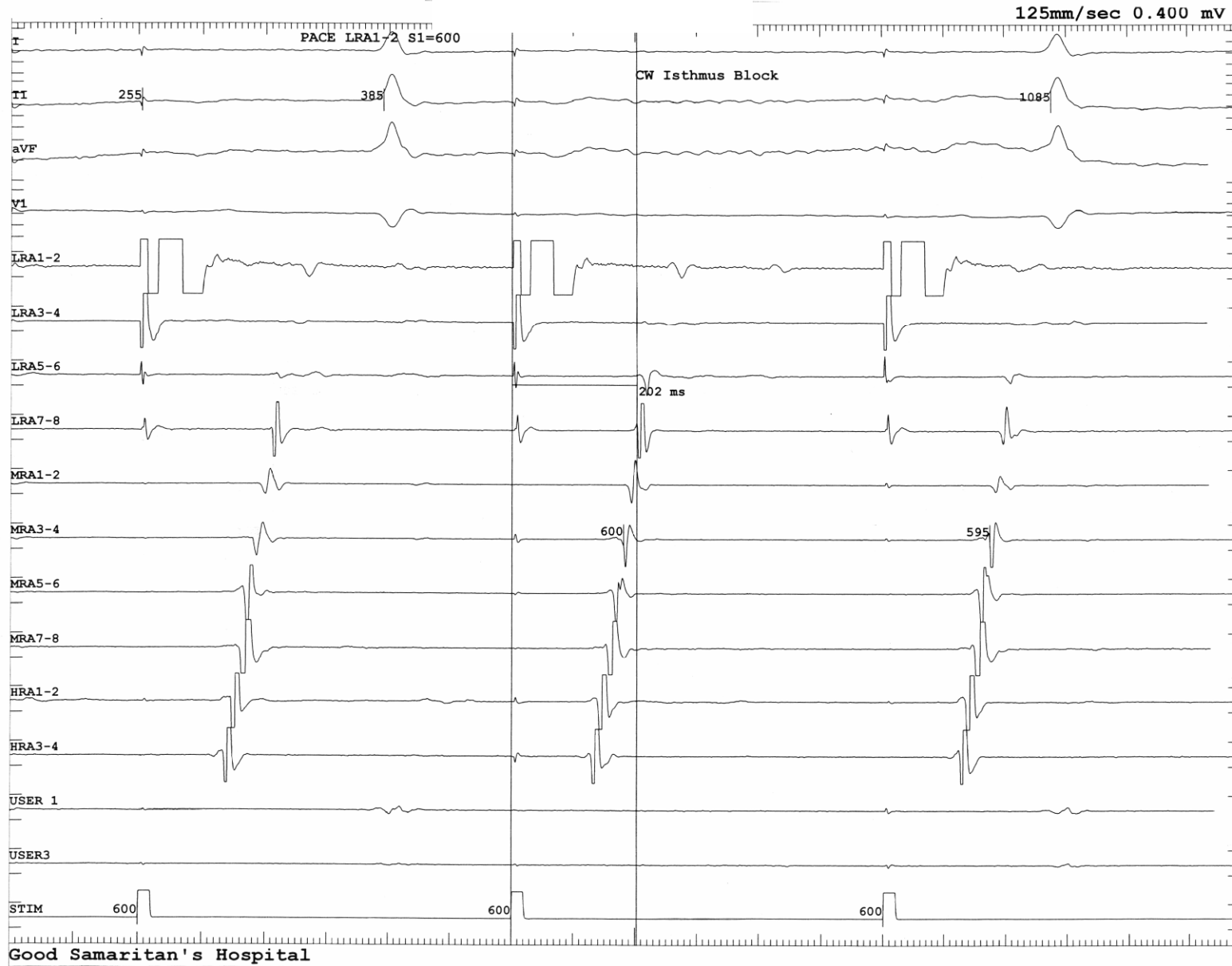

Flutter Breaks with RF across tricuspid annulus isthmus  
Line of block is around LRA 3-4

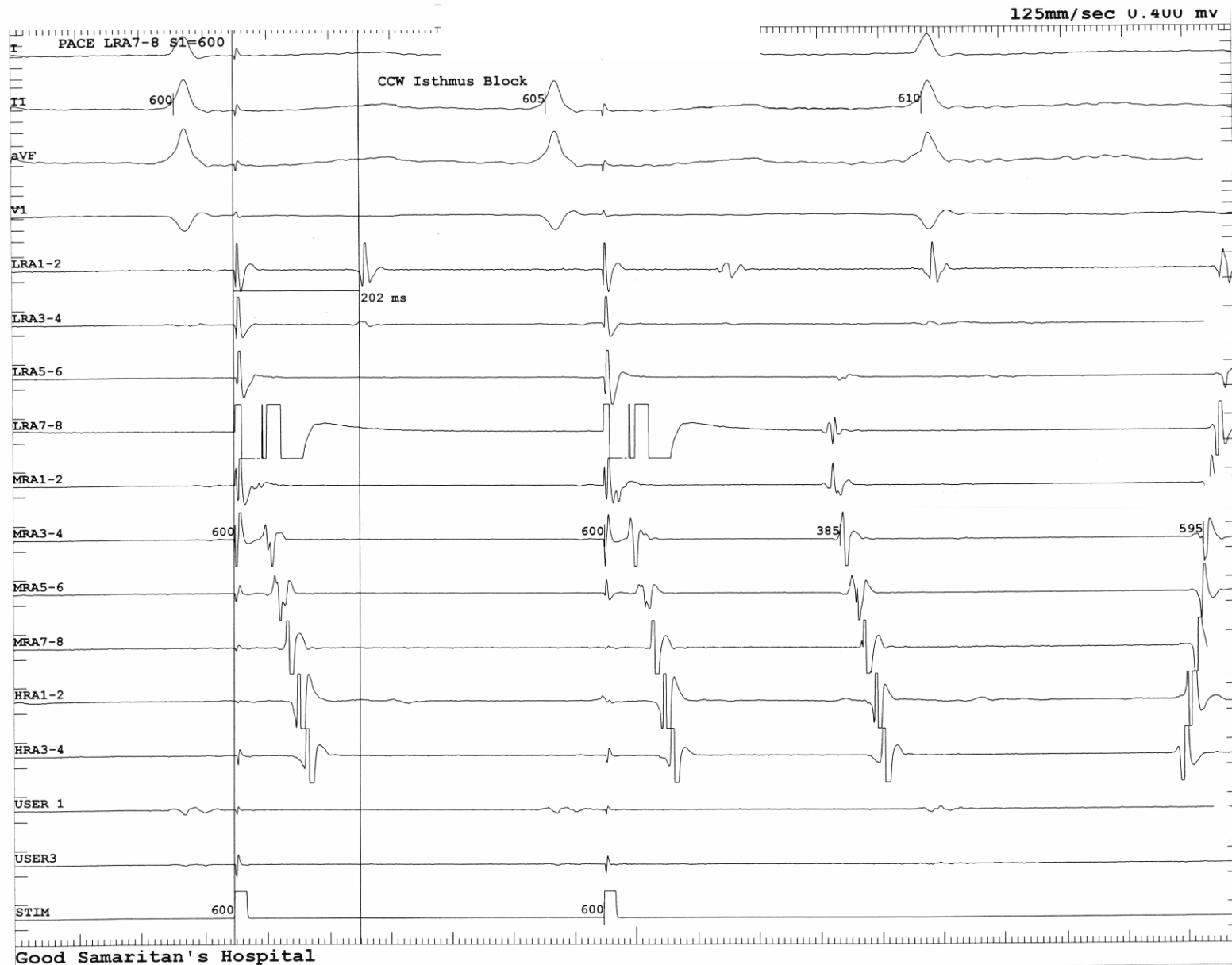


Pacing at LRA 3-4 to demonstrate variable conduction time to LRA 5-6  
(Clockwise conduction is still present, incomplete lesion)

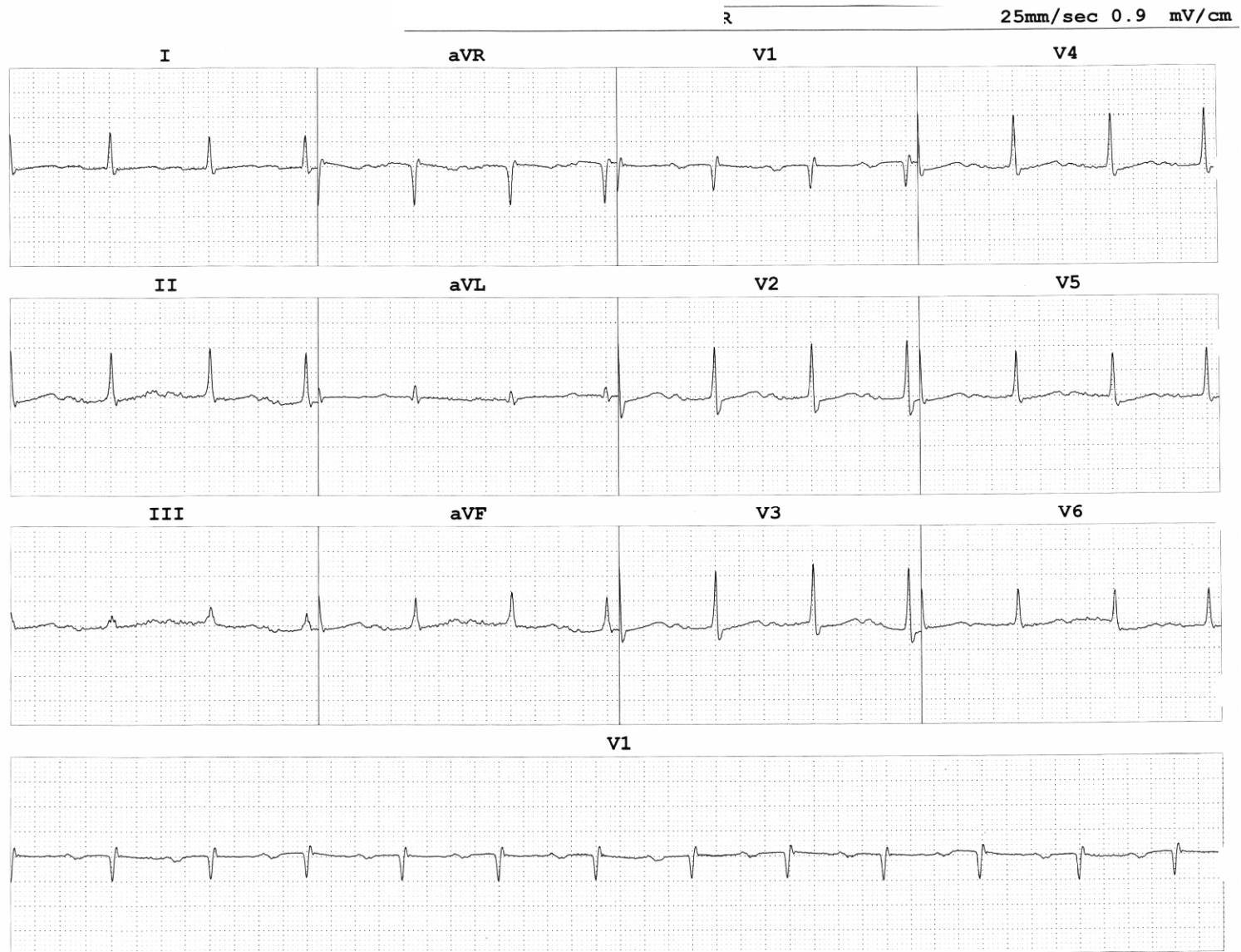



Pacing at LRA 1-2 demonstrates only counterclockwise conduction  
Clockwise block around LRA 3-4 (isthmus) lesion

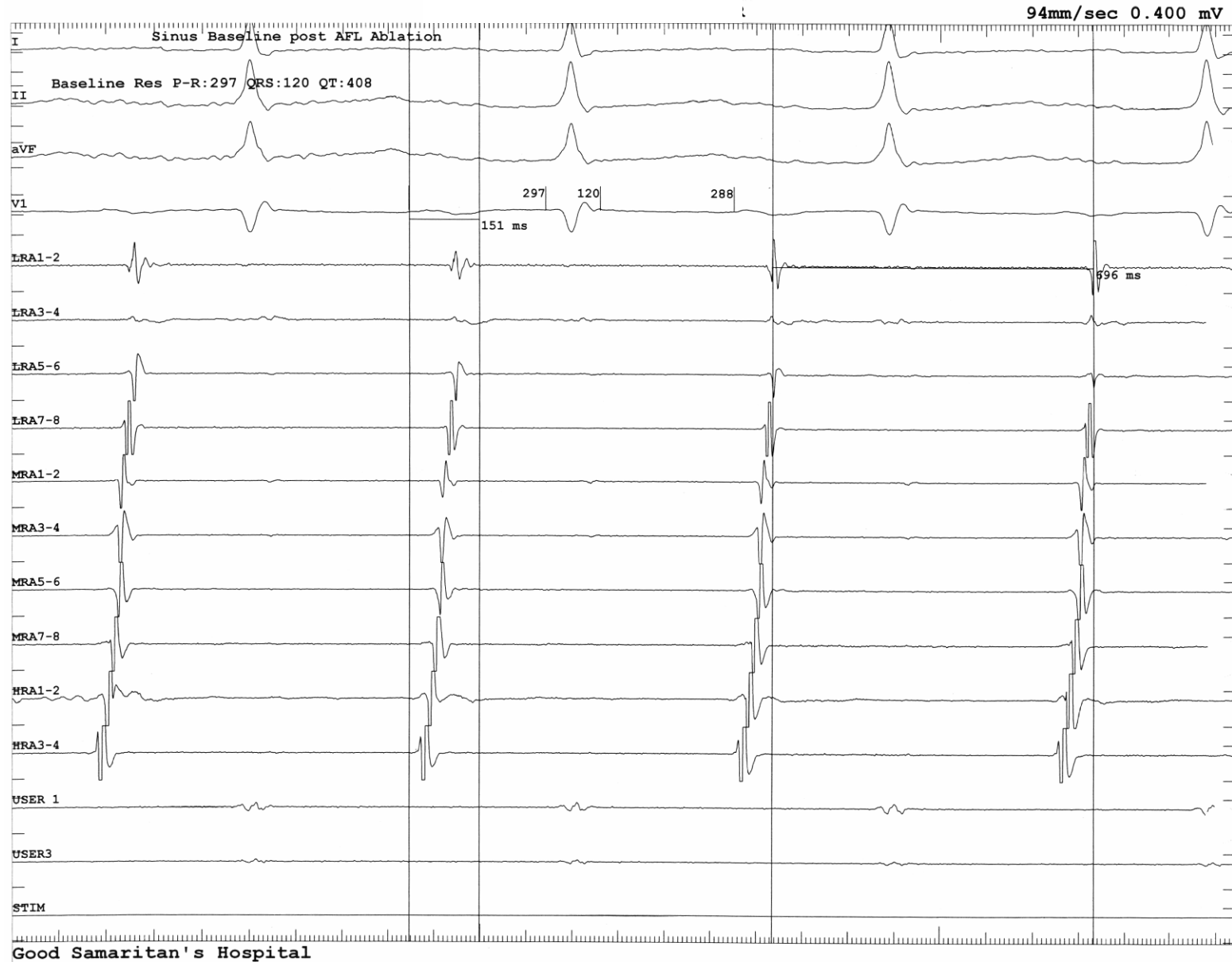


Pacing at LRA 7-8 demonstrates clockwise conduction  
Counterclockwise conduction across LRA 3-4 lesion (isthmus) is blocked

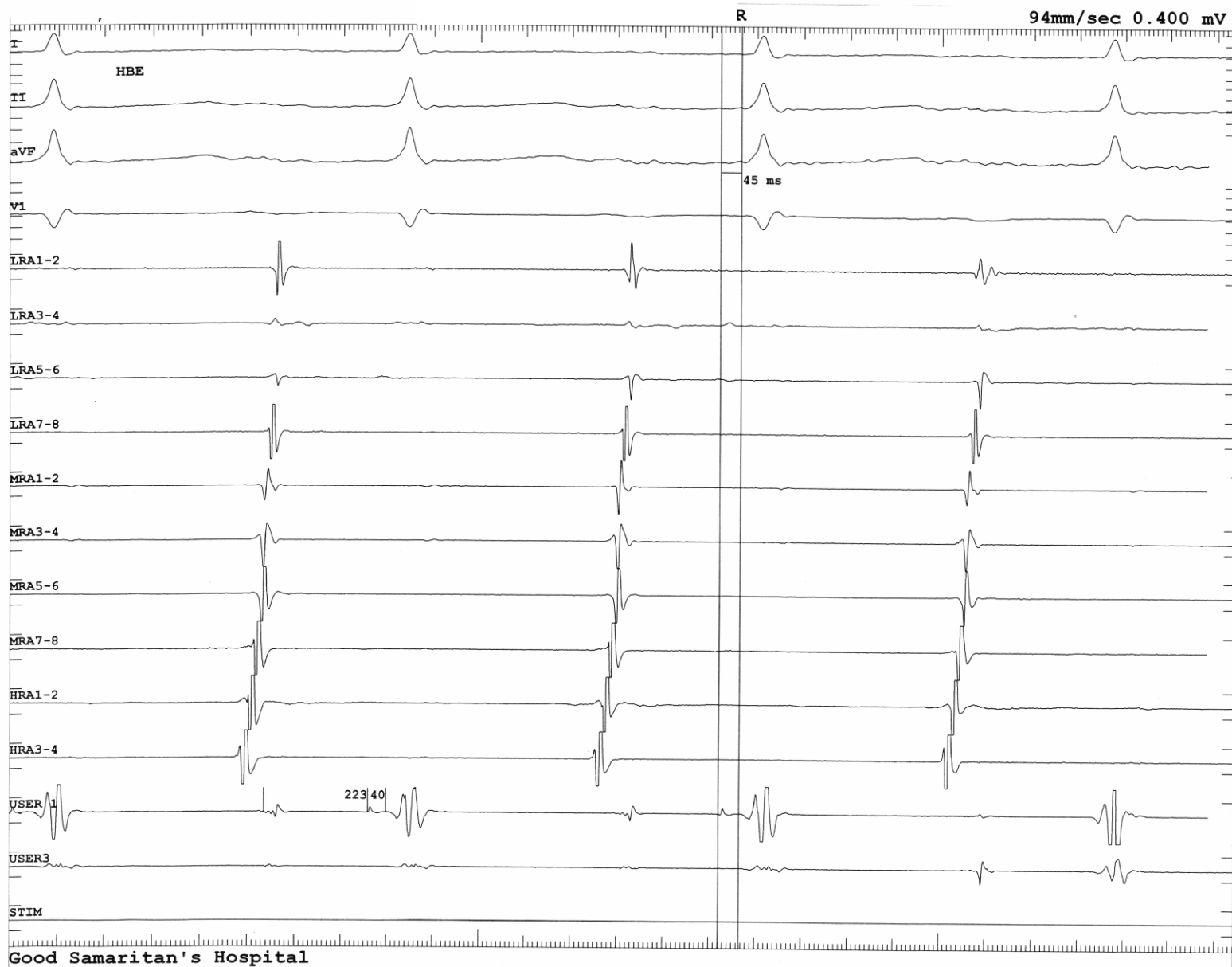


Good Samaritan's Hospital

Post ablation EKG – 1<sup>st</sup> degree AV block



Post Ablation Intracardiac Electrogram  
Note Prolonged AV interval (297ms)



User 1 (ablation catheter) moved to His position; H-V interval 45ms



Date

Total RF Time : 555 secs

TIME			POWER			TEMPERATURE			IMPEDANCE		
#	Start (H:M:S)	Duration (Secs)	Avg (W)	Max (W)	Max At (Secs)	Avg (°C)	Max (°C)	Max At (Secs)	Avg (Ω)	Max (Ω)	Max At (Secs)
1	08:47:18	120	48	52	40	53	59	68	97	106	18
2	08:49:19	52	37	51	13	54	67	39	104	142	47
3	08:54:01	120	48	52	88	53	62	120	96	107	80
4	08:56:02	93	35	51	13	57	65	26	94	137	93
5	09:05:27	120	35	52	27	56	67	42	95	122	44
6	09:07:28	52	16	32	52	57	64	40	96	134	51

3 total burn cycles