

Pediatric Cardiology

David Stultz, MD

Cardiology Fellow, PGY-6

January 24, 2006

PARADE



Who Is The World's Worst Dictator?

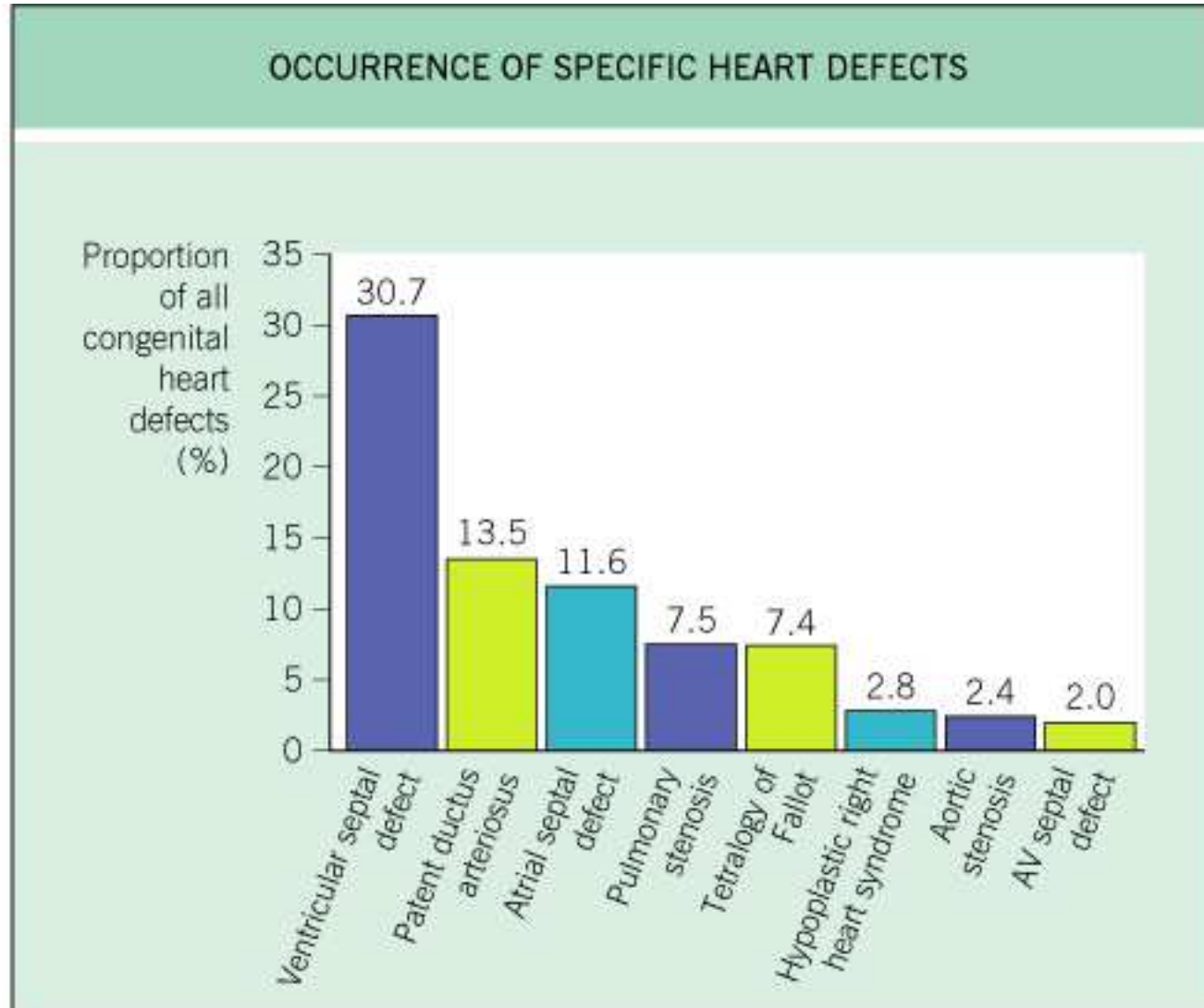
By David Wallechinsky

Plus... "Medical Facts...or Fiction?" by Dr. Isadore Rosenfeld • In Step With...Actress Cynthia Nixon

What is the incidence of Congenital Heart Disease?

| HYPOTHETICAL INCIDENCE OF CONGENITAL HEART DEFECTS | | | | | |
|---|-----------------------|-----|------------------------------|------------|----------|
| | | | Rate of occurrence of CHD | | |
| 100,000 | Pregnancies | | | | |
| <u>-22,000</u> | Spontaneous abortions | 20% | → | 4400 | with CHD |
| 78,000 | Continue pregnancy | | | | |
| <u>1,560</u> | Stillbirths | 10% | → | 156 | with CHD |
| 76,440 | Live births | 1% | → | <u>764</u> | with CHD |
| | | | | 5,320 | with CHD |
| Incidence = $\frac{5,320 \text{ with CHD}}{100,000 \text{ pregnancies}} = 5.32 \text{ per } 1000 \text{ pregnancies}$ | | | | | |
| Prevalence at birth = $\frac{764}{76,440 \text{ live births}} = 1.0 \text{ per } 1000 \text{ live births}$ | | | | | |

© 2004 Elsevier Ltd - Cardiology 2E, edited by Crawford, DiMarco and Paulus. All rights reserved.



© 2004 Elsevier Ltd - Cardiology 2E, edited by Crawford, DiMarco and Paulus. All rights reserved.

| DOMINANT HEART DEFECTS IN MALES AND FEMALES | |
|---|---|
| Males | Females |
| Hypoplastic left heart syndrome Double-outlet right ventricle Coarctation of the aorta Aortic stenosis D-transposition of the great arteries Pulmonary atresia Tricuspid atresia L-transposition of the great arteries | Atrial septal defect Patent ductus arteriosus Atrioventricular septal defects |

© 2004 Elsevier Ltd - Cardiology 2E, edited by Crawford, DiMarco and Paulus. All rights reserved.

COUNSELING PARENTS WHO HAVE A CONGENITAL HEART DEFECT

- Recurrence risk in offspring may approach 4–10%
- Risk may be higher if more than one relative is affected with congenital heart disease
- Recurrent heart defects in offspring are often similar to that of the parent
- If the mother has compromised cardiac status, she should be referred to a cardiologist for management of pregnancy and delivery, optimally before she conceives
- Fetal echocardiography is recommended in the second trimester
- Genetic karyotyping may be warranted if fetal echocardiography demonstrates a heart defect

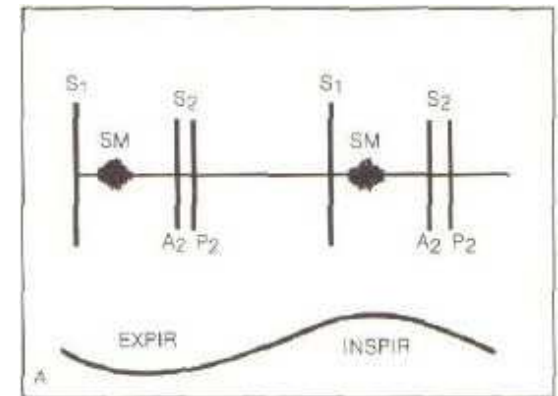
© 2004 Elsevier Ltd - Cardiology 2E, edited by Crawford, DiMarco and Paulus. All rights reserved.

Case 1

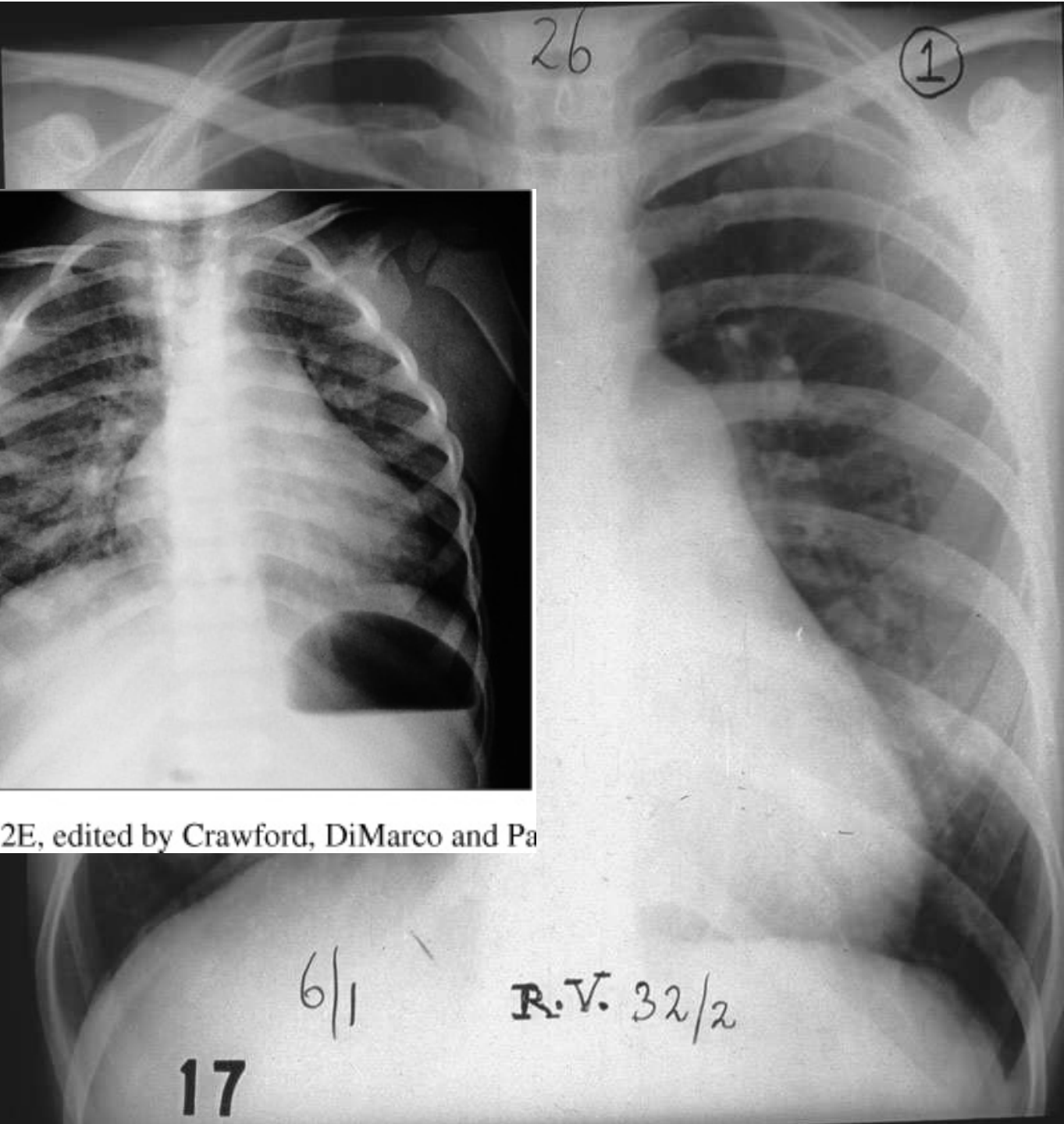
- 9 year old female referred for evaluation of murmur, heard on pediatric exam 1 week ago
- No prior history is available
- Child does not recall any hospitalizations
- No Medications
- Active in school gym, able to keep up with peers in physical activities

Case 1 – Physical Examination

- HR 90, SBP 95
- Gen: NAD
- HEENT: Normal Facies
- Neck: no JVD
- Lungs: CTA B
- Ext: 2+ pulses, no radio-femoral delay, no edema
- Heart



Ch



Cardiology 2E, edited by Crawford, DiMarco and Pa

- Head
indic
dilat

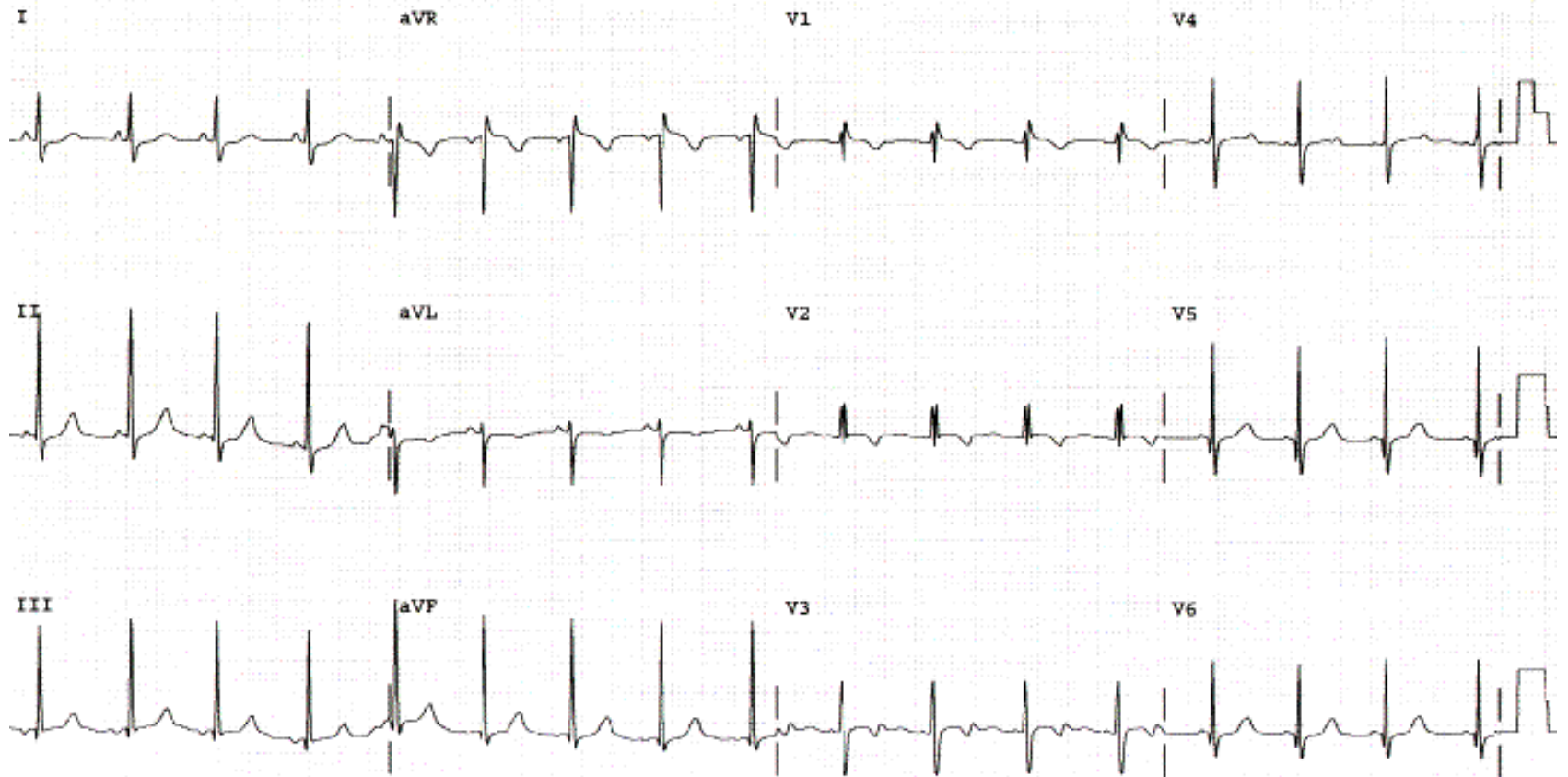
w
essels

EKG

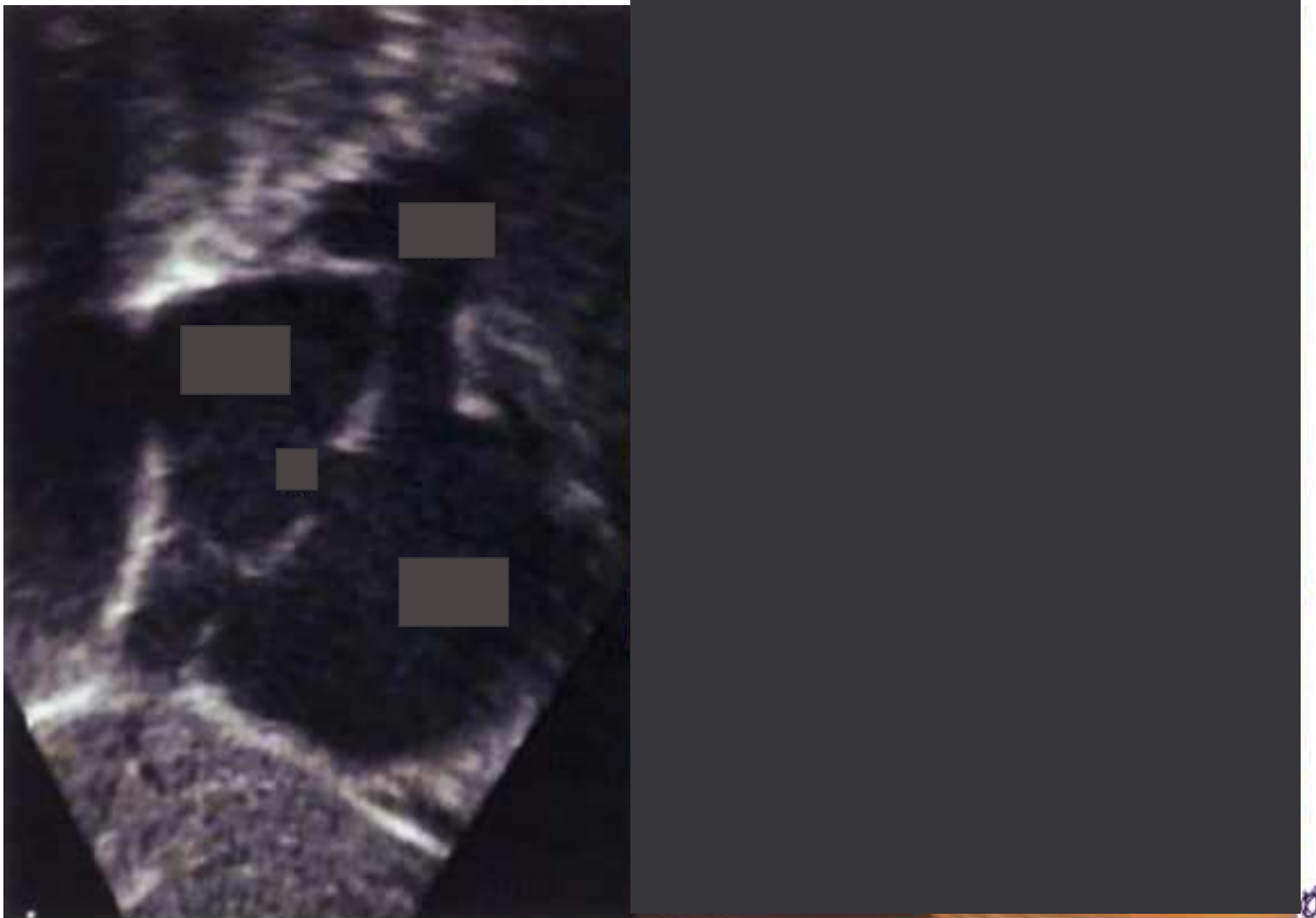PR 92
QRSD 70
QT 308
QTc 401

--AXES--
P -5
QRS 85
T 72

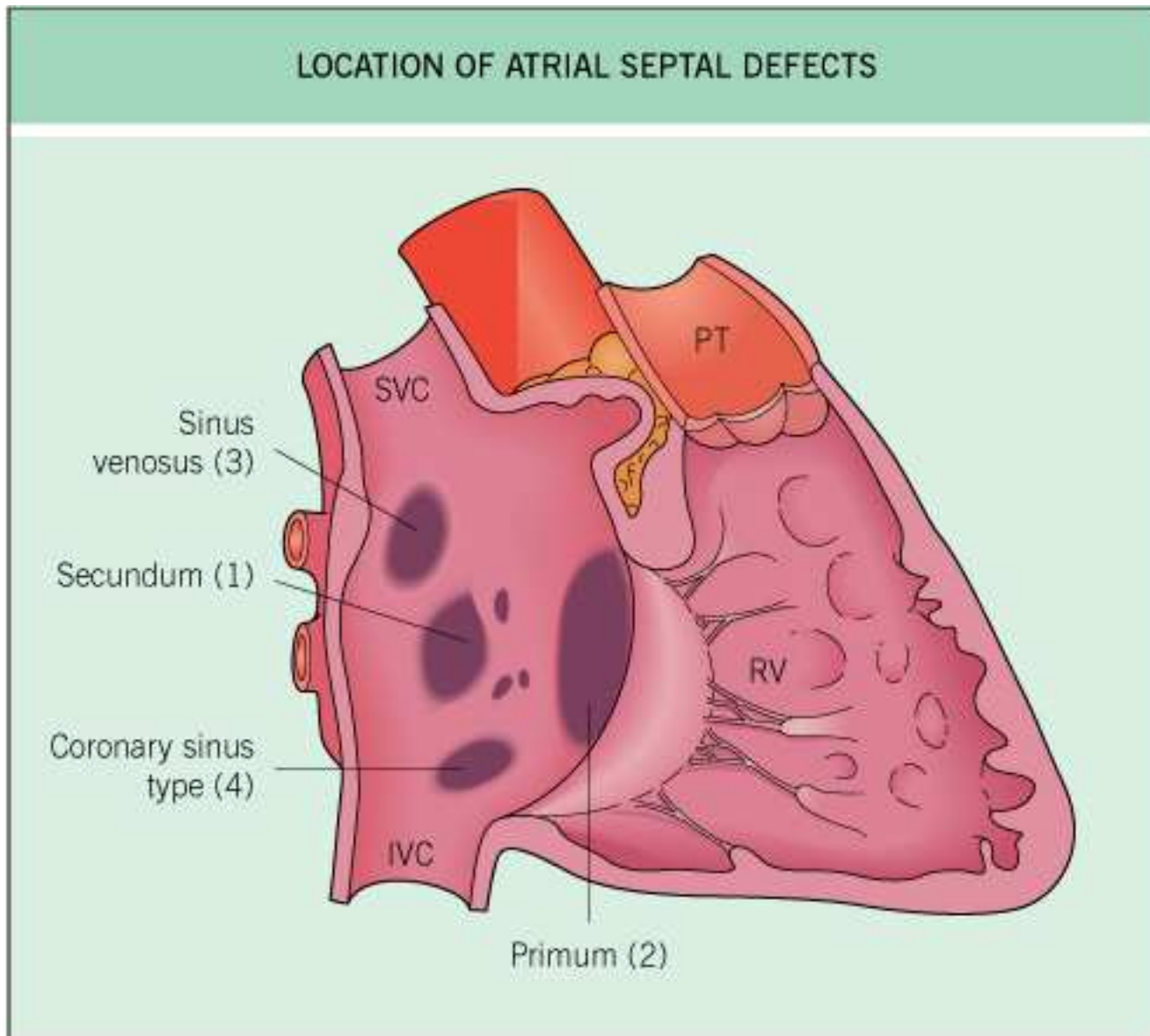
THE UNIVERSITY OF KANSAS MEDICAL CENTER - PEDIATRIC CLINIC



Echo

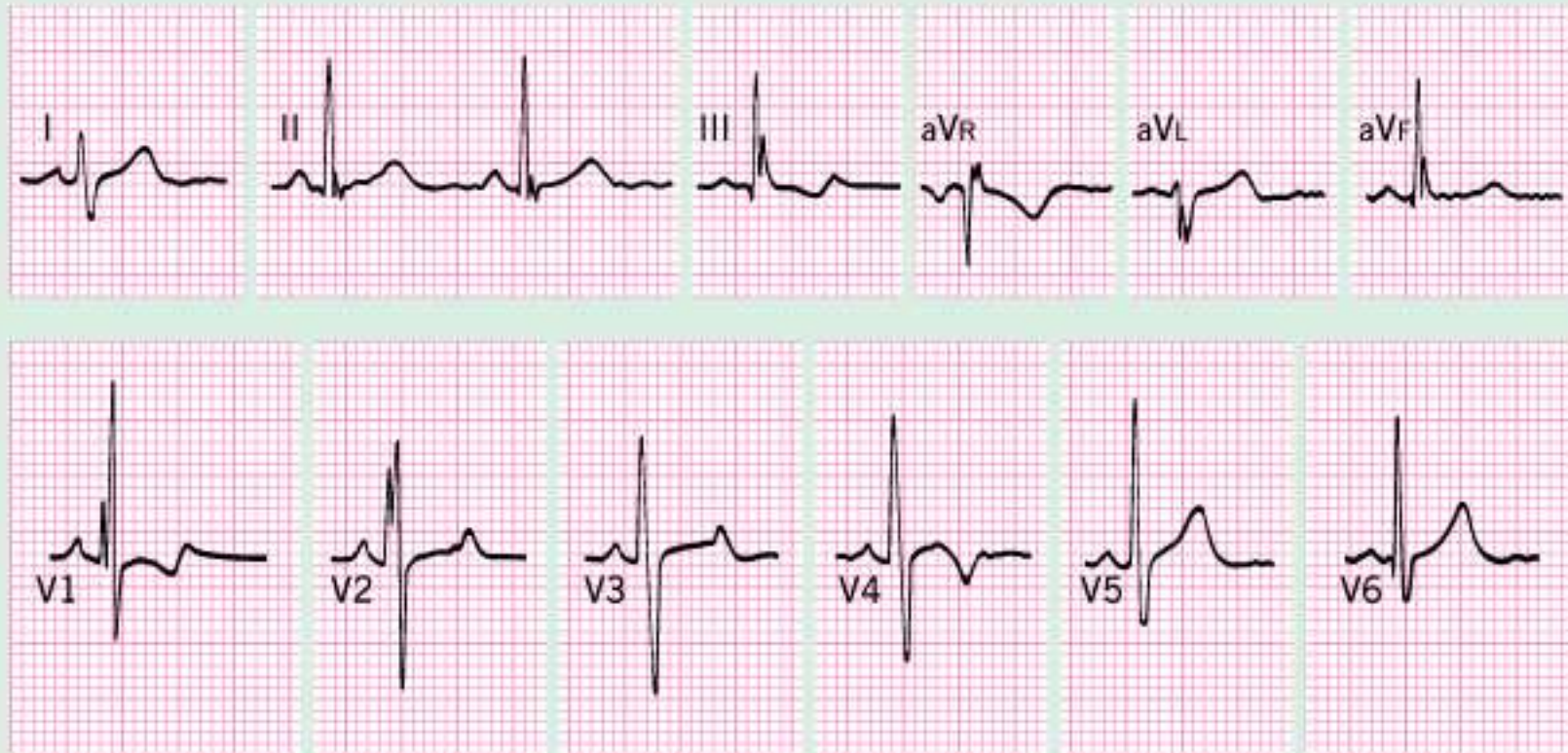

B



© 2004 Elsevier Ltd - Cardiology 2E, edited by Crawford, DiMarco and Paulus. All rights reserved.

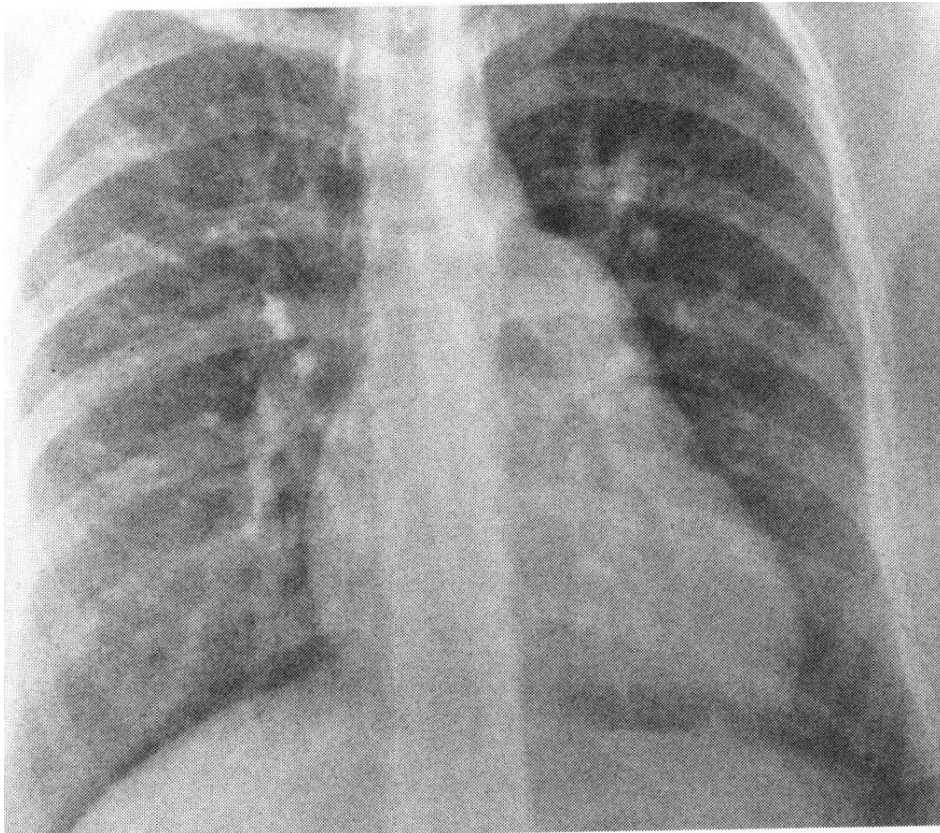
ELECTROCARDIOGRAPHIC FINDINGS IN SECUNDUM ARTIAL SEPTAL DEFECT



Atrial Septal Defect Secundum

- Often recognized in early childhood
- Incidence approximately 1 in 2000 live births
- Prominent RV impulse
- Fixed split S₂
- Surgical intervention at age 4-5 years for asymptomatic children
 - Generally recommended for Qp/Qs >1.5
 - Early intervention for symptomatic children
- Natural history – unrepaired ASD's develop atrial fibrillation in 40's-50's
- Spontaneous closure in 14-66% of infants, usually by age 2-8 years
- Survival of patients operated before age 25 similar to general population
- Older age at repair is associated with late atrial fibrillation and decreased long term survival

Which of the following physical findings would not be associated with the congenital anomaly shown on this chest radiograph?



A. Right Ventricular Lift

B. Systolic Thrill

C. Diastolic Flow Rumble

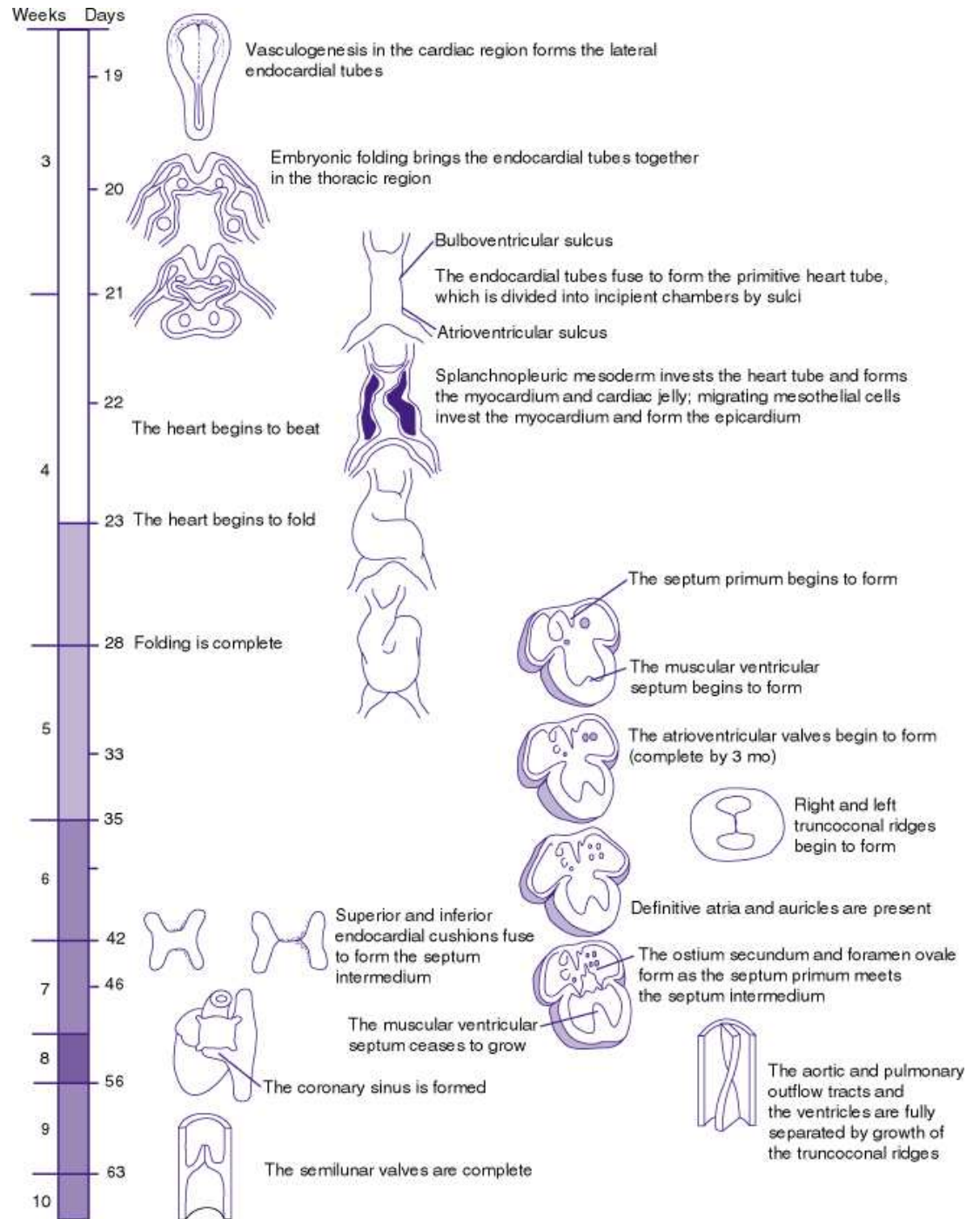
D. Normal Jugular

Pressure

E. Fixed Splitting of the second heart sound

This is a typical radiograph of a patient with a large secundum atrial septal defect. There is a large heart with a right ventricular contour, a prominent pulmonary artery, and plethora in the lung fields. A diastolic rumble would be expected because of the increased flow across the tricuspid valve. Secundum atrial septal defect is never associated with a systolic thrill

Brief Embryology

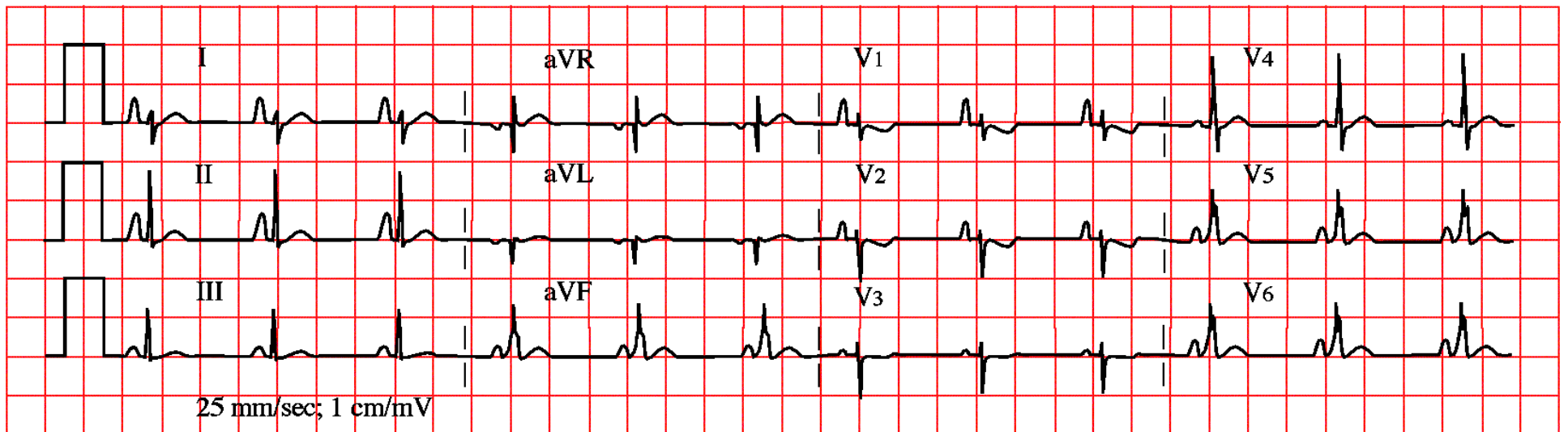


TIMELINE. FORMATION OF THE HEART.

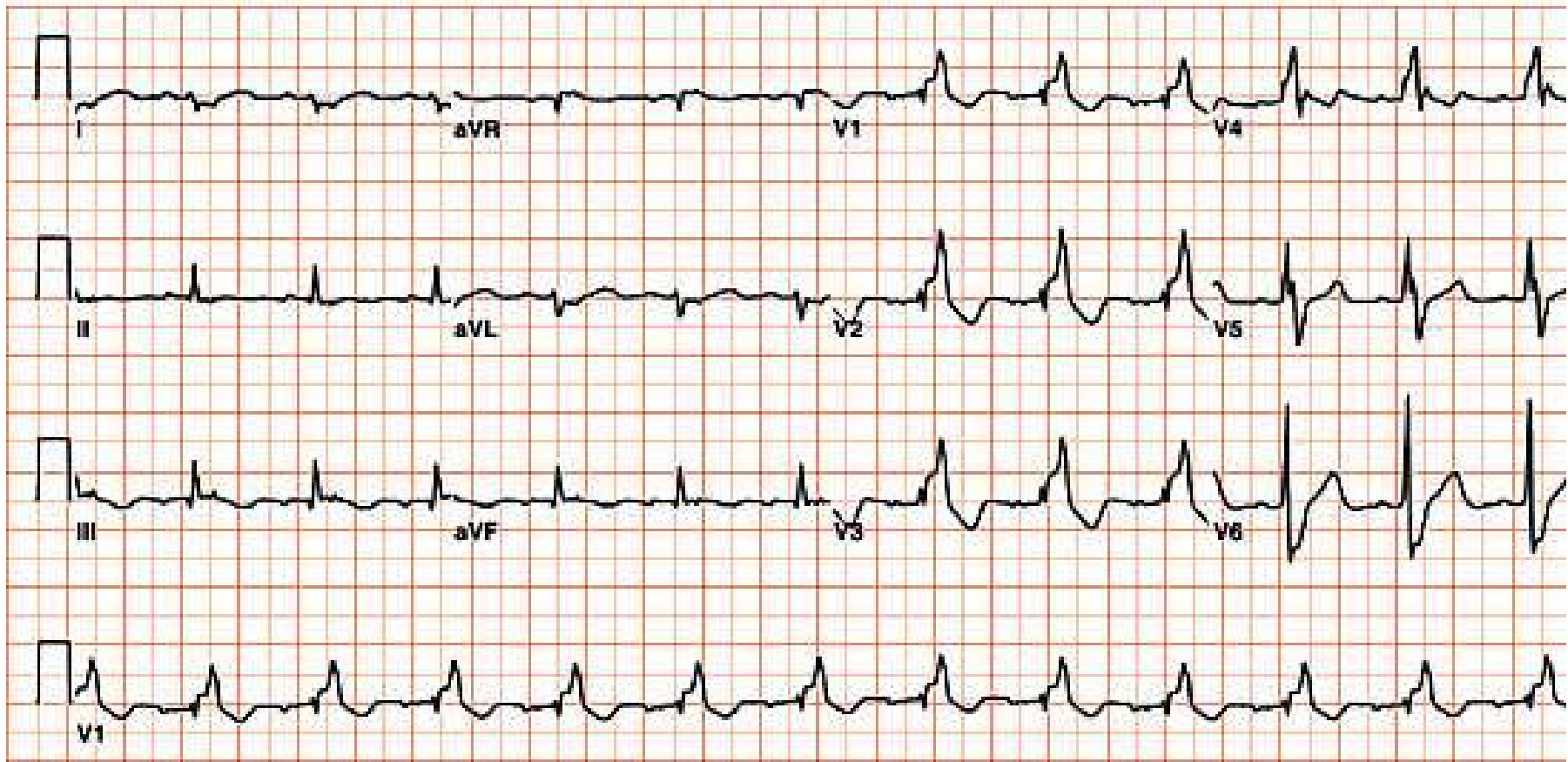
Patient 2

- 14 year old male referred for palpitations
 - These occur during exertion, with an abrupt onset. These were noticed about 1 year ago, and have become more frequent. Palpitations last about 5-10 minutes, and resolve with rest. During palpitations, he is somewhat short of breath. There is no presyncope or syncope.
- No medications
- Plays basketball

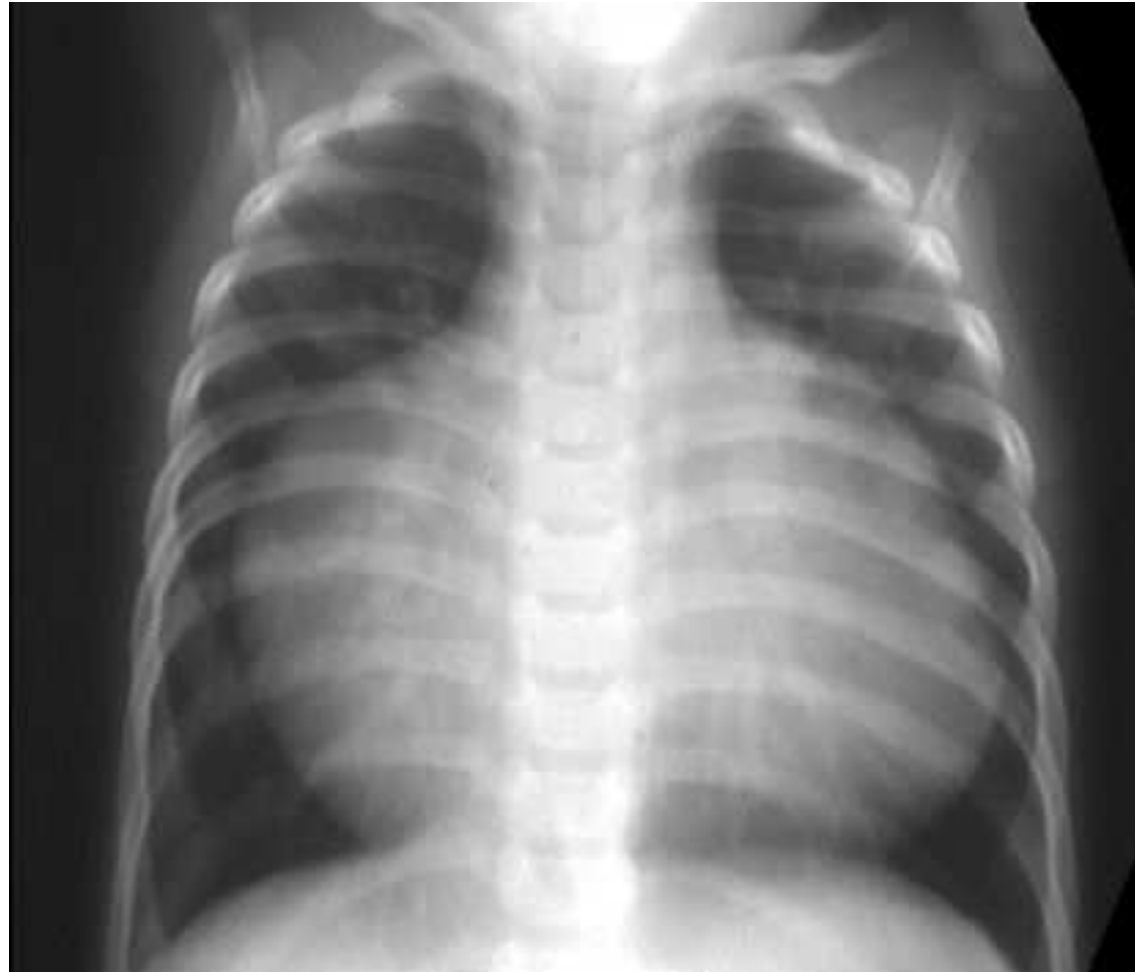EKG



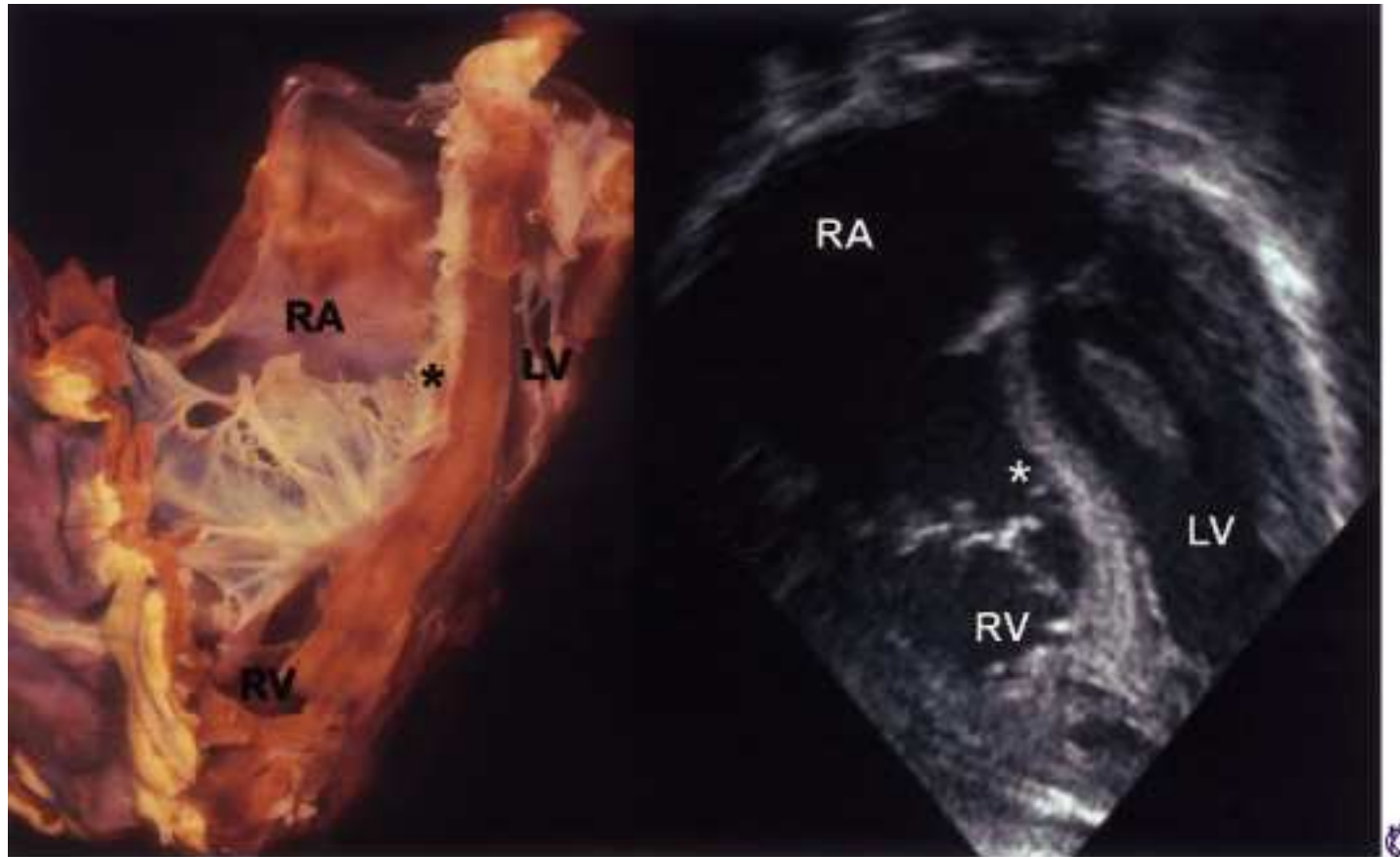
Another EKG



Chest Xray (Infant)

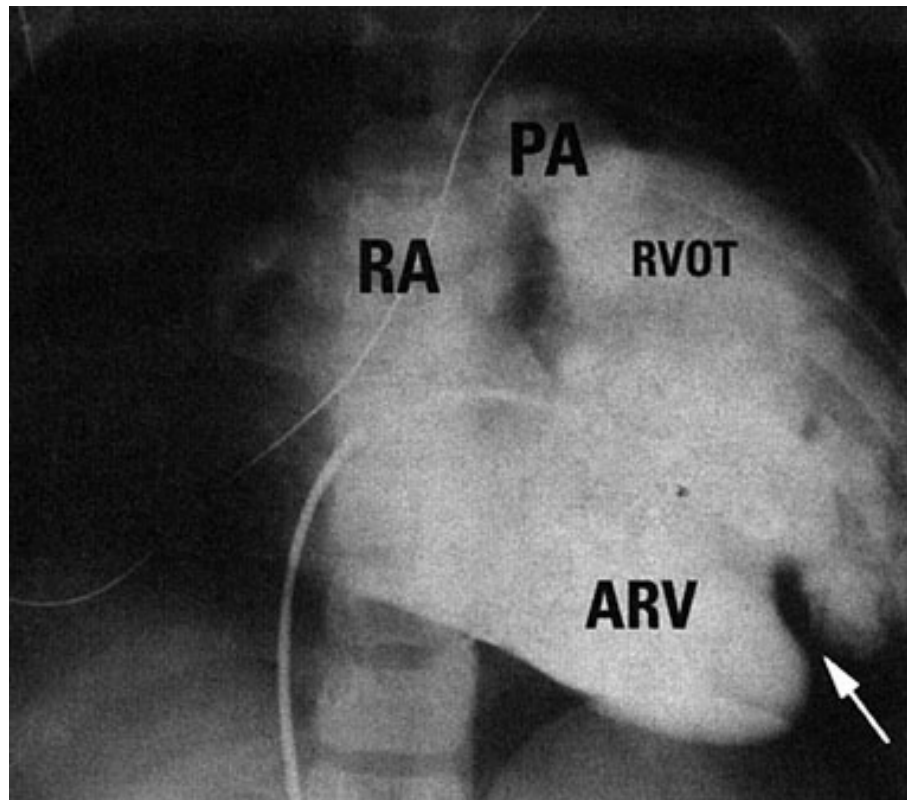


Echocardiography



Copyright © 2005 by Elsevier Inc.

Right Ventriculogram



Right ventricular angiogram showing a notch of the displaced tricuspid valve (arrow) on the diaphragmatic surface of the right ventricle, typical of Ebstein's anomaly of the tricuspid valve. ARV, atrialized right ventricle; PA, pulmonary artery; RA, right atrium; RVOT, right ventricular outflow tract.

Invasive catheterization of RV

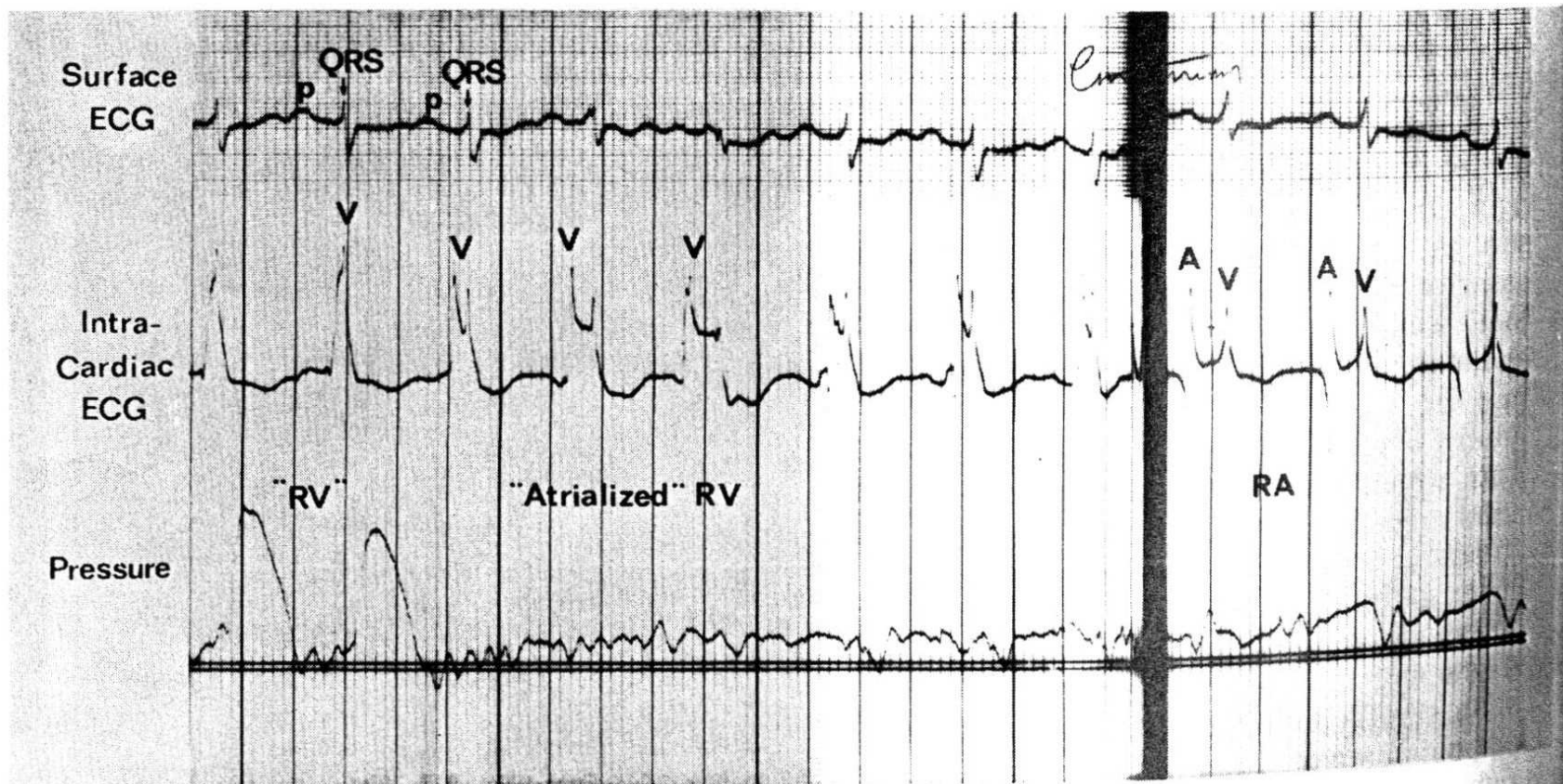


Fig. 28-16. Surface ECG, intracardiac ECG, and pressure recording in a 15-year-old girl with Ebstein's disease. As catheter is withdrawn from right ventricle (RV) (left) to right atrium (right), one sees an RV electrogram with RV pressure in the body of the RV, and RV electrogram with atrial pressures in the "atrialized" portion of the RV, and an atrial electrogram with atrial pressures in the true right atrium. V and A refer to ventricular and atrial depolarization, respectively.

Ebstein's Anomaly

- 0.5-1% of congenital heart disease
- Variable degrees of displacement of mural and septal leaflets of the tricuspid valve
- May be mild – some patients live into 70's-80's
- Most common associated defect is secundum type atrial septal defect
- Also associated with Wolff-Parkinson-White syndrome
- Some infants present with heart failure and gigantic hearts – poor prognosis
- Predictors of poor outcome include pulmonary atresia, increased displacement of the tricuspid valve and more severe tricuspid regurgitation, larger atrioventricular septal defect, and reduced left ventricular function

Ebstein's anomaly of the tricuspid valve is associated with all of the following except:

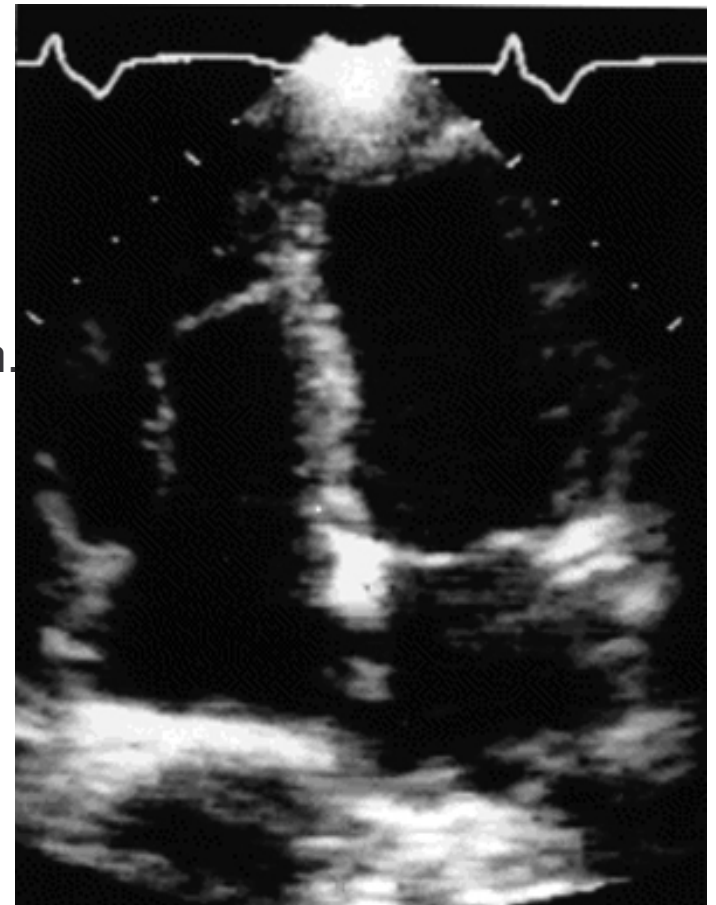
- A. A systemic right ventricle with a high incidence of right ventricular failure
 - B. Patent foramen ovale or atrial septal defect
 - C. Wolff-Parkinson-White syndrome
 - D. First degree AV block
- (Note: The text for option C is partially obscured by a large watermark in the image.)*

A 60-year-old white woman presents with a history of occasional episodes of paroxysmal atrial tachycardia. She has admitted to intermittent chest discomfort not always associated with activity, lasting 15 minutes to over an hour for the past 10 years. She smokes two packs of cigarettes per day. She is sent to you because her primary care physician heard a murmur. The patient can walk two flights of stairs and feels that she is normal for a 60-year-old. The chest X-ray reveals a globular heart and clear lung fields. The heart is slightly enlarged. The ECG shows a right bundle branch block. The echocardiogram is shown.

The most likely diagnosis is:

- A. Right ventricular dysplasia.
- B. Cardiomyopathy.
- C. Ebstein's anomaly.
- D. Atrial septal defect.
- E. Mitral valve prolapse with mitral regurgitation.

The correct answer is C. This patient has physical findings that are all consistent with Ebstein's disease. The echocardiogram in the four-chamber view is typical for Ebstein's disease, with deep displacement of the septal leaflet into the cavity of the right ventricle.



Can this patient play competitive sports? (Ebstein's Anomaly alone)

- 1. Athletes with a mild expression of Ebstein's anomaly without cyanosis, with normal right ventricular size, and with no evidence of atrial or ventricular tachyarrhythmias can participate in all sports.**
- 2. Athletes with tricuspid regurgitation of moderate severity can participate in low-intensity competitive sports (class IA) if there is no evidence of arrhythmia on ambulatory ECG Holter monitoring other than isolated premature contractions.**
- 3. Athletes with severe Ebstein's anomaly are precluded from all sports participation. However, after surgical repair, low-intensity competitive sports (class IA) can be permitted if tricuspid regurgitation is absent or mild, cardiac chamber size on chest radiograph or by echocardiography is not substantially increased, and symptomatic atrial or ventricular tachyarrhythmias are not present on ambulatory ECG monitoring and exercise test. Selected athletes with an excellent hemodynamic result after repair may be permitted additional participation on an individual basis.**

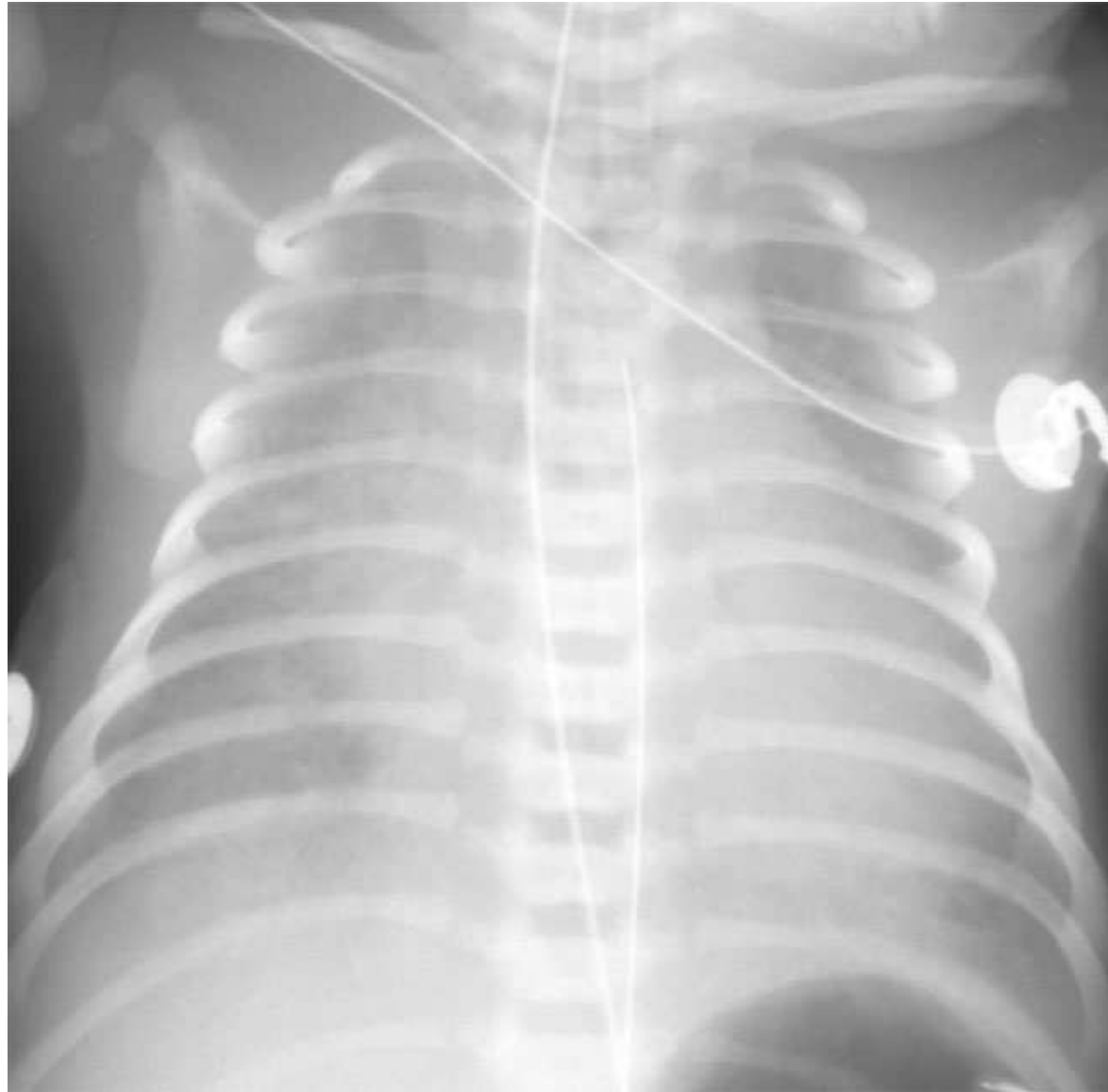
Can this patient play competitive sports? (WPW alone)

- 1. Athletes without structural heart disease, without a history of palpitations, or without tachycardia (particularly those 20 to 25 years old or more) can participate in all competitive sports. However, in younger age groups, a more in-depth evaluation including an electrophysiologic study may be recommended before allowing participation in moderate to high-intensity competitive sports.**
- 2. Athletes with episodes of AV reciprocating tachycardia should be treated as previously recommended (see section on Supraventricular Tachycardia). However, it should be appreciated that they can develop atrial fibrillation with rapid ventricular rates. Electrical induction of atrial fibrillation to determine the shortest QRS interval between two complexes conducted over the accessory pathway during isoproterenol administration or exercise is recommended. Those athletes in whom the shortest cycle length is less than 250 ms should undergo ablation of the accessory pathway.**
- 3. Athletes with episodes of atrial flutter/fibrillation and syncope or near syncope whose maximal ventricular rate at rest (without therapy) as a result of conduction over the accessory pathway exceeding 240 beats/min should be considered for catheter ablation therapy of the accessory pathway prior to continuing competition. Those whose ventricular rate during isoproterenol administration is less than 240 beats/ min and who have no episodes of syncope or near syncope appear to be at low risk for sudden cardiac death.**
- 4. Athletes with no structural heart disease who have had successful catheter or surgical ablation of the accessory pathway, are asymptomatic, and have normal AV conduction and no inducible arrhythmia by follow-up electrophysiologic study can participate in all competitive sports in several days. Those without an electrophysiologic study and no spontaneous recurrence of tachycardia for two to four weeks after ablation can participate in all competitive sports.**

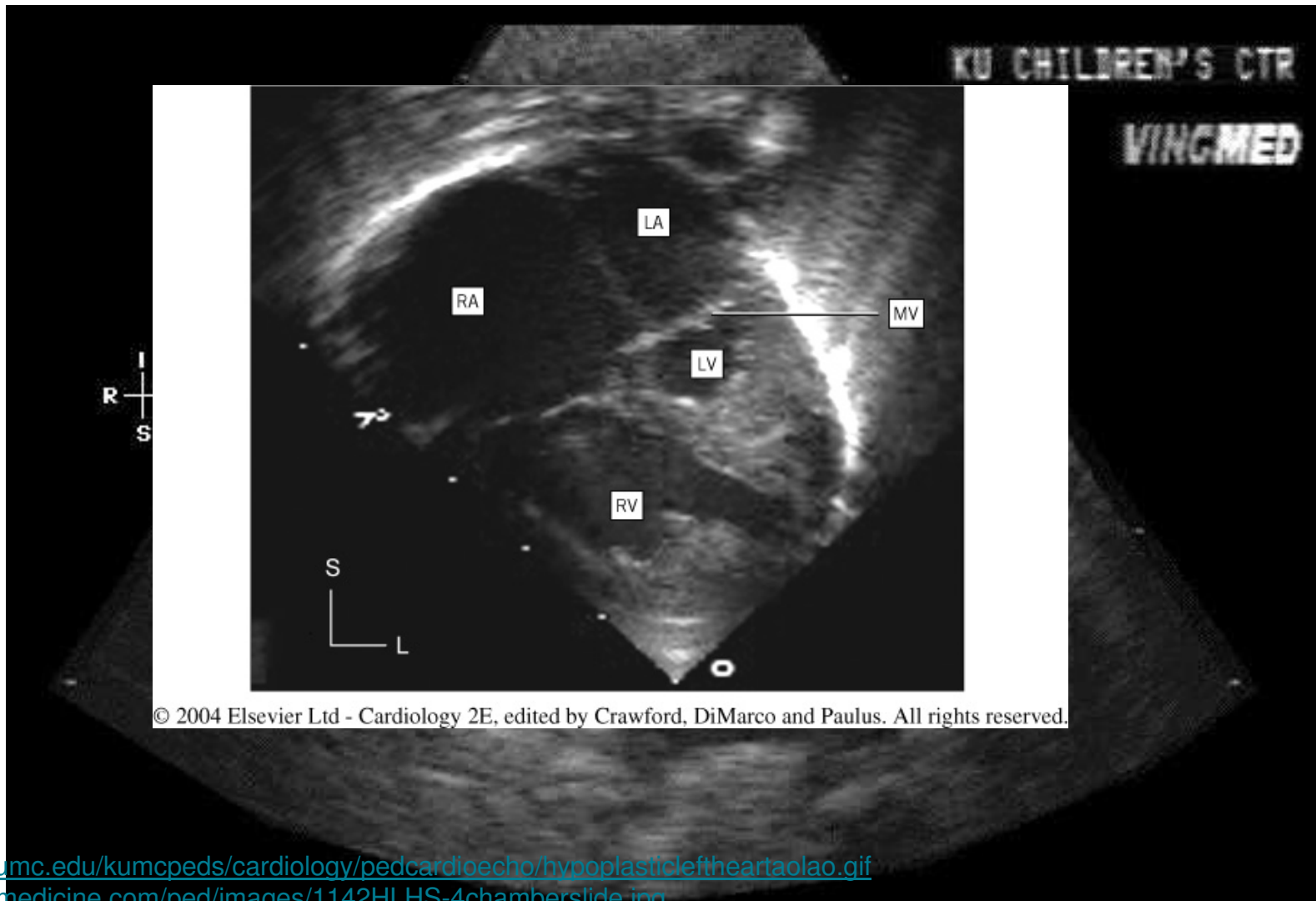
Case 3

- Female newborn, 4 hours old
- Progressive peri-oral and digital cyanosis
- Pulse ox 85%
- SBP noted to be falling
- Noted to have systolic murmur at birth

Chest Xray



Echo

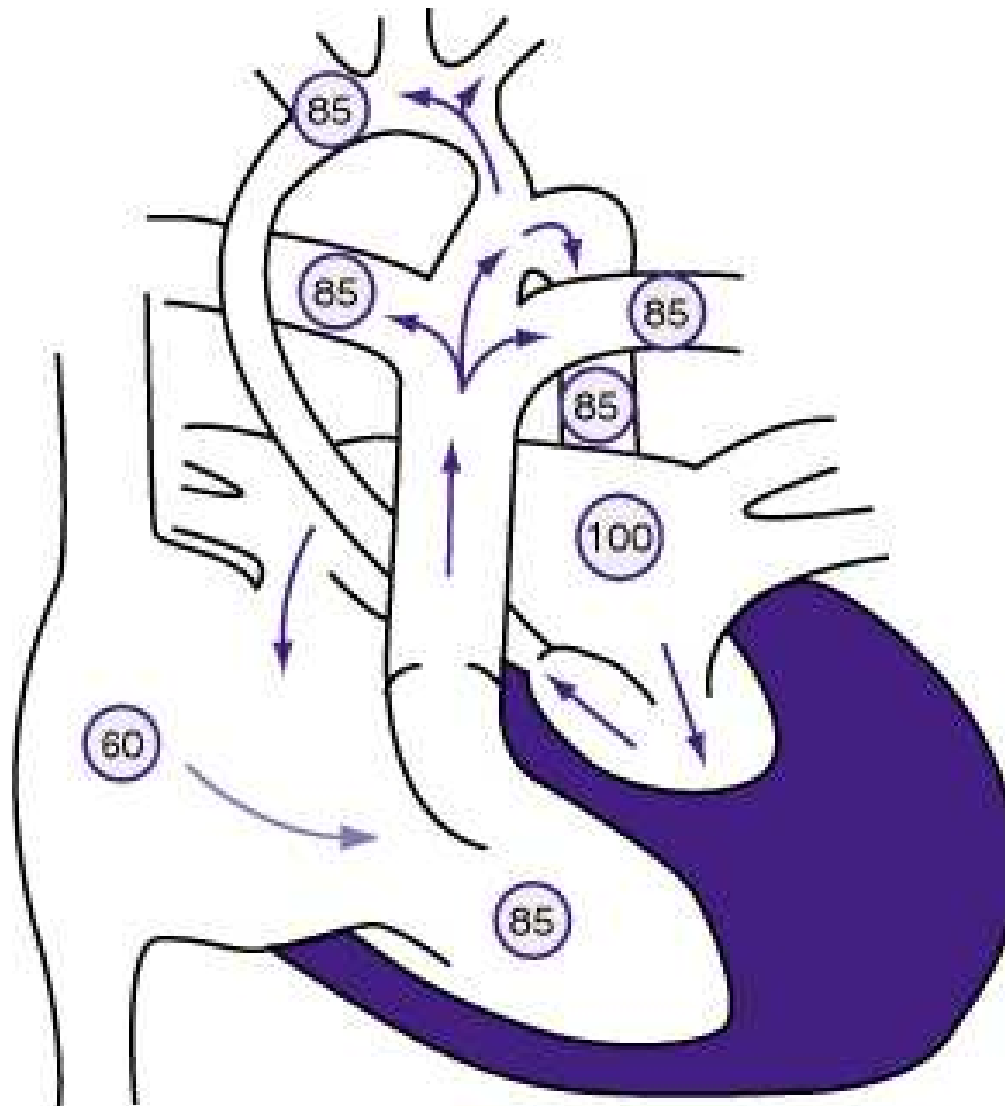


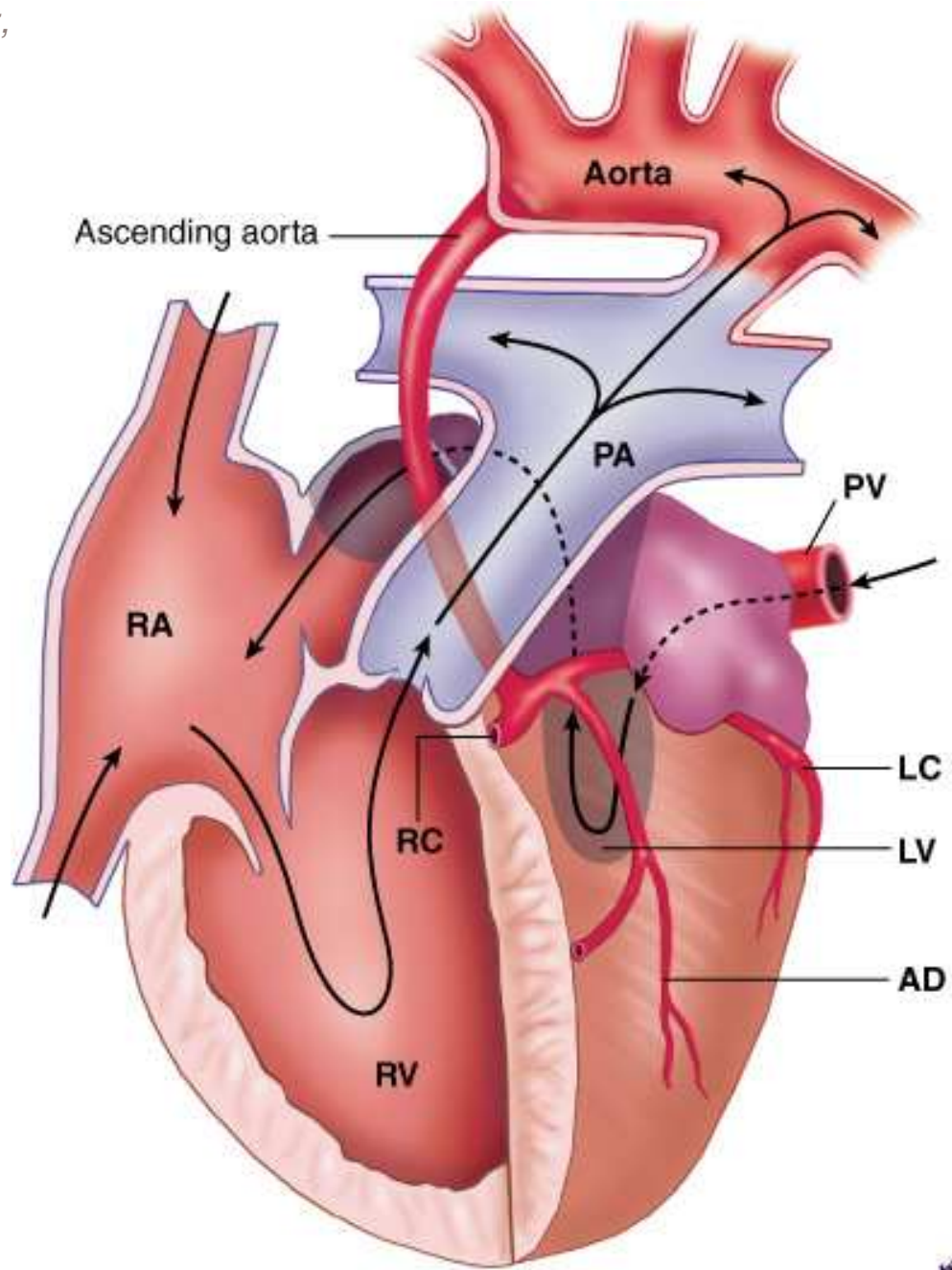
<http://www.kumc.edu/kumcpeds/cardiology/pedcardioecho/hypoplasticleftheartaolao.gif>

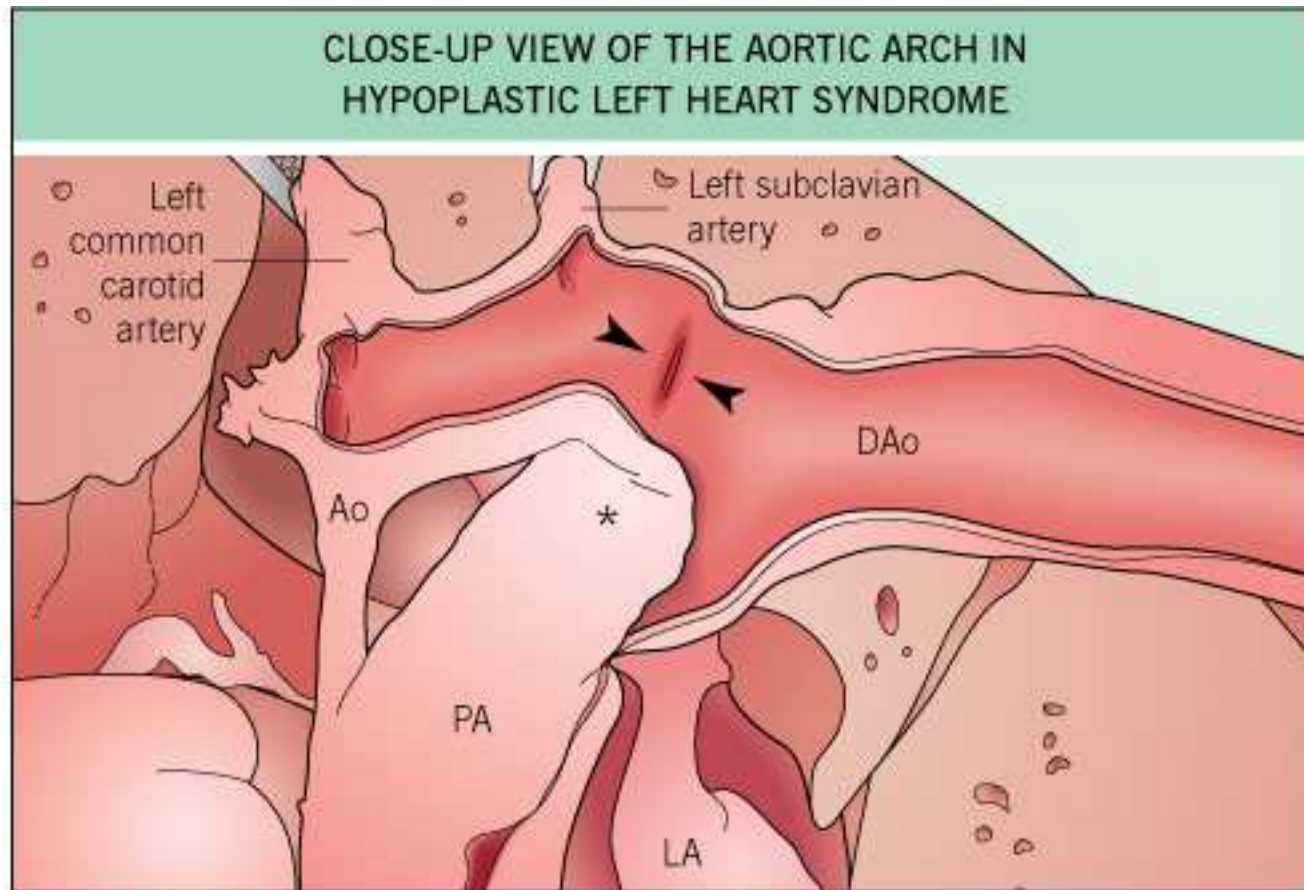
<http://www.emedicine.com/ped/images/1142HLHS-4chamberslide.jpg>

Crawford and DiMarco, 2nd ed

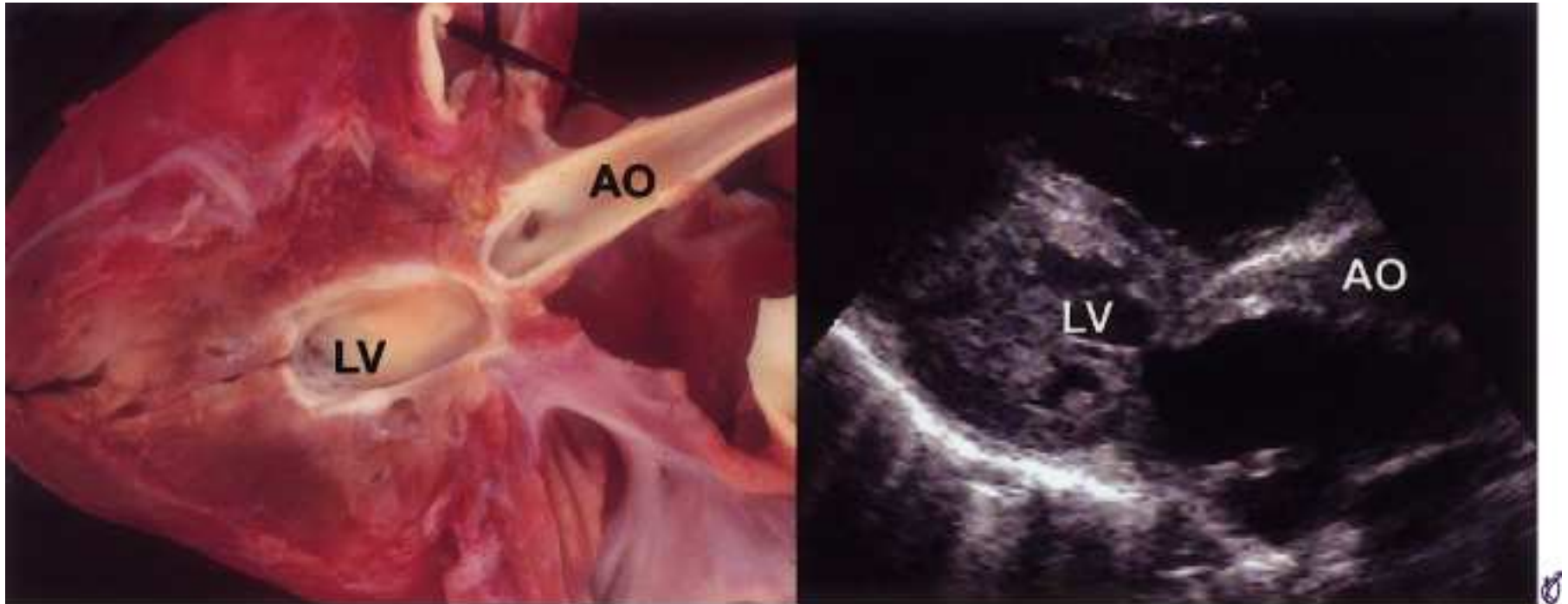
Hypoplastic Left Heart







© 2004 Elsevier Ltd - Cardiology 2E, edited by Crawford, DiMarco and Paulus. All rights reserved.



Copyright © 2005 by Elsevier Inc.

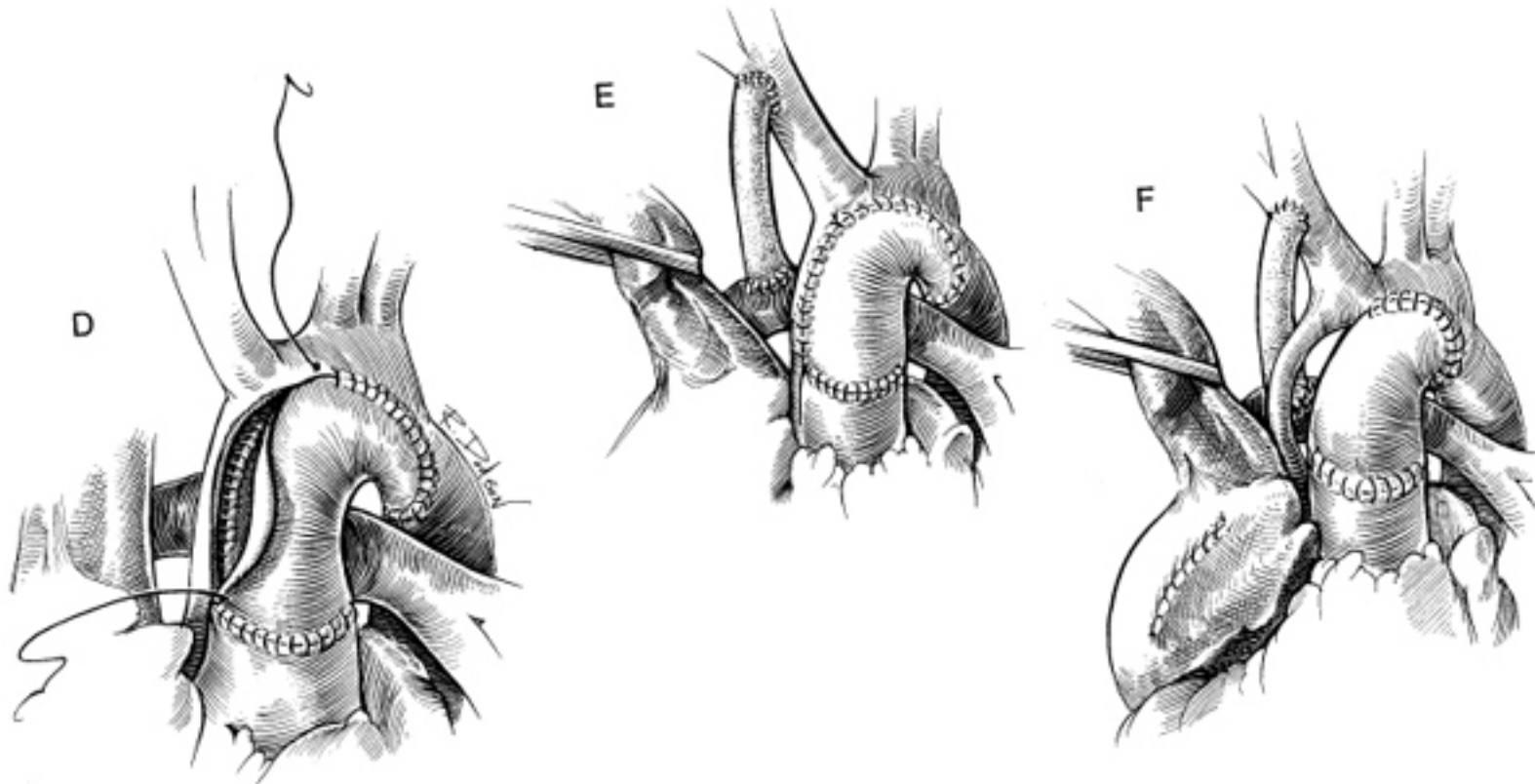
Initial Management of Hypoplastic Left Heart

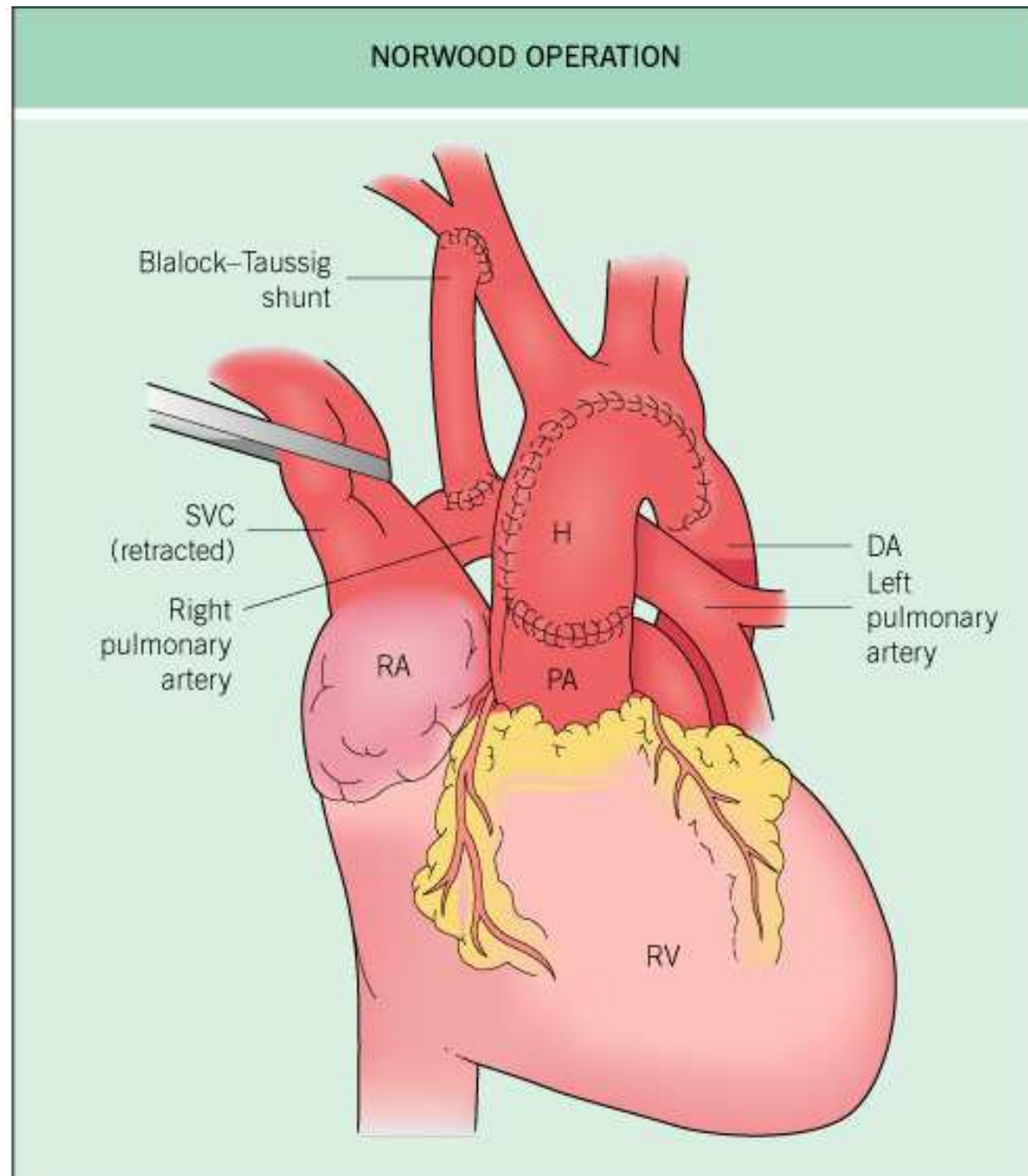
- Infuse Prostaglandin E
 - Important to maintain patency of ductus arteriosus
 - Correct metabolic acidosis
 - Ventilator support with paralysis
 - Judicious use of oxygen level, as high level may shunt blood to lungs

Definitive treatment of hypoplastic left heart

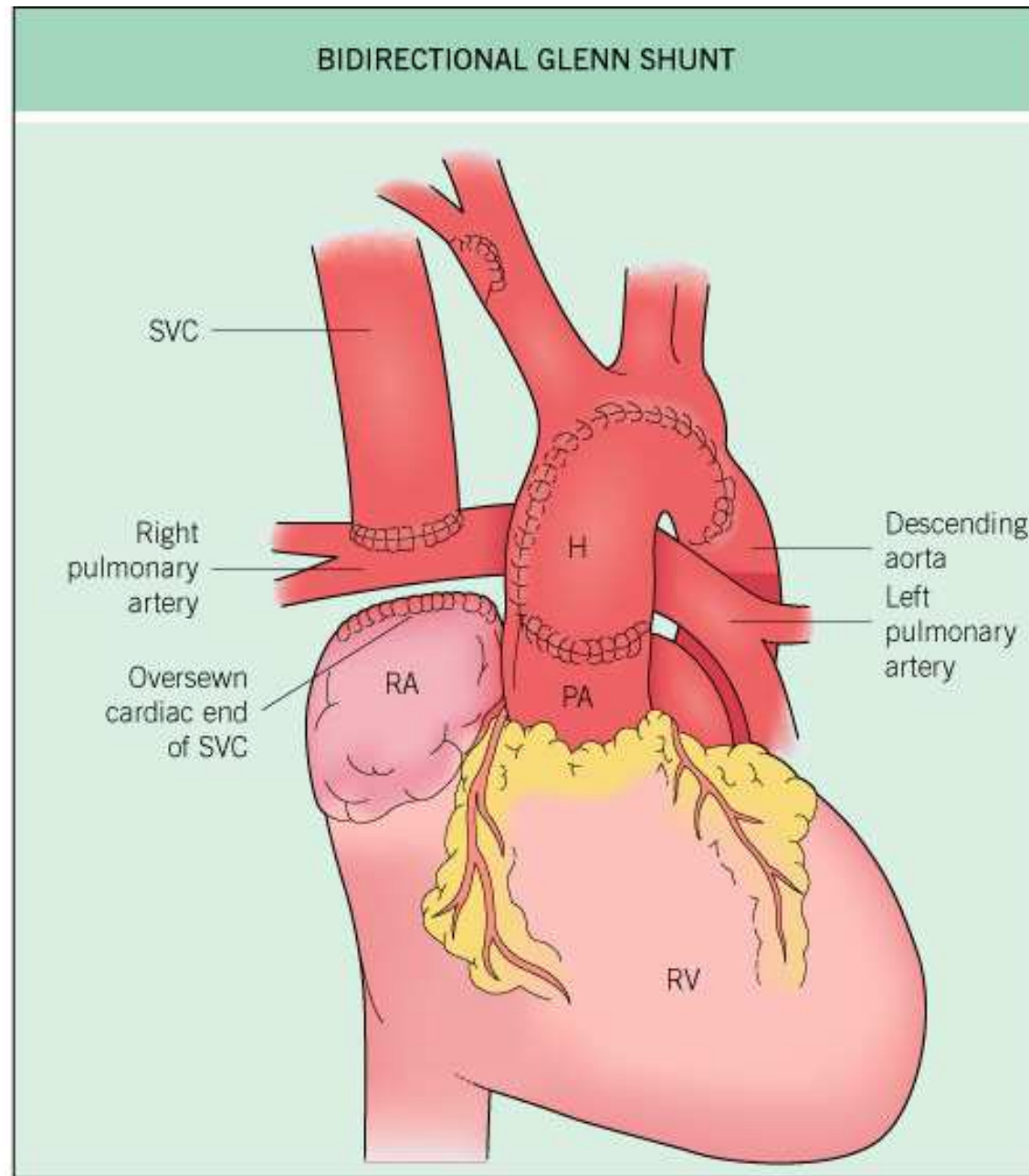
- Heart Transplant
- 3 stage surgical procedure
- Stage 1
 - Norwood procedure combines aorta and pulmonary artery
 - Blalock-Taussig shunt (Left subclavian artery to Left pulmonary artery)
- Stage 2 (3-9 months of age)
 - Bidirectional Glenn shunt – SVC connected to Left pulmonary artery
 - B-T shunt is removed
 - Atrial septum is removed
- Stage 3 (Fontan)

Surgery for hypoplastic left heart

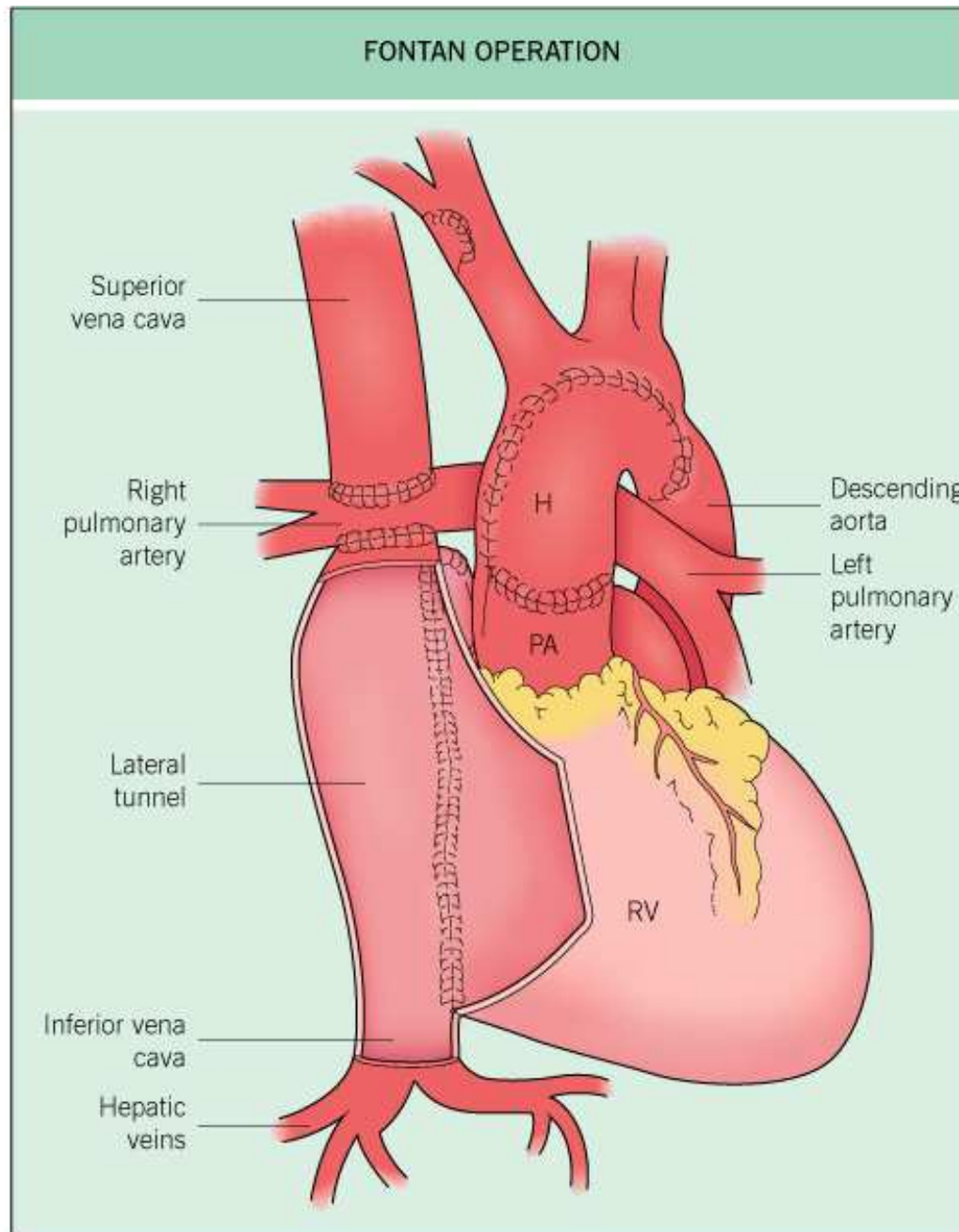




© 2004 Elsevier Ltd - Cardiology 2E, edited by Crawford, DiMarco and Paulus. All rights reserved.



© 2004 Elsevier Ltd - Cardiology 2E, edited by Crawford, DiMarco and Paulus. All rights reserved.



© 2004 Elsevier Ltd - Cardiology 2E, edited by Crawford, DiMarco and Paulus. All rights reserved.

The Fontan patient will have all of the following except:

- A. A long continuous murmur from the right atrial to pulmonary artery connection
- B. A normal S_1 and single S_2

C. Potential for protein-losing enteropathy

A. The Fontan procedure involves the direct connection of the right atrium to the pulmonary artery without an intervening ventricle. The physiology will be that of a systemic vein returning to the lungs and thus no systemic desaturation. The mitral and aortic closure will be normal and thus S_1 and S_2 will be normal. There will be no pulmonary component to the second heart sound since there is no pulmonary valve opening. A continuous murmur would not normally be present and would indicate the presence of a possible patent ductus arteriosus or a patent prior palliative systemic-to-pulmonary shunt. The higher than normal right atrial pressures and the development of lymphatic lymphangectasia results in a protein-losing state, which in some series is seen in up to 13% of patients.

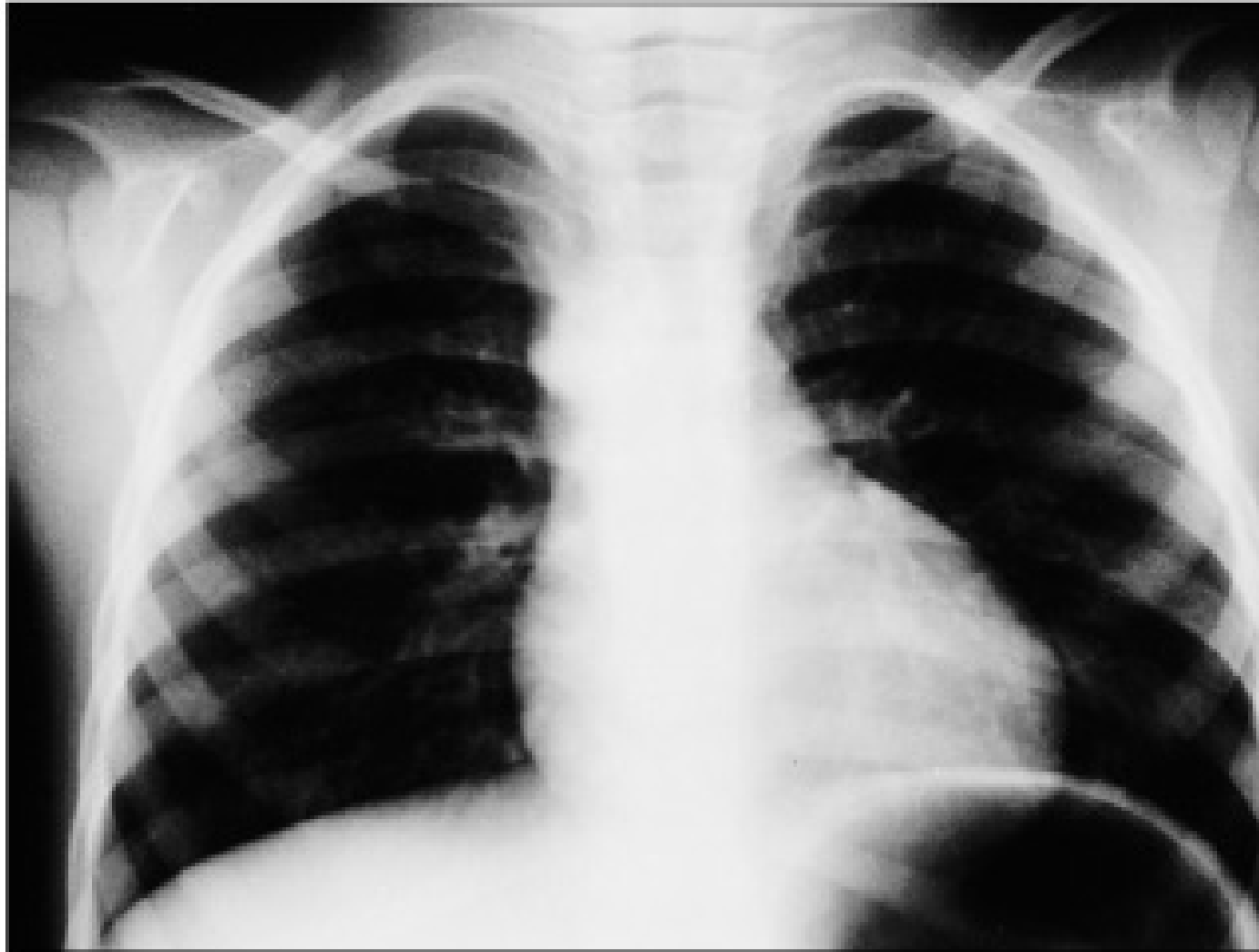
Case 4

- 7 month old male referred for heart murmur
- Mother admits to seeing bluish tinge of lips during feedings
- Baby seems to tire after feedings

Physical Exam

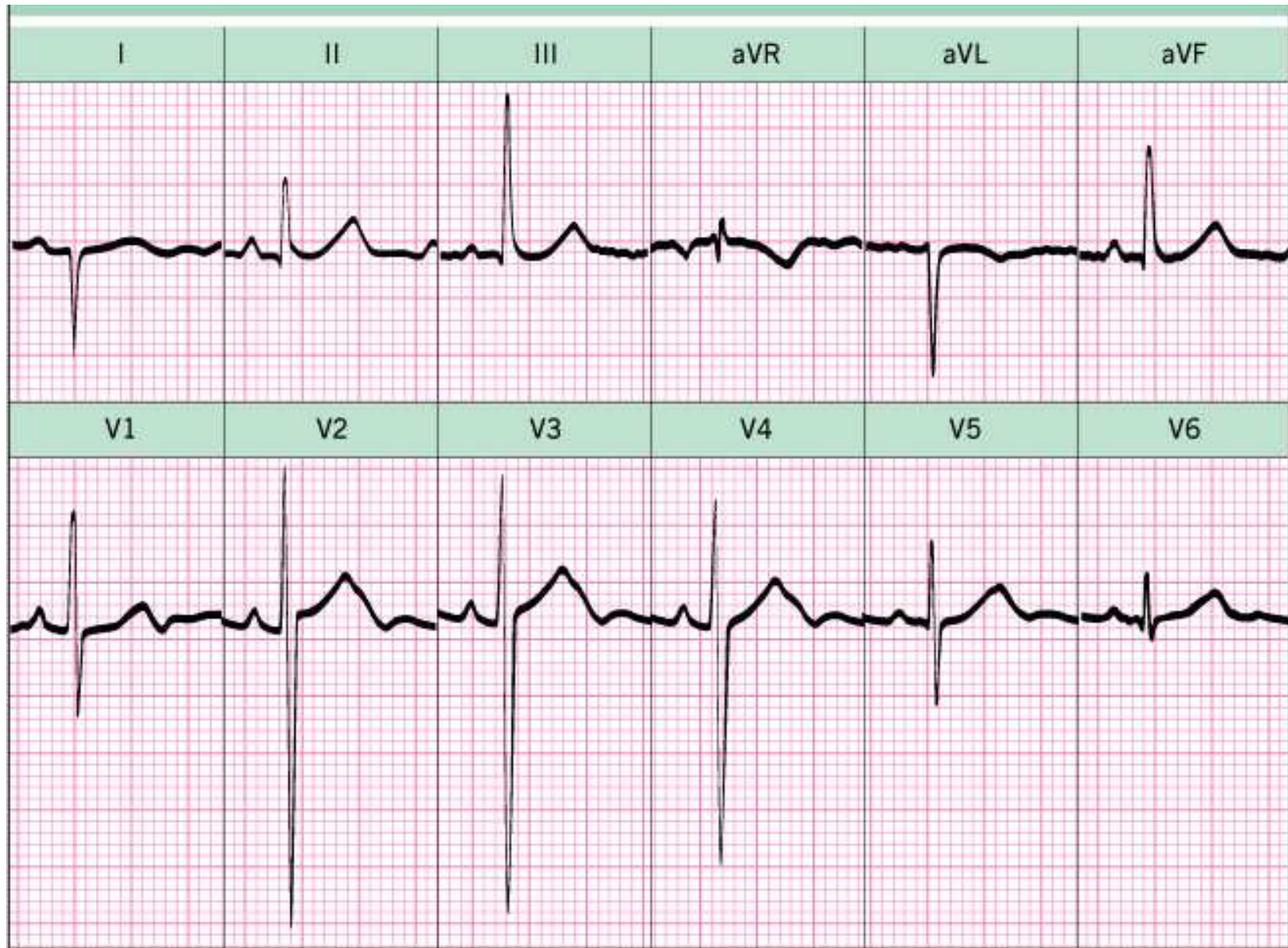
- Infant is at 15th percentile for length, 10th percentile for weight
- Cardiac impulse maximal at left lower sternal border
- Single S₂ heard at LLSB
- 3/6 Systolic Ejection murmur at LLSB
- Oxygen saturation 85%

Chest Xray

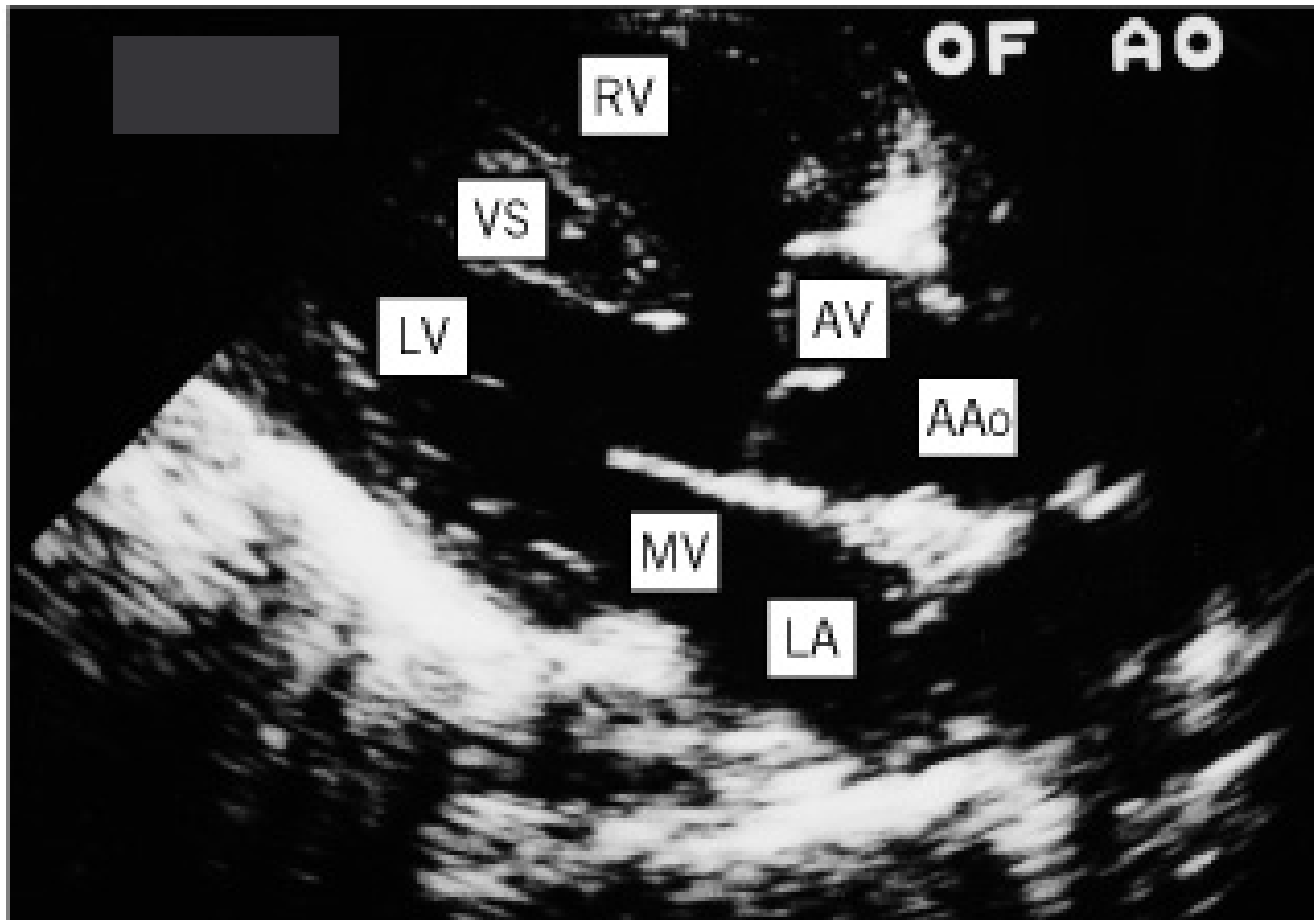


Cardiology 2E, edited by Crawford, DiMarco and Pa

EKG



Echocardiography



Cardiology 2E, edited by Crawford, DiMarco and Pa

Tetralogy of Fallot

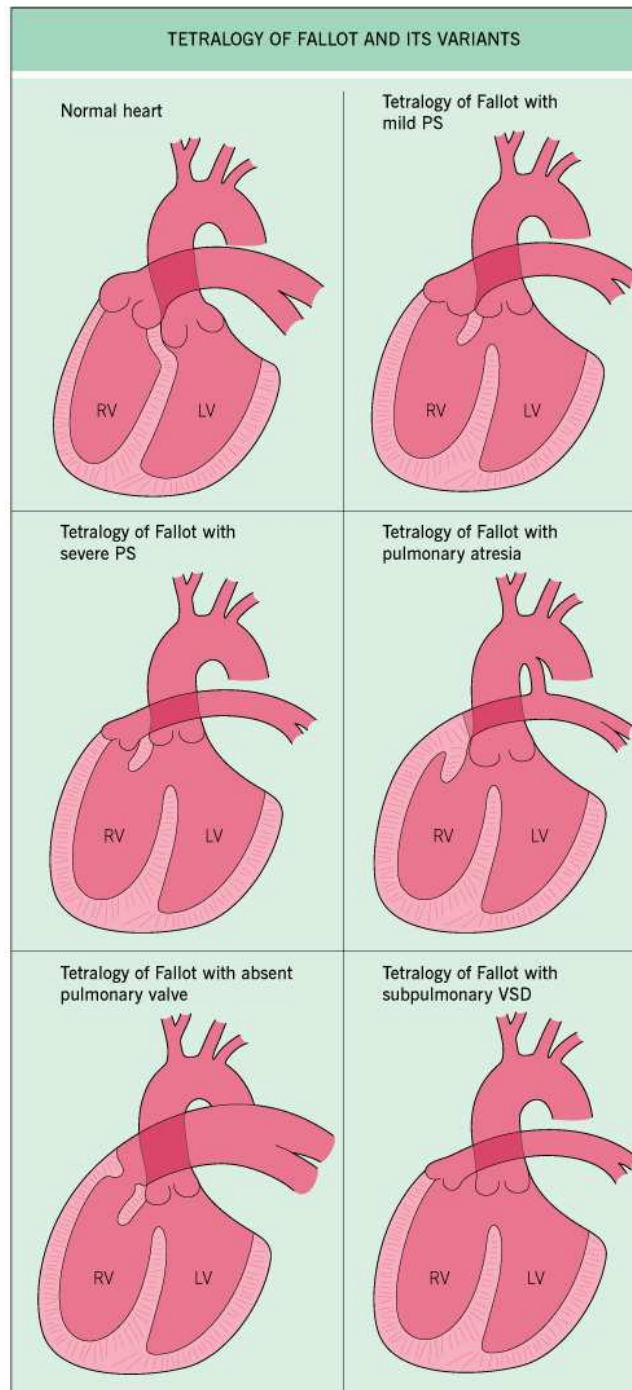
- 4-10% of all congenital heart disease
- Most common congenital cyanotic congenital heart disease
- 15% of tets have deletion of chromosome 22q11
 - Nasal voice, cleft palate, hypocalcemia
- Cyanosis develops in childhood

22q11 facies



Components of Tetralogy

- Pulmonary stenosis
 - Infundubular hypoplasia
- Ventricular septal defect
 - perimembranous
- Overriding aorta
- Right ventricular hypertrophy
- 10% have secundum ASD ('pentalogy')



Pathophysiology

- Cyanosis and murmur intensity related to degree of pulmonary/infundibular stenosis
- Crying, defecation and feeding lower SVR, increase venous return and pulmonary stenosis → cyanosis
- Squatting increases SVR
- Polycythemia and collateral circulation may develop

Associated Lesions

- Right aortic arch is present in 25-30% of patients with Tetralogy
 - More common with 22q11 deletion (40%)
- Anomalies of ductus arteriosus and pulmonary artery
- Coronary artery anomalies (5%)
- 22q11
- Trisomy-21 (6% of trisomy-21 patients have tetralogy)

Management

- Cyanotic spells initially managed medically
 - Squatting, knee to chest position
 - Propranolol
 - Fe supplementation if anemic
 - Emergency morphine, oxygen for severe/long lasting spell
- Palliative surgery
 - Blalock-Taussig shunt (subclavian artery to pulmonary artery)
 - Brock – pulmonary valvotomy
- Definitive surgery (age 3 months to 4 years)
 - RVOT reconstruction with patch closure of VSD
 - Surgical mortality <2%
 - Postoperative patients usually have RBBB and a to-and-fro murmur of pulmonary regurgitation

Prognosis

- Without surgery
 - 25% mortality at 1 year
 - 70% mortality at 10 years
- 90% of postoperative patients have an active life

A patient with tetralogy of Fallot has been palliated with a classic right Blalock-Taussig shunt from the subclavian artery to the pulmonary artery. All of the following would be expected findings except:

- A. Absent right radial pulse
- B. Harsh systolic ejection murmur along the left upper sternal border
- C. High pitched diastolic blow

D. Cyanosis and clubbing

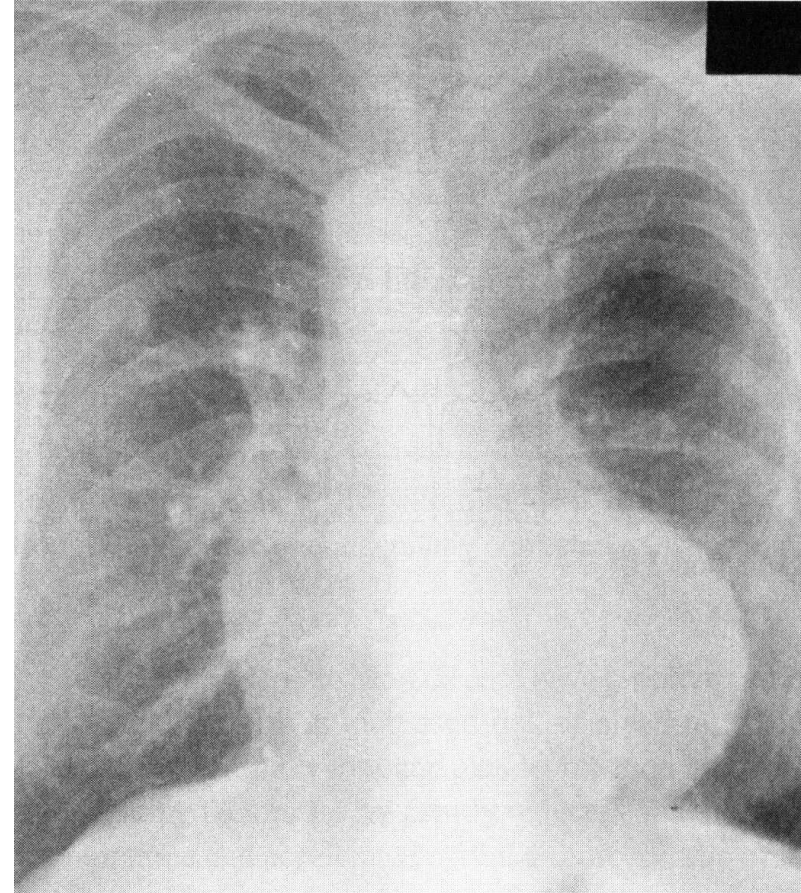
E. Continuous murmur along the right
intraclavicular region

C. The palliated tetralogy patient will have the intracardiac anatomy of tetralogy of Fallot with the VSD and infundibular pulmonary stenosis. This combination will result in right-to-left shunting and the harsh pulmonary outflow tract murmur. The palliated surgery will result in the connection of the high-pressure aorta and the low-pressure pulmonary artery, and thus the continuous murmur results. You should not hear the murmur of pulmonary or aortic insufficiency in the palliated tetralogy patient.

What is the most likely congenital anomaly shown on this chest radiograph?

- A. Congenitally corrected transposition
- B. Tricuspid atresia
- C. Primum atrial septal defect
- D. Eisenmenger syndrome
- E. Tetralogy of Fallot

E. This chest radiography shows a boot shaped heart, pulmonary oligemia, and a concave pulmonary bay, strongly suggestive of tetralogy of Fallot



Long term complications after repaired tetralogy of Fallot often include all of the following except:

- A. Aortic regurgitation
- B. Ventricular arrhythmias
- C. Pulmonary regurgitation
- D. Pulmonary hypertension
- E. Right ventricular dysfunction

D. Pulmonary hypertension is not associated with Tetralogy of Fallot because the pulmonary stenosis “protects” the lungs

References

- Brown AS. Educational Review Manual in Cardiovascular Disease. Castle Connolly Graduate Medical Publishing, Ltd, 2003.
- Crawford MH, DiMarco JP, Paulus WJ. Cardiology, 2nd ed. Mosby, 2004.
- Murphy JG. Mayo Clinic Cardiology Review, 2nd ed. Lippincott Williams & Wilkins, 2000.
- Topol EJ. Textbook of Cardiovascular Medicine, 2nd ed. Lippincott Williams & Wilkins, 2002.
- Zipes DP, Libby P, Bonow R, Braunwald E. Braunwald's Heart Disease: A Textbook of Cardiovascular Medicine, 7th ed. W.B. Saunders, 2004.