Cardiac CT

David Stultz, MD
Cardiology Fellow, PGY 6
March 28, 2006

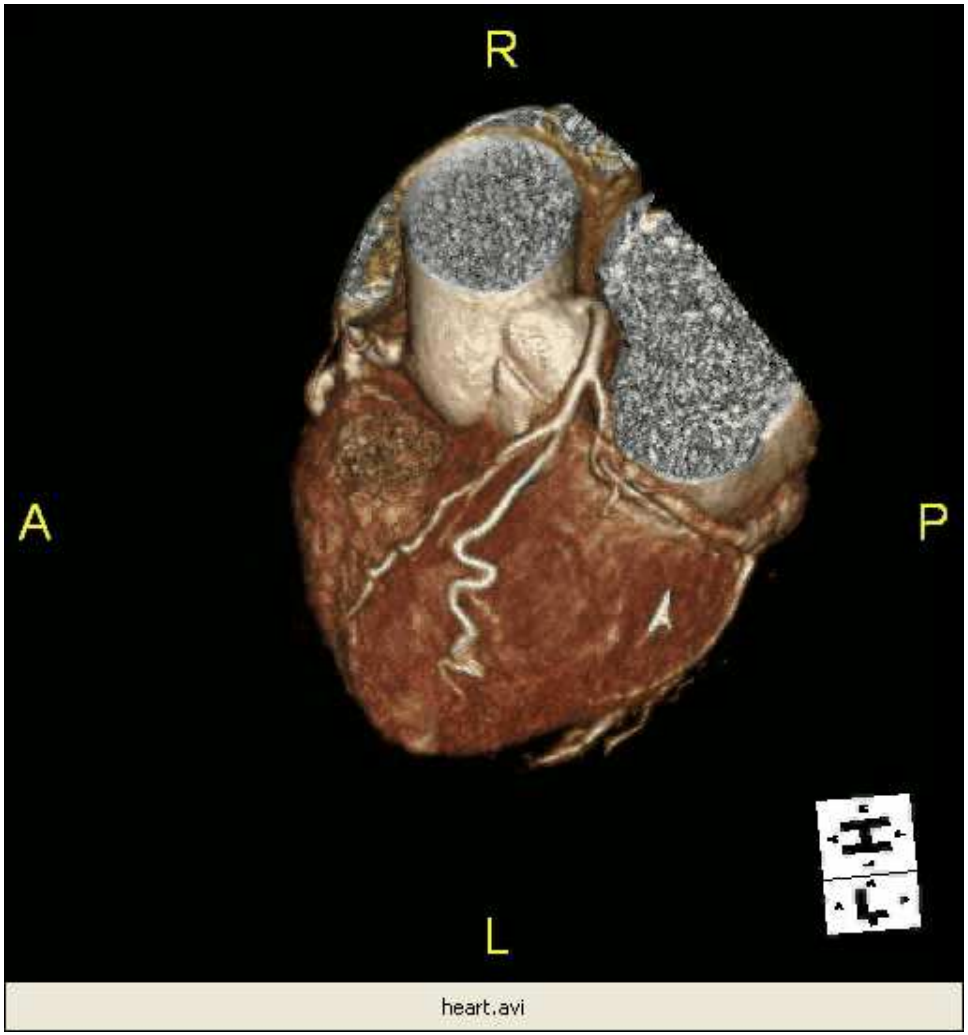

Courtesy Tom Kraus
Kettering Medical Cente

Pretty Pictures Are Nice…

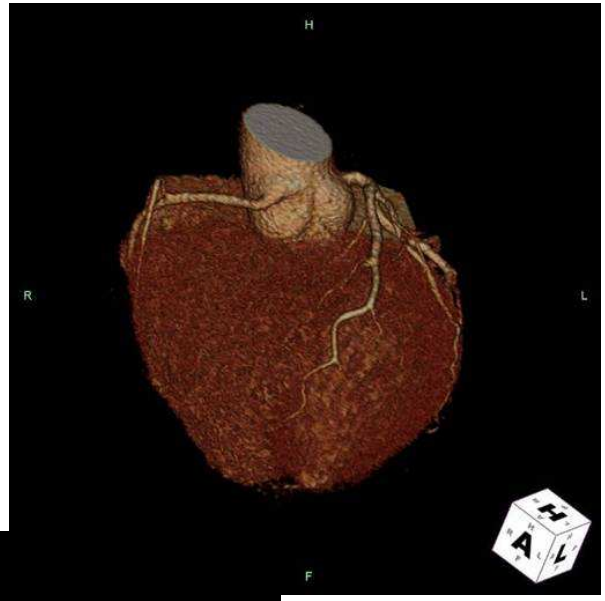

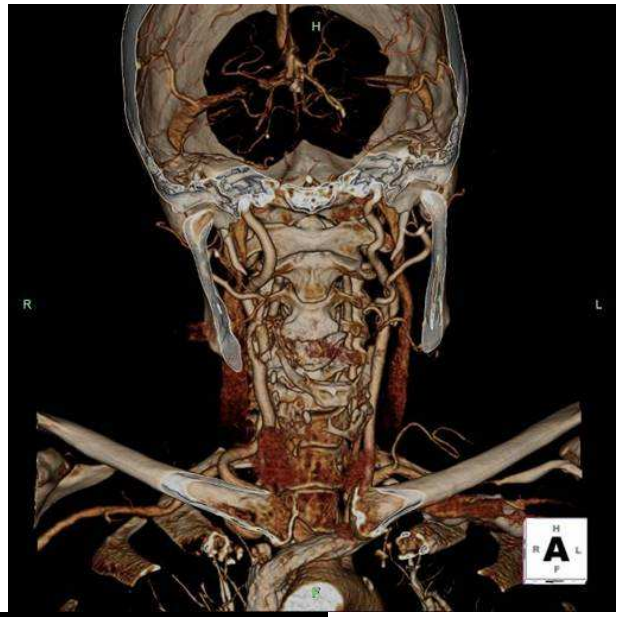

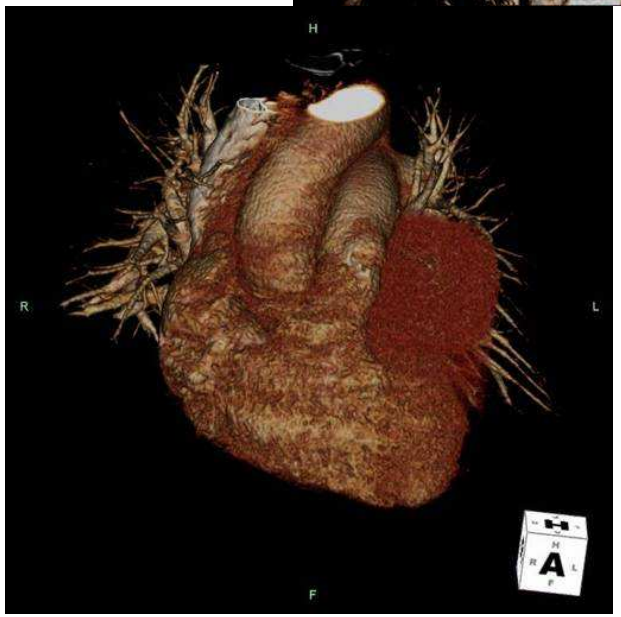

Courtesy Tom Kracus
Kettering Medical Center

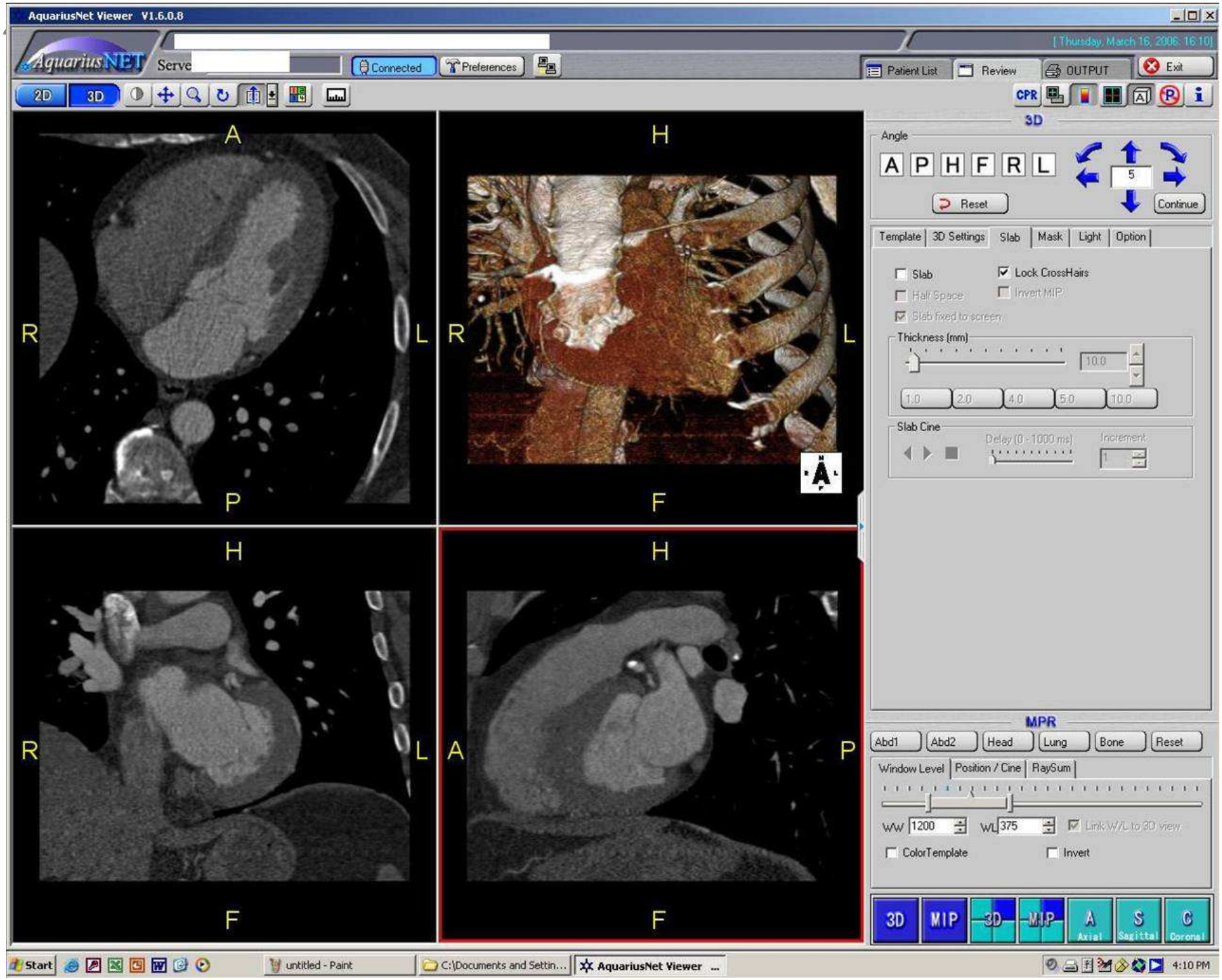
AquariusNet Viewer V1.6.0.8
AquariusNET
Serve
Connected
Preferences
[Thursday, March 16, 2006, 16:10]
Patient List
Review
OUTPUT
Exit
2D
3D
CPR
A
R
L
P
H
F
3D
Angle
A P H F R L
5
Reset
Continue
Template
3D Settings
Slab
Mask
Light
Option
Slab
Lock CrossHairs
Half Space
Invert MIP
Slab fixed to screen
Thickness (mm)
10.0
1.0
2.0
4.0
5.0
10.0
Slab Cine
Delay (0 - 1000 ms)
Increment
1
MPR
Abd1
Abd2
Head
Lung
Bone
Reset
Window Level
Position / Cine
RaySum
WW 1200
WL 375
Link W/L to 3D view
ColorTemplate
Invert
3D
MIP
3D
MIP
A
Axial
S
Sagittal
C
Coronal
Start
untitled - Paint
C:\Documents and Settin...
AquariusNet Viewer ...
4:10 PM

Basic Protocol for 64 slice Coronary MDCT

- Heart rate <65
  - Administer atenolol or metoprolol po
  - Administer metoprolol IV prn (5-10mg)
- Nitroglycerin just before injection
- Test bolus (10cc) – track intensity in aorta to determine optimal time for imaging (about 20 seconds)
- Bolus contrast (70-120cc) with breath hold coordinated during image acquisition

Sequential vs Helical CT scan

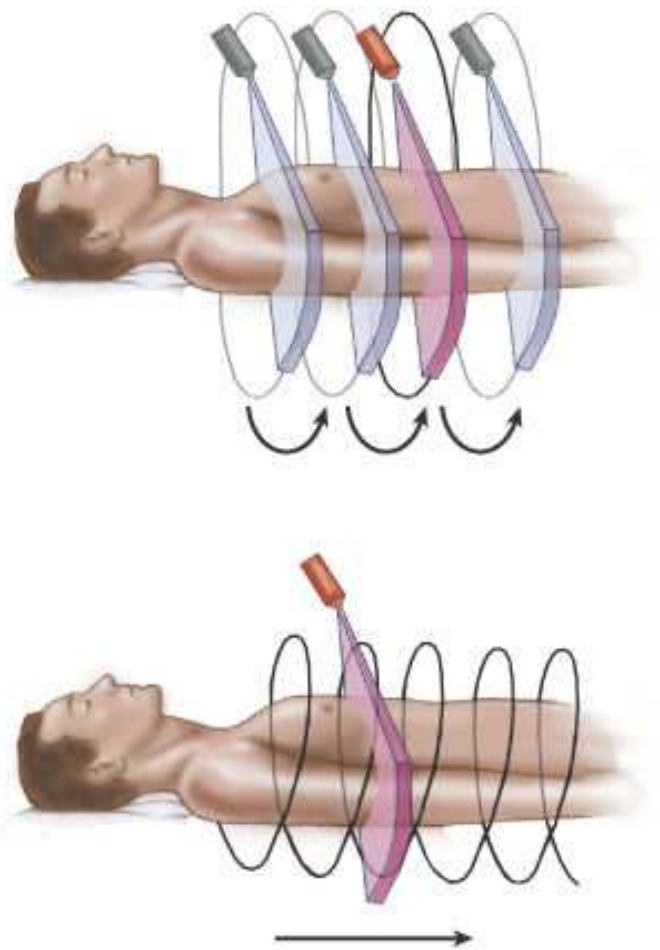

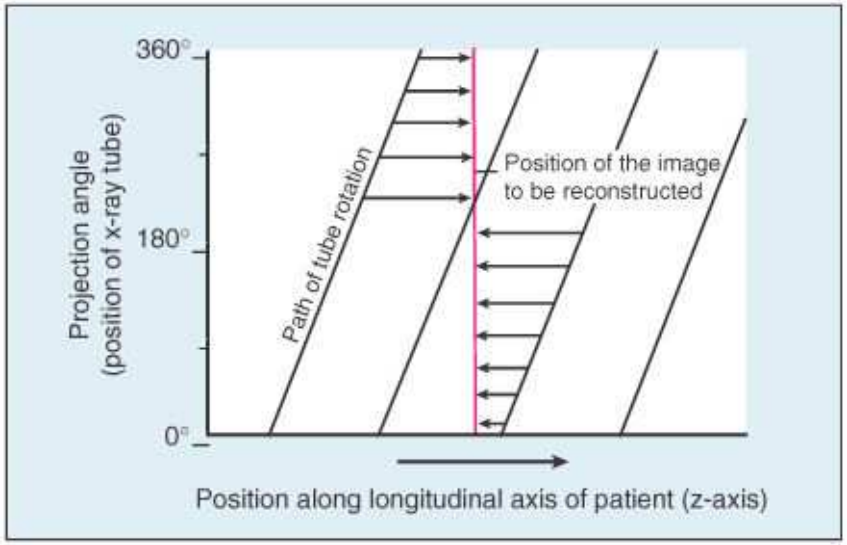

Braunwald 7th ed

Resolution

- Current scanners can acquire a slice in about 0.3 seconds
- Spatial resolution among scanners varies
  - 0.4mm x 0.4mm x 0.4mm for example

Planar vs Tomographic images

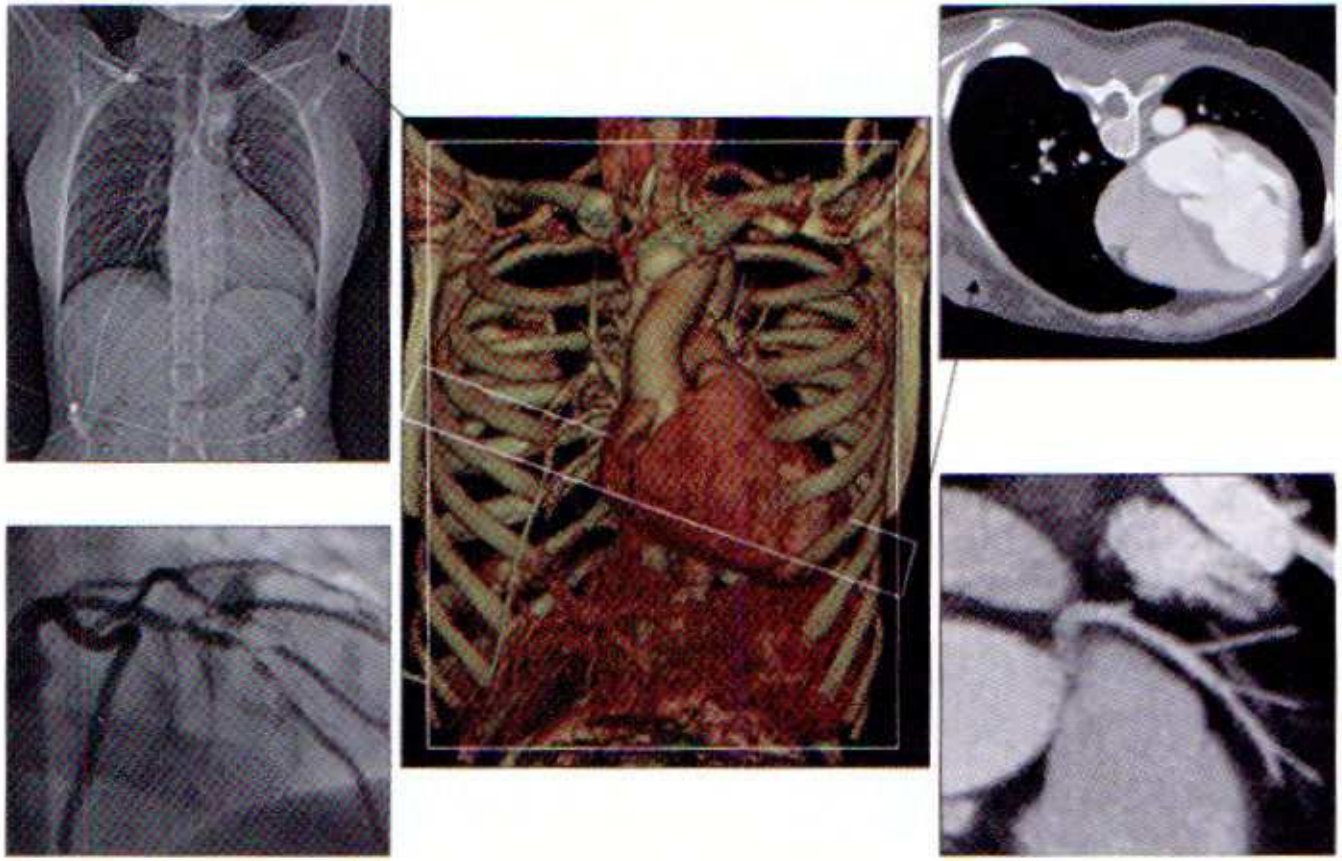

Figure 1 Planar versus tomographic imaging

Schoenhagen

Image Acquisition Angiography vs CTA

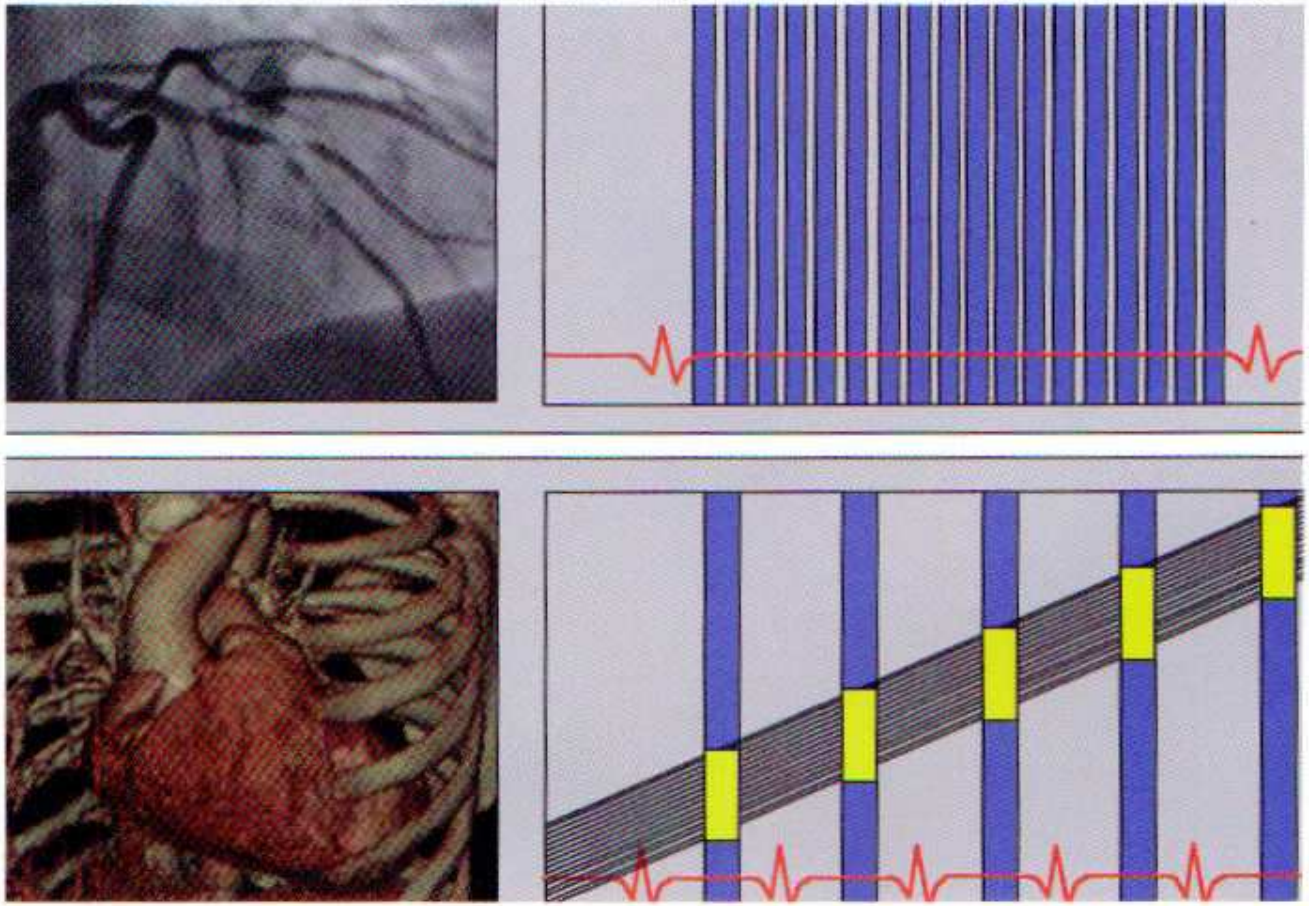

Figure 2 Image acquisition time

Schoenhagen

EKG gating

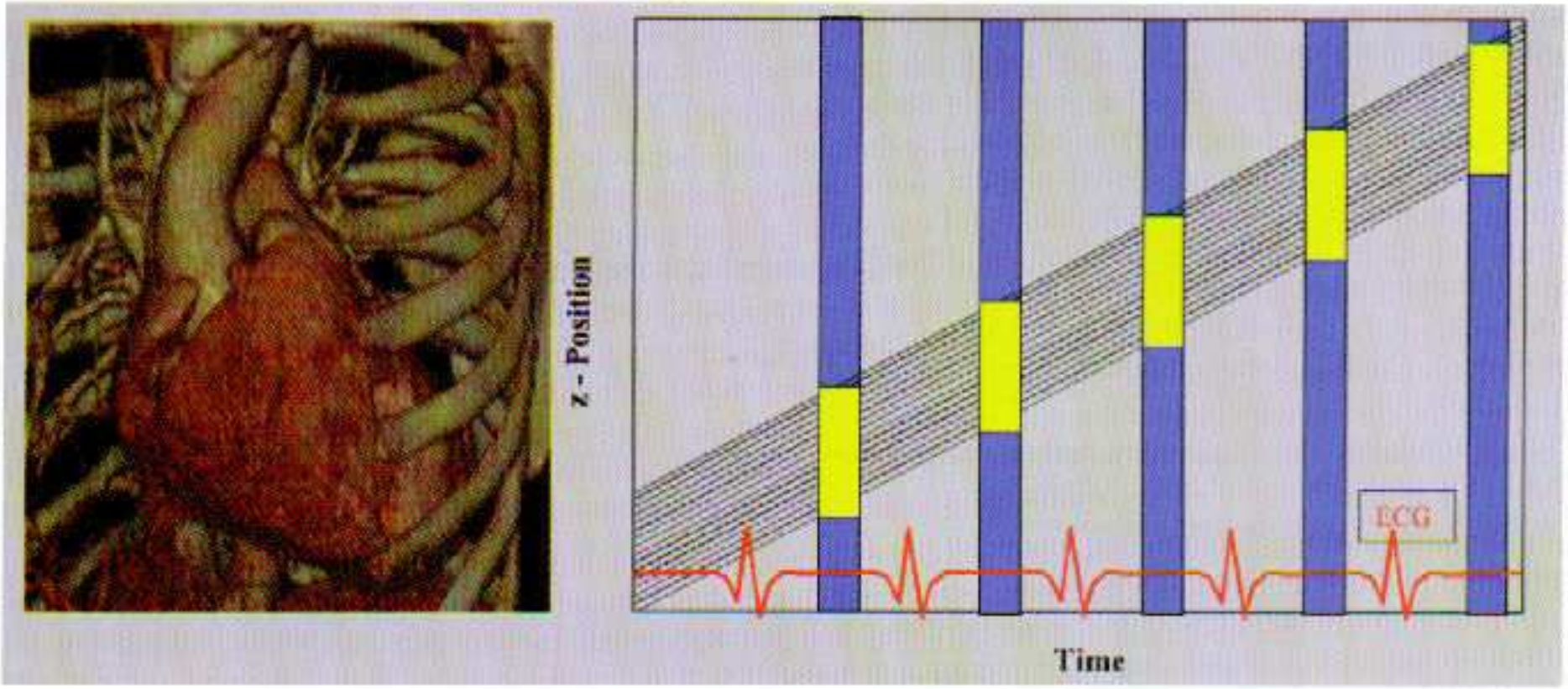

Figure 9 Volume coverage

Schoenhagen

Data sets at different points along the R-R interval can give different results

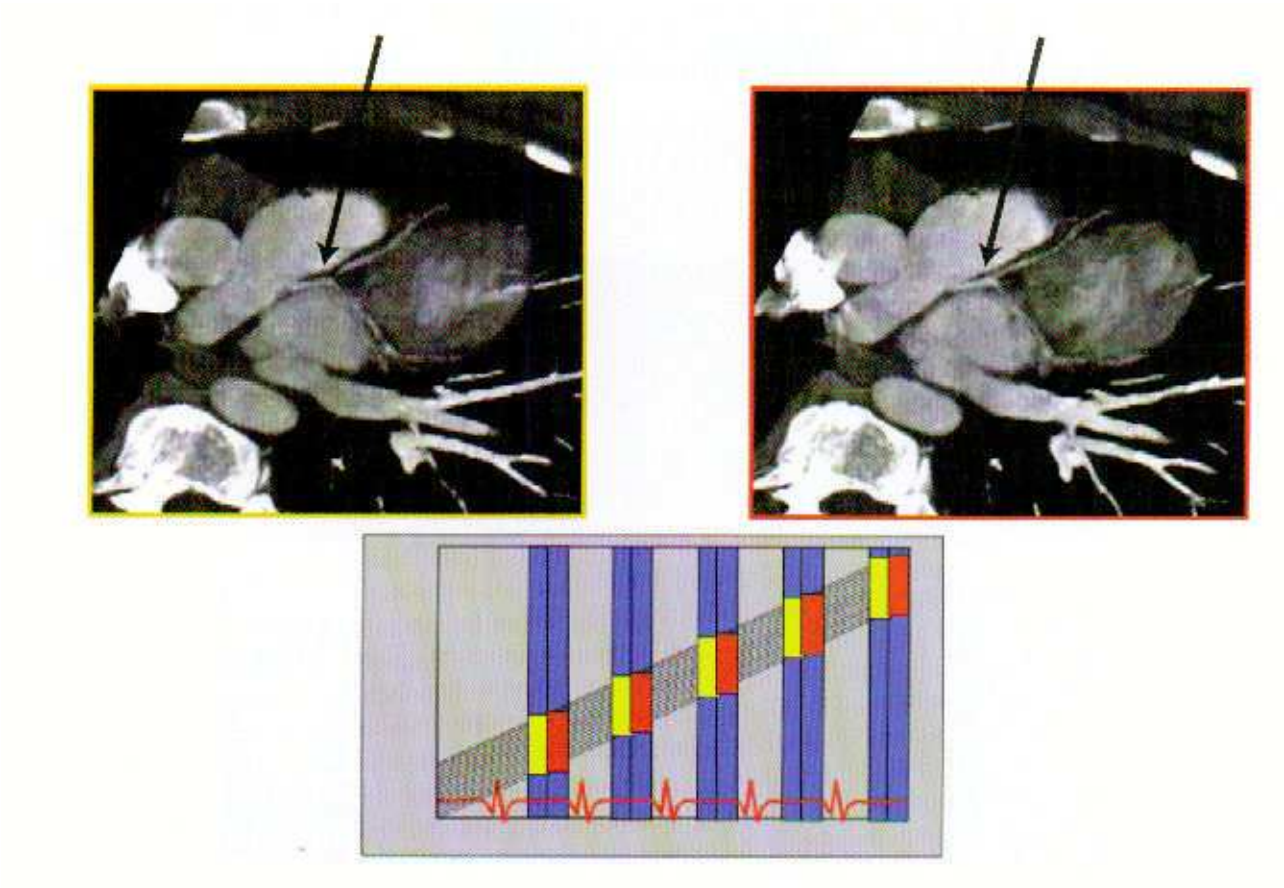

Figure 10 Reconstruction window: image quality

Schoenhagen

Vessel motion during cardiac Cycle

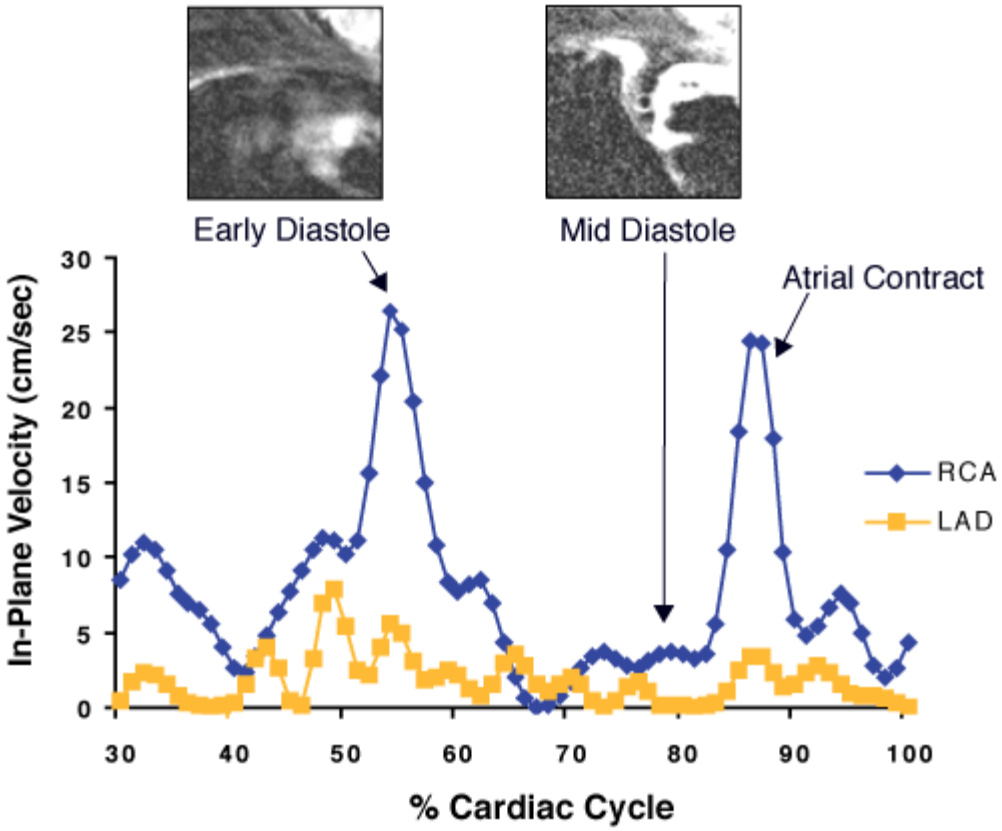

Arrhythmia distorts image

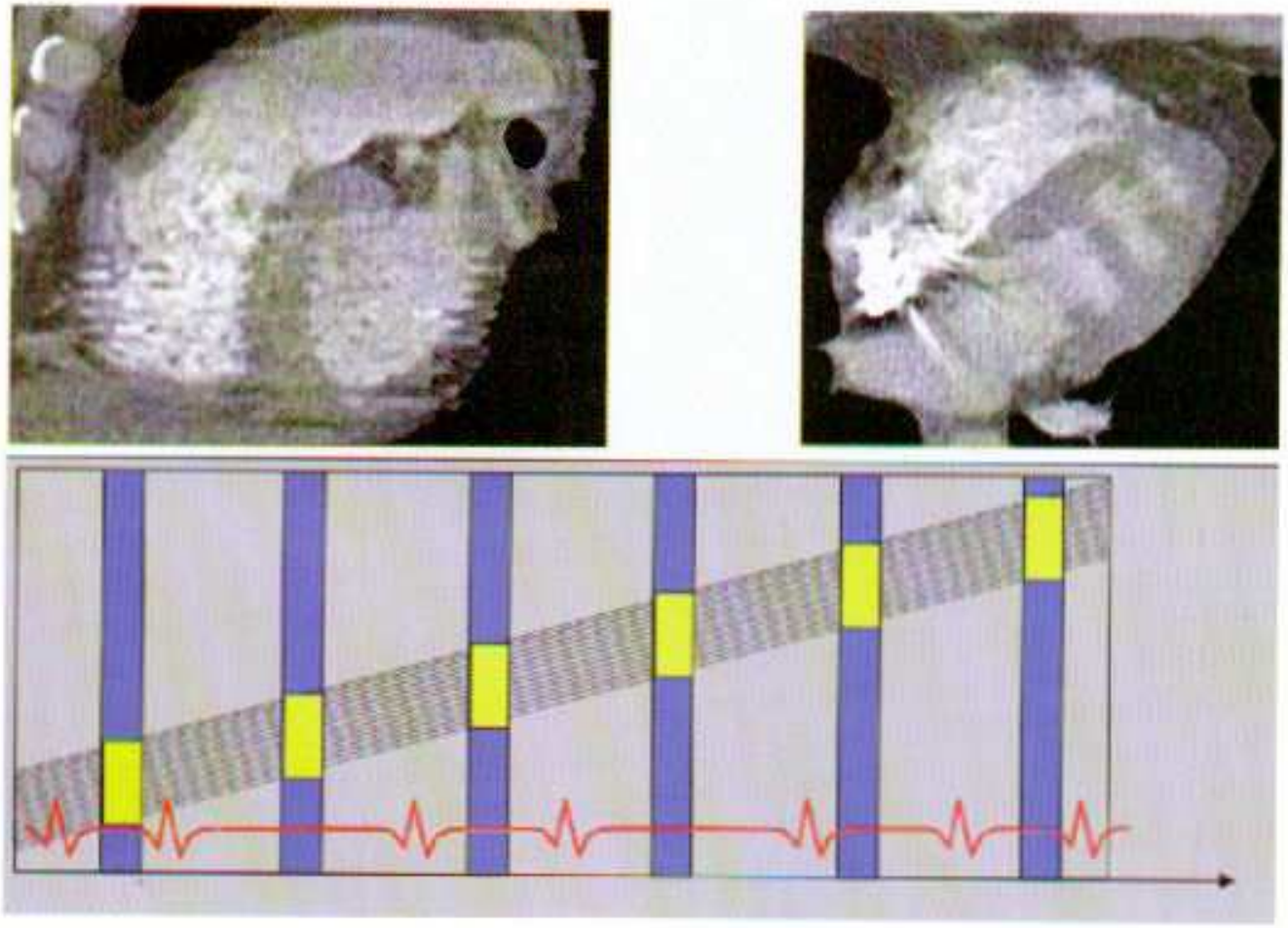

Figure 29 Arrhythmia artifact (1)

Schoenhagen

Image Reconstruction Techniques

- MPR – Multiplaner Reconstruction
- MIP – Maximal Intensity Projection
- CPR – Curved Planar Reformation
- VR – Volume Rendering

Axial vs MPR images

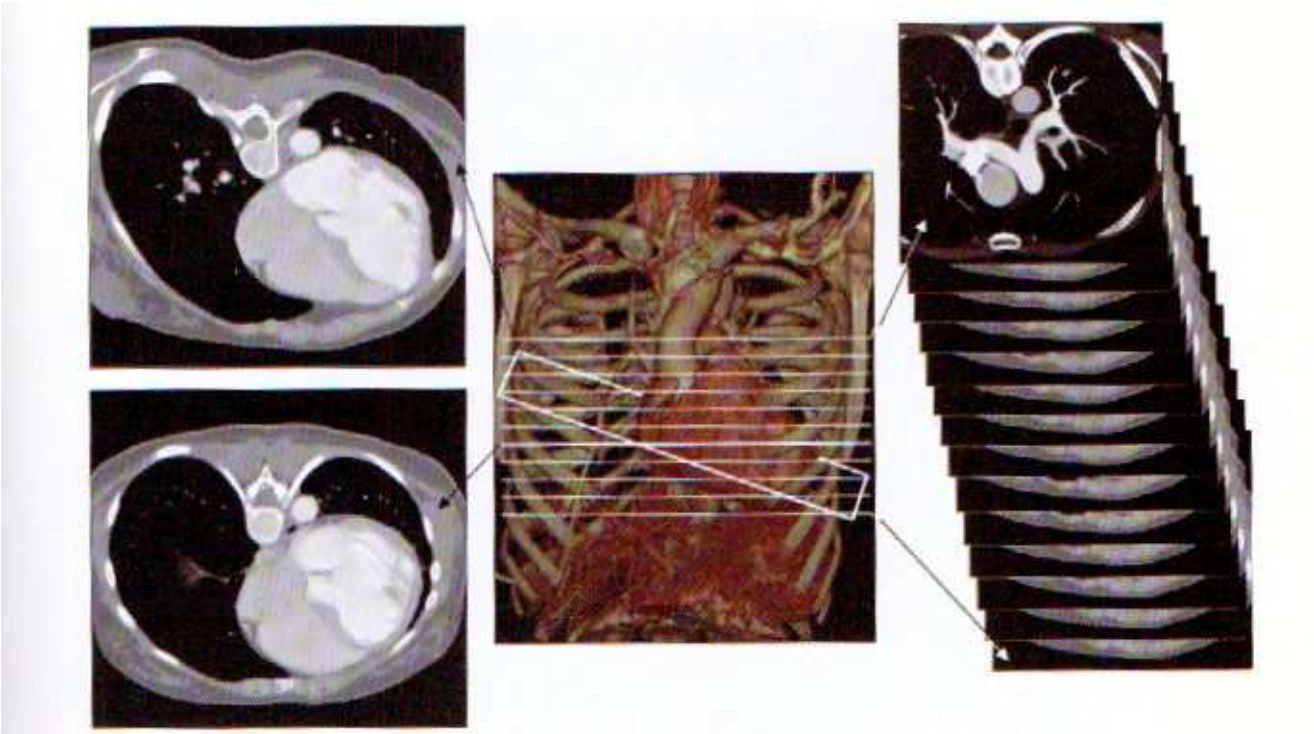

Figure 18 Axial and oblique images

Schoenhagen

Maximal Intensity Projection

- Thicker slice than MPR (10mm)
- Takes the brightest spot (voxel) within the slice and emphasizes that point
- Good for general visualization and layout of vessel

Curved Plane Reformation

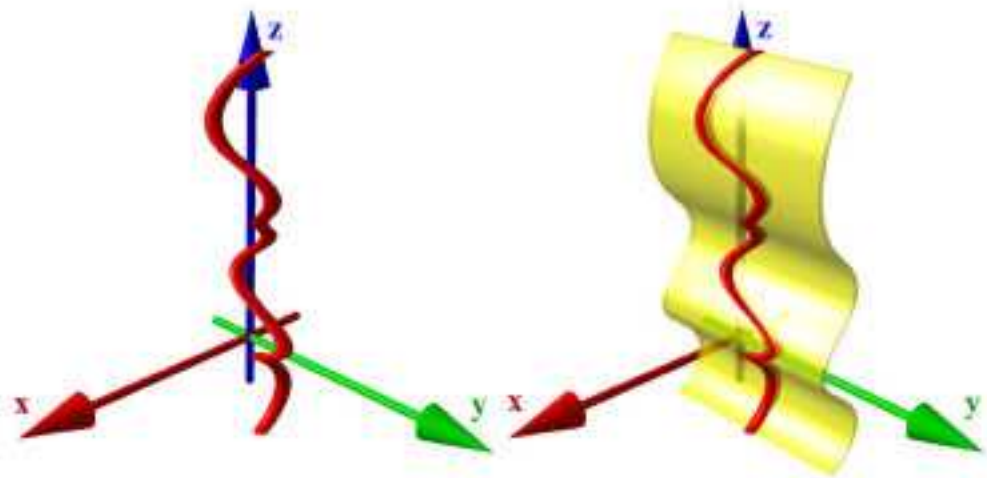

Figure 1: Principle of the CPR visualization

Axial Endovascular VR of Aorta

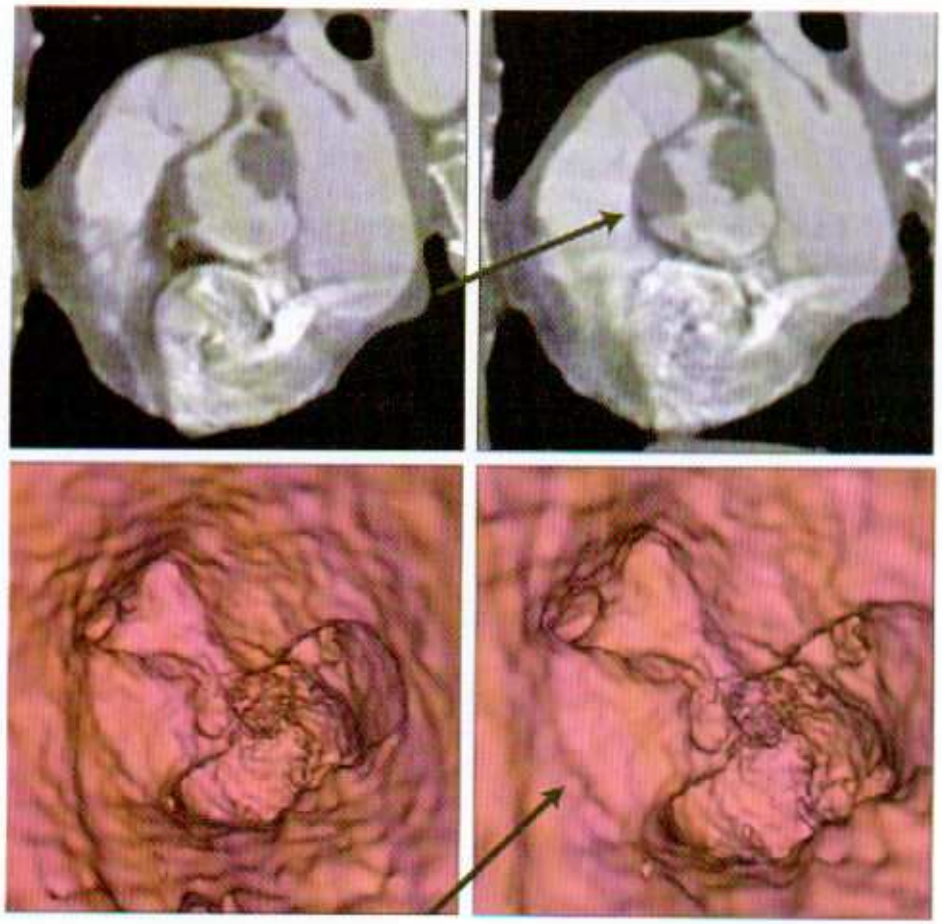

Figure 27 Perspective volume rendering

Schoenhagen

Radiation dose from various sources

Effective dose of selected radiologic examinations

Examination	Effective dose (mSv)
Head CT	1–2
Chest CT	5–7
Abdomen and pelvis CT	8–11
Selective coronary angiogram	3–5
PA and lateral chest X-ray	0.04–0.06
Average annual background radiation in the United States	3.6

Abbreviations: CT, computed tomography; PA, posteroanterior.

Data from Morin RL, Gerber TC, McCollough CH. Radiation dose in computed tomography of the heart. Circulation 2003;107:917–22; with permission.

Cardiology Clinics 2003

How good is 64 slice coronary MDCT?

TABLE 2. Diagnostic Performance and Predictive Value of 64-Slice CT Coronary Angiography for the Detection of ≥50% Stenoses on QCA

	n	Sensitivity, %	Specificity, %	PPV, %	NPV, %	+LR	−LR
Segment-based analysis							
All segments	725	99 (94–98)	95 (93–96)	76 (67–89)	100 (99–100)	20.81	0.01
Proximal segments	204	100 (89–100)	97 (93–98)	83 (67–97)	100 (97–100)	29.00	0.00
Mid segments	142	97 (83–99)	94 (88–97)	81 (63–96)	99 (94–99)	15.47	0.04
Distal segments	121	100 (68–100)	97 (92–99)	73 (39–98)	100 (96–100)	37.67	0.00
Side branches	258	100 (87–100)	94 (90–96)	65 (48–85)	100 (98–100)	16.57	0.00
LM	51	100 (21–100)	100 (93–100)	100 (92–100)	100 (2–100)	∞	0.00
LAD	230	97 (85–100)	92 (88–95)	69 (53–86)	99 (96–99)	12.68	0.03
LCx	235	100 (88–100)	97 (94–99)	83 (66–97)	100 (98–100)	34.33	0.00
RCA	209	100 (89–100)	95 (91–97)	77 (60–95)	100 (97–100)	19.89	0.00
Patient-based analysis							
All segments	51	100 (91–100)	92 (67–99)	97 (86–99)	100 (73–100)	13.00	0.00

PPV indicates positive predictive value; NPV, negative predictive value; +LR, positive likelihood ratio; −LR, negative likelihood ratio; LM, left main coronary artery; LCx, circumflex coronary artery; and RCA, right coronary artery. For segment-based analysis, analysis of 725 segments visualized on the conventional angiogram and classified according to a 17-segment modified AHA classification was performed. Segments were further classified on the basis of their location within the coronary tree (proximal, mid, or distal segments of the main coronary artery arteries or side branches) and their location within a single vessel (LM, LAD, LCx, or RCA). For patient-based analysis, analysis of 51 patients was performed. Values in parentheses represent 95% CIs.

Mollet et al., 2005

Orientation to Anatomy – Axial MPR

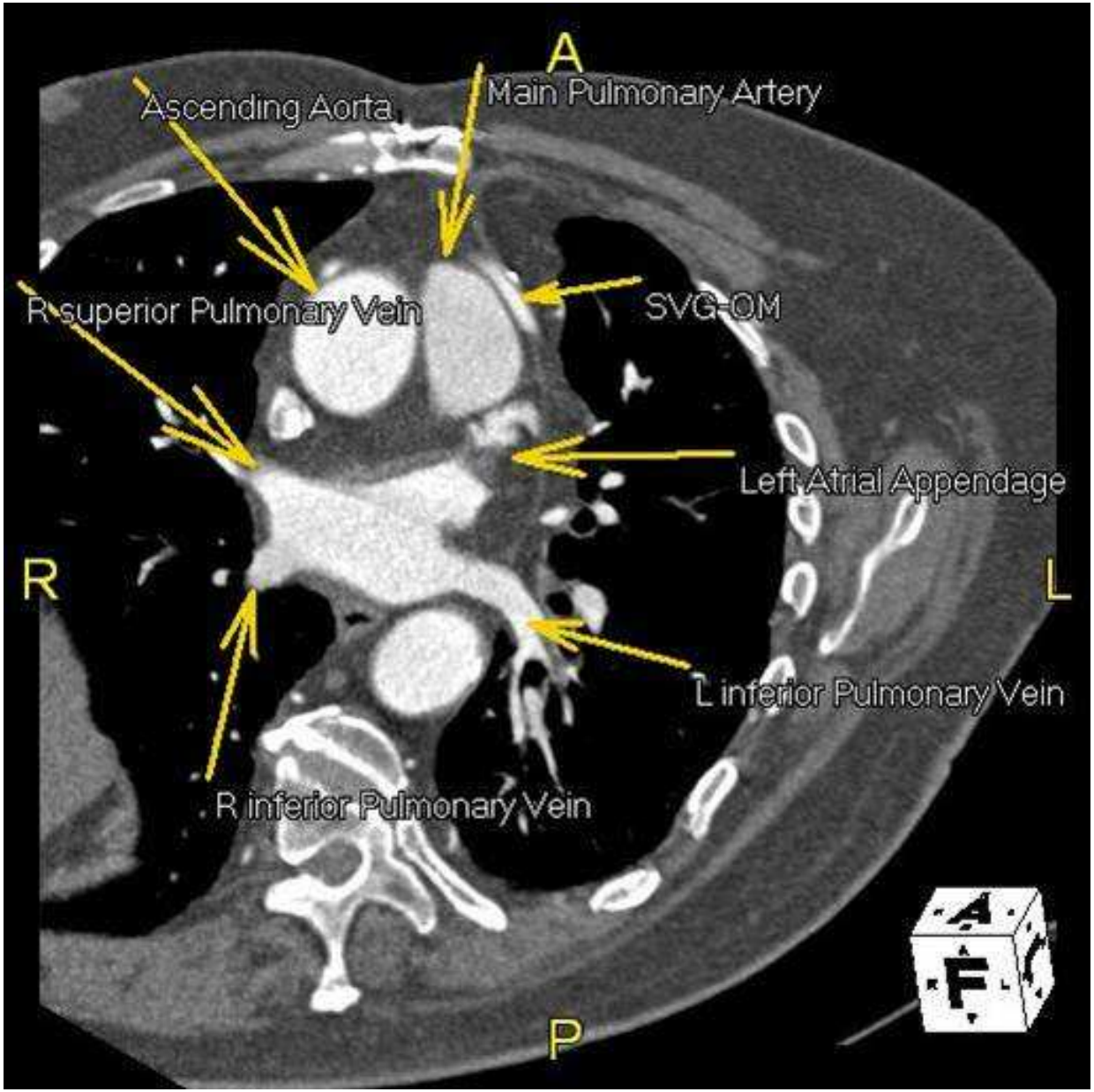

Parasternal Short Axis MPR

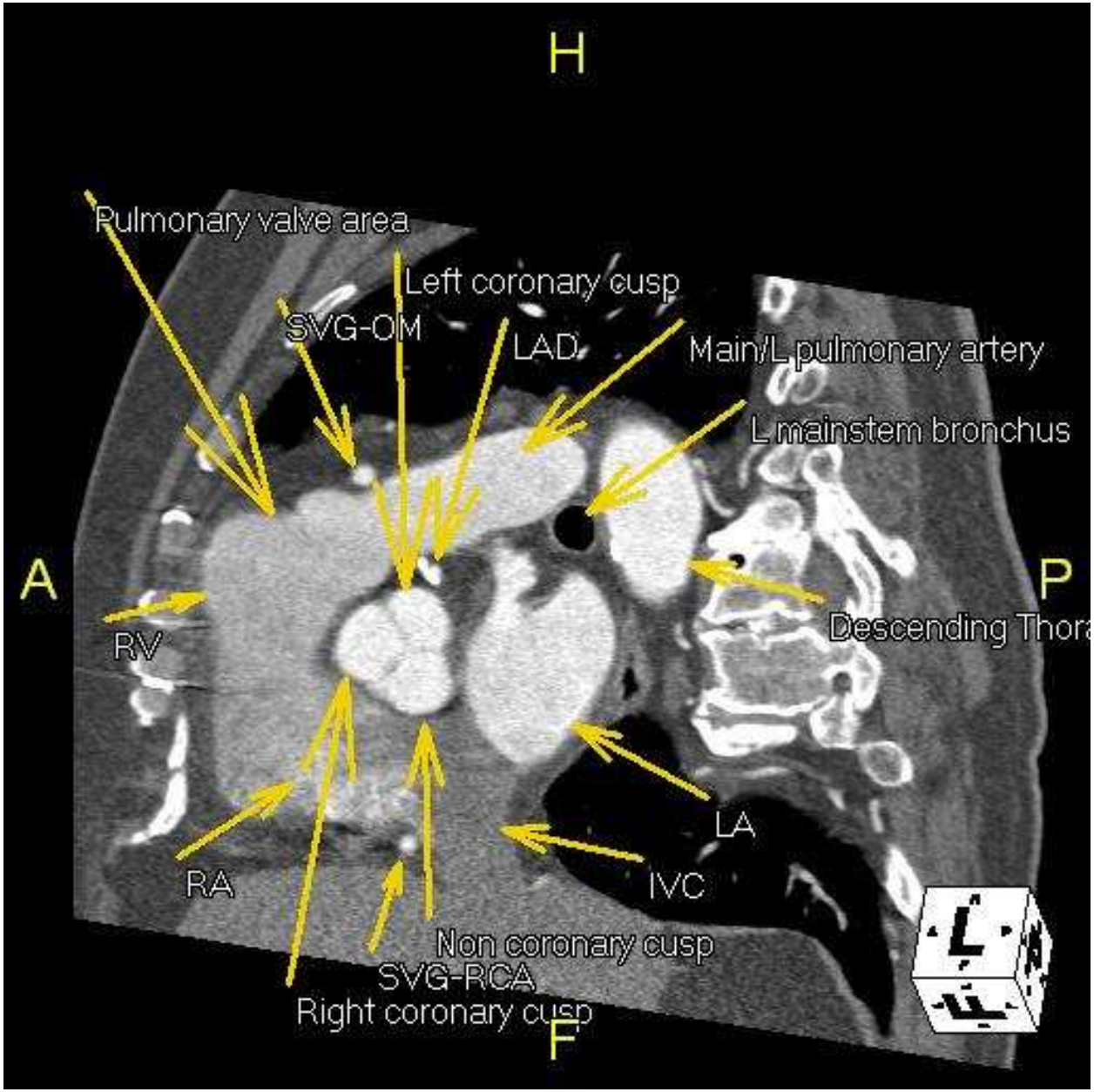

3 Chamber View MPR

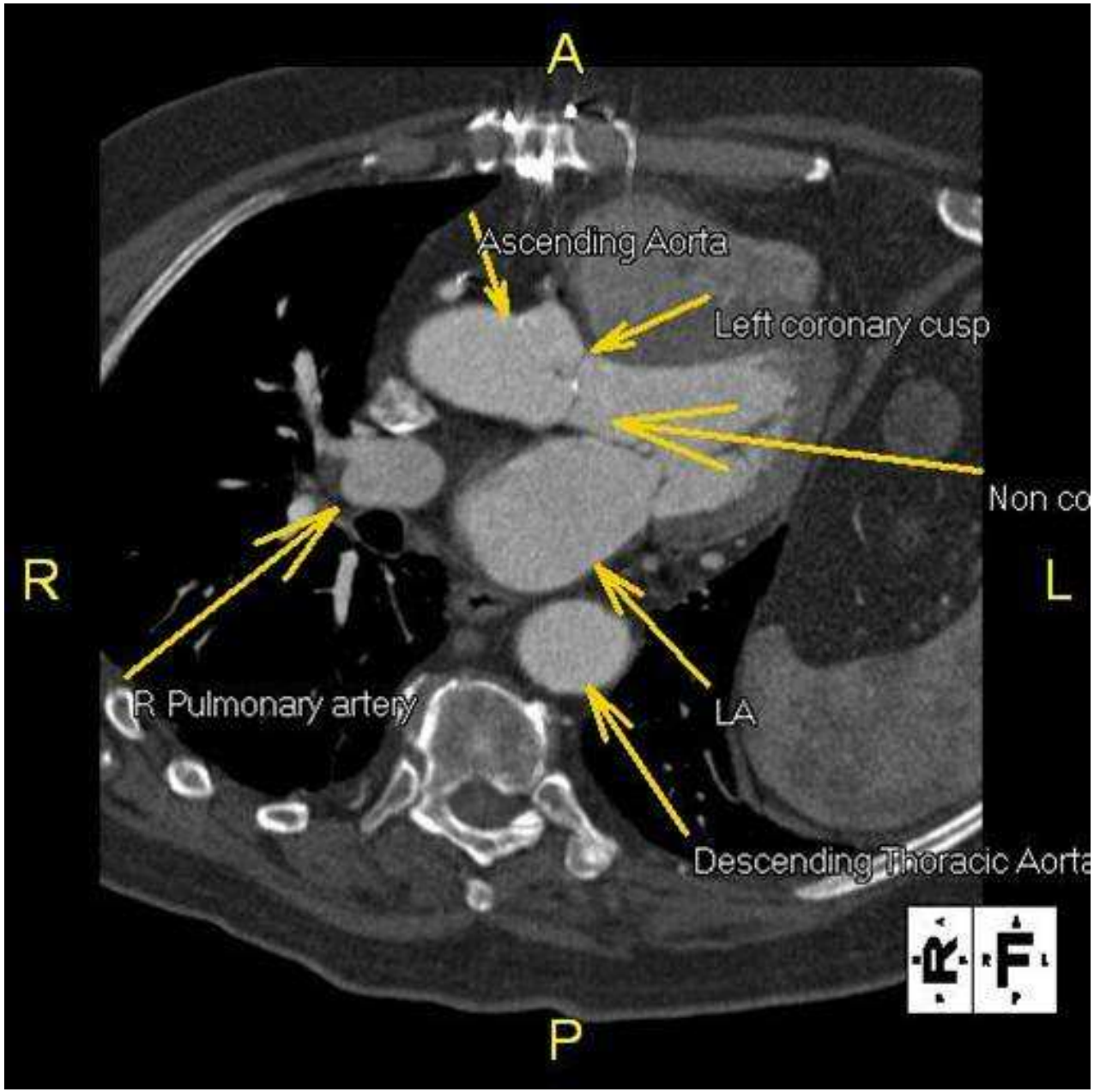

VR graft anatomy

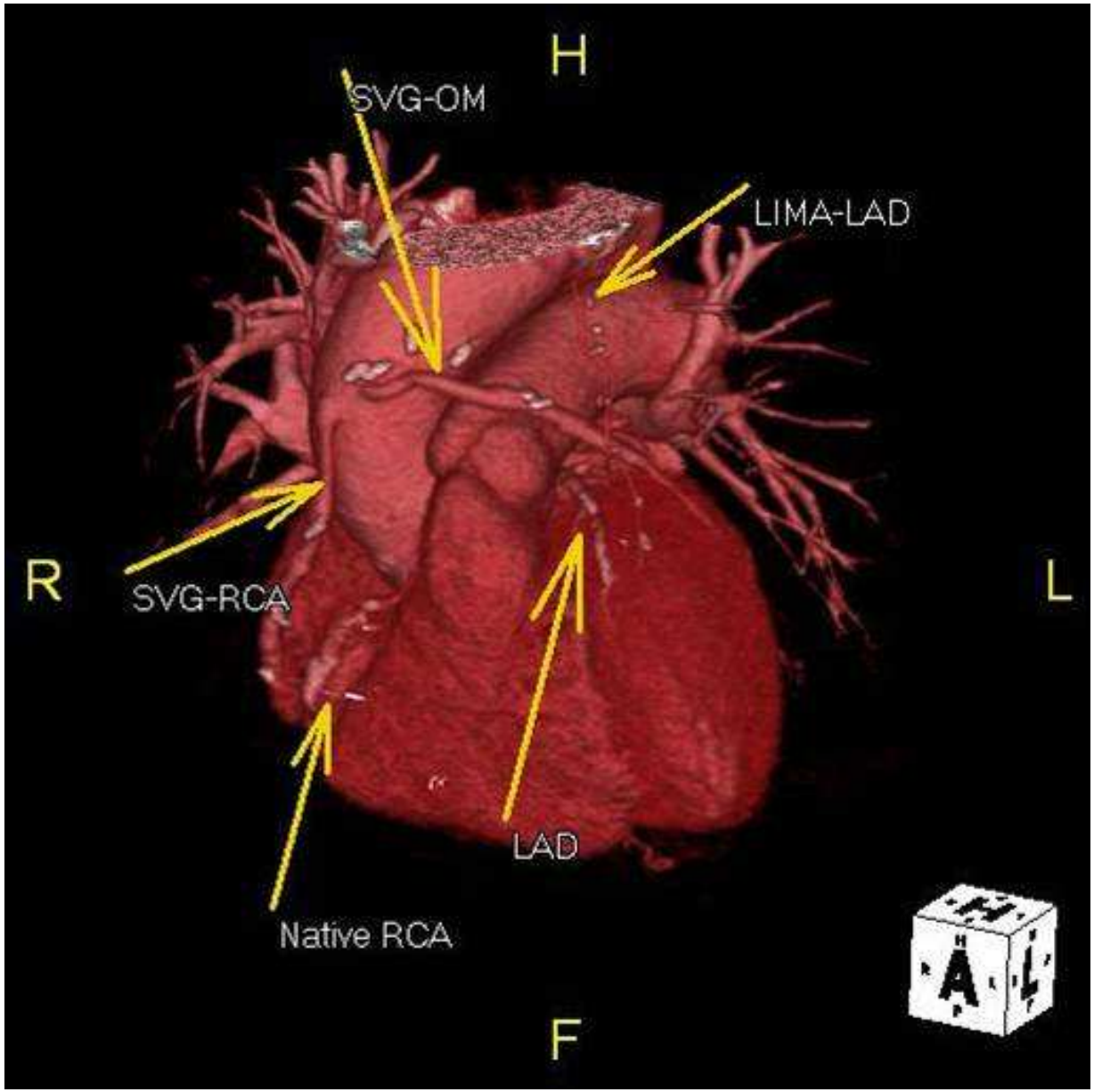

Axial images

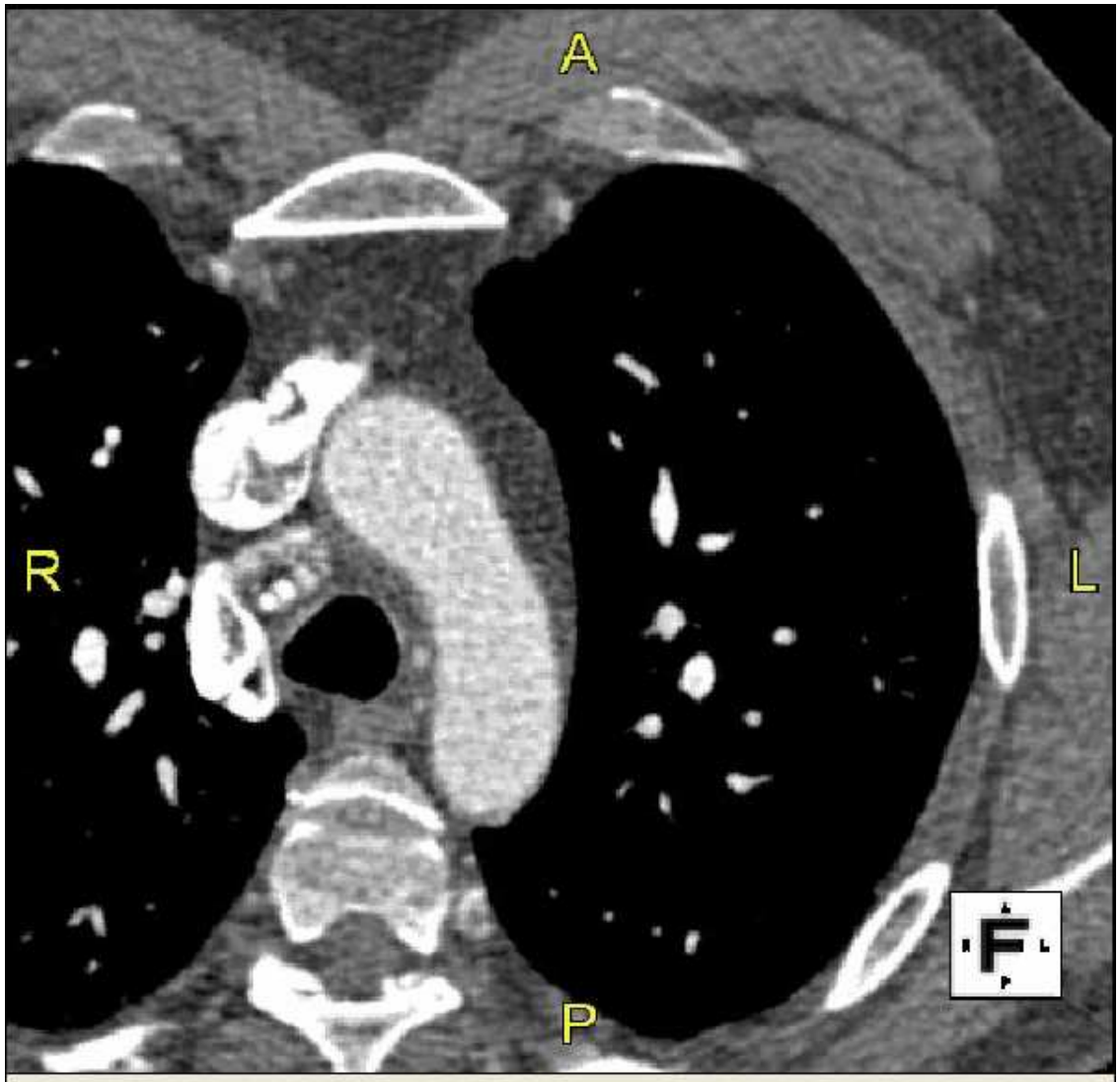

Good Axial slices raw (not MIP) (pt 2).avi

Examine axial images

Notice Calcium in LAD and D1

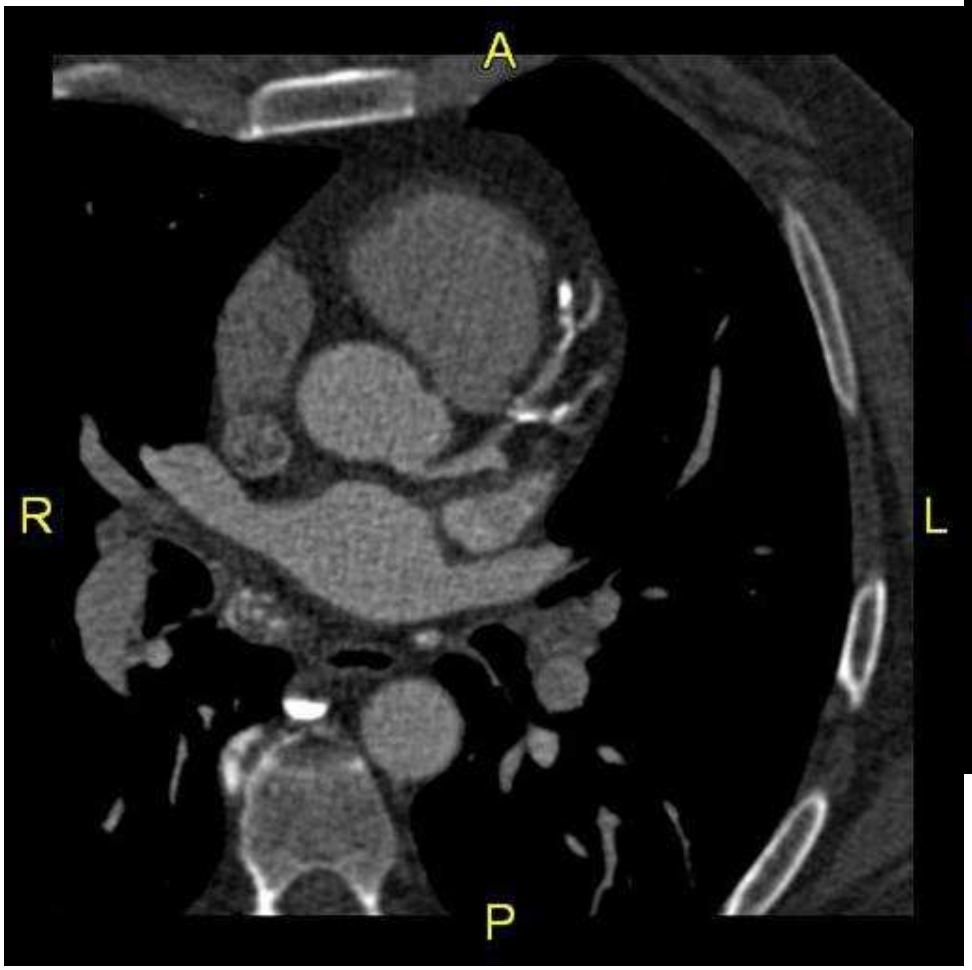

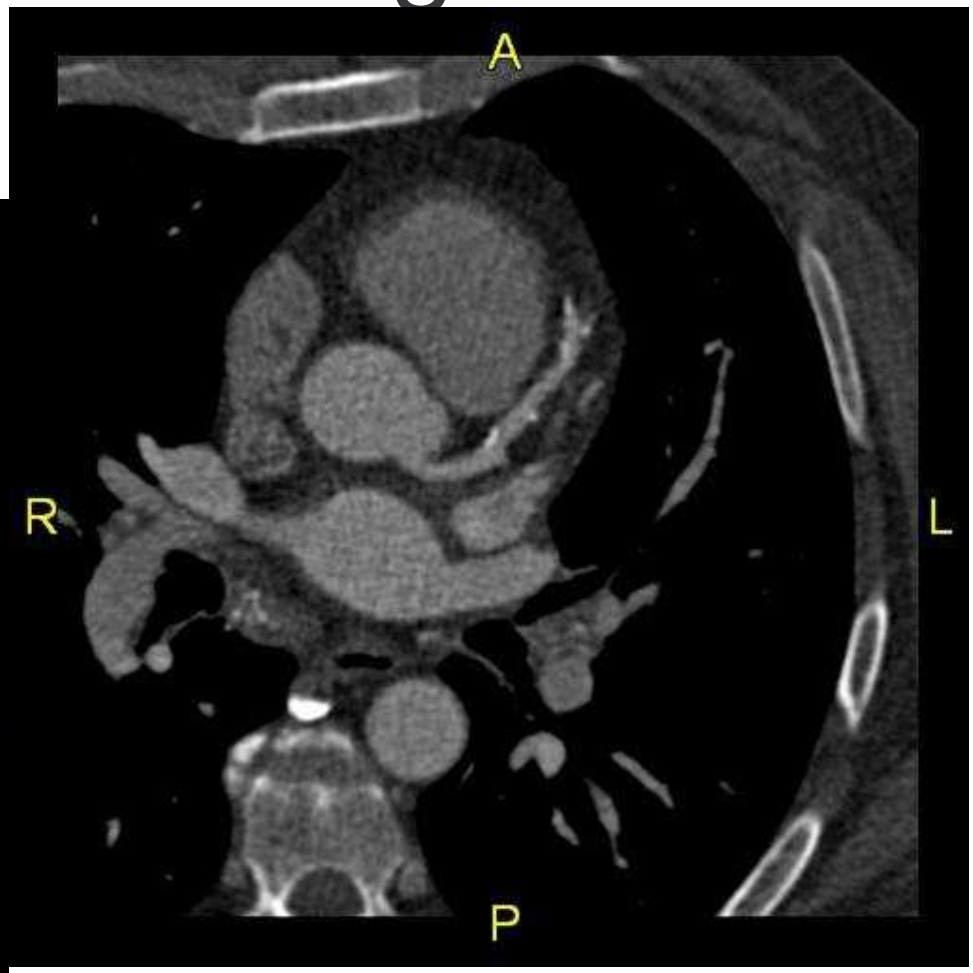

MIP View of Left Coronary

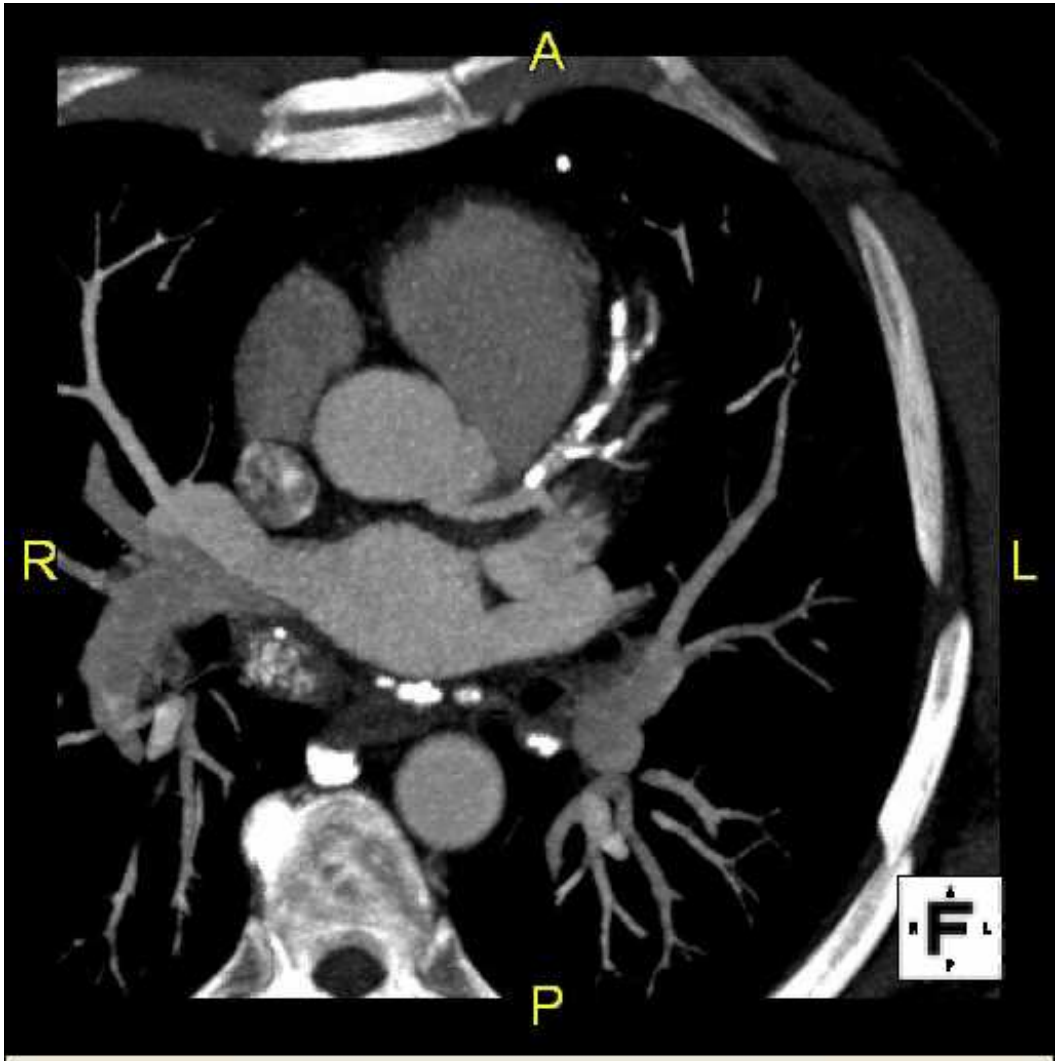

MIP rotation of left cor system with distal LAD lesion.avi

Notice misregistration of distal LAD raw Axial Slices

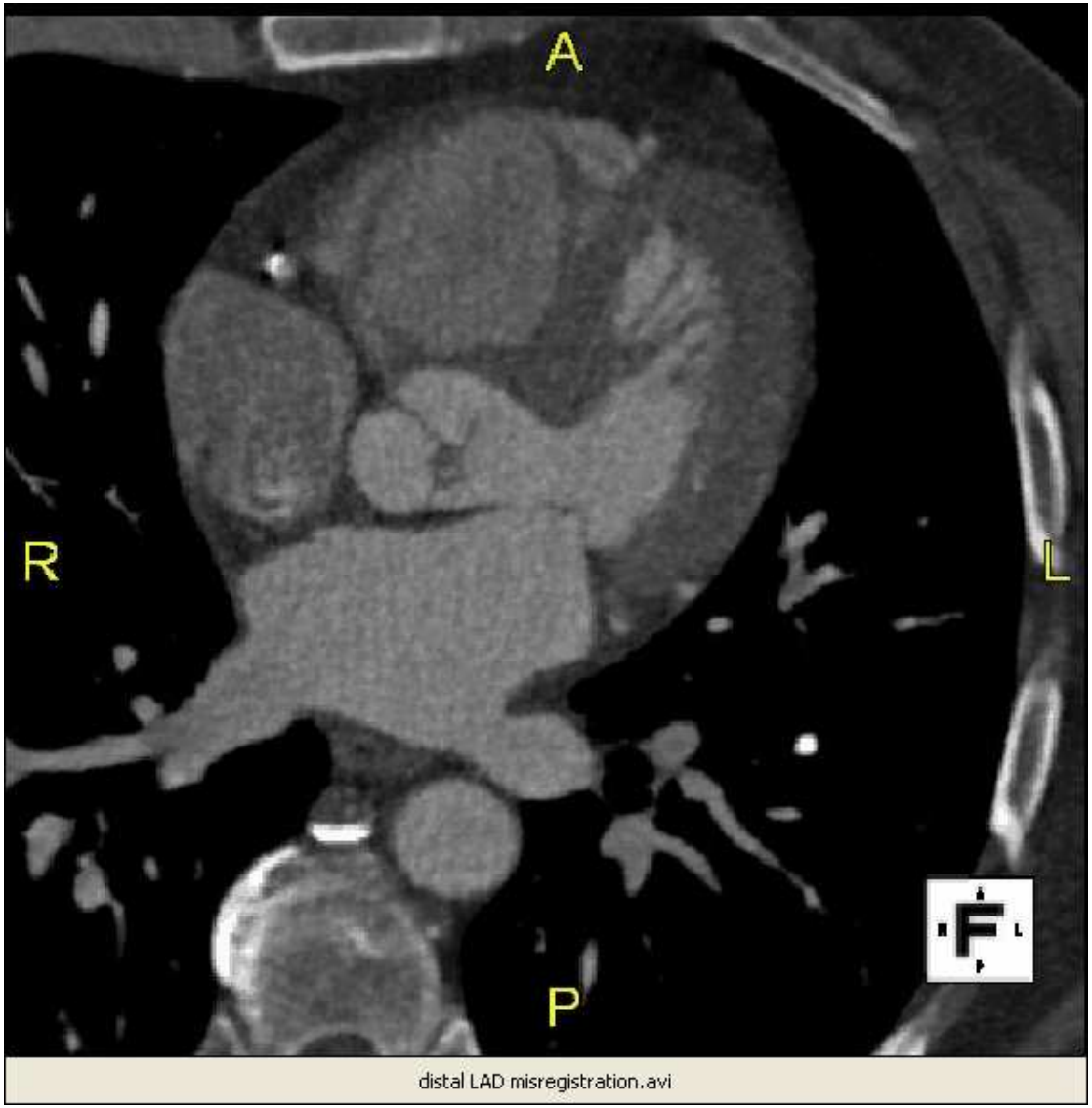

MIP View of RCA

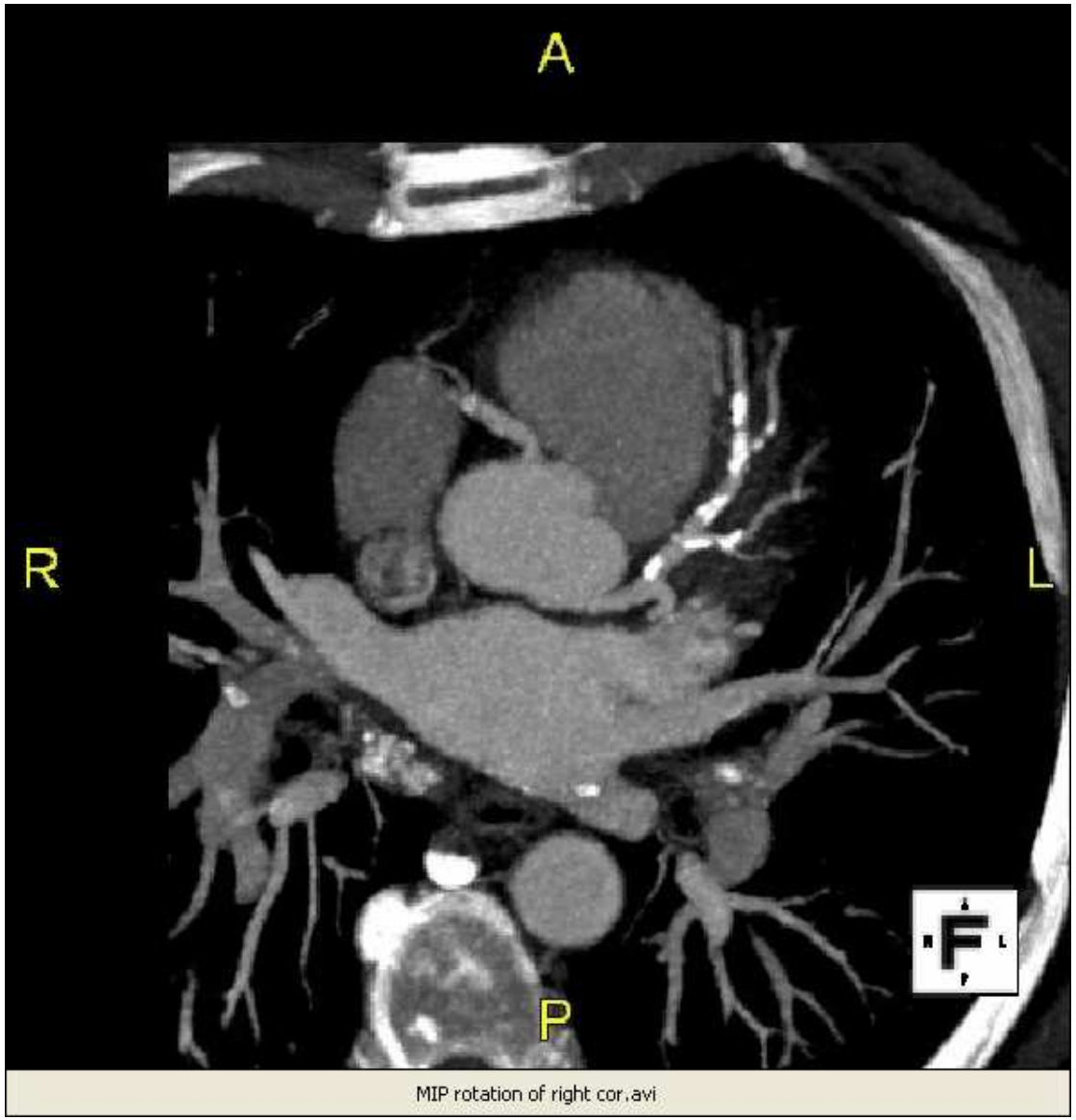

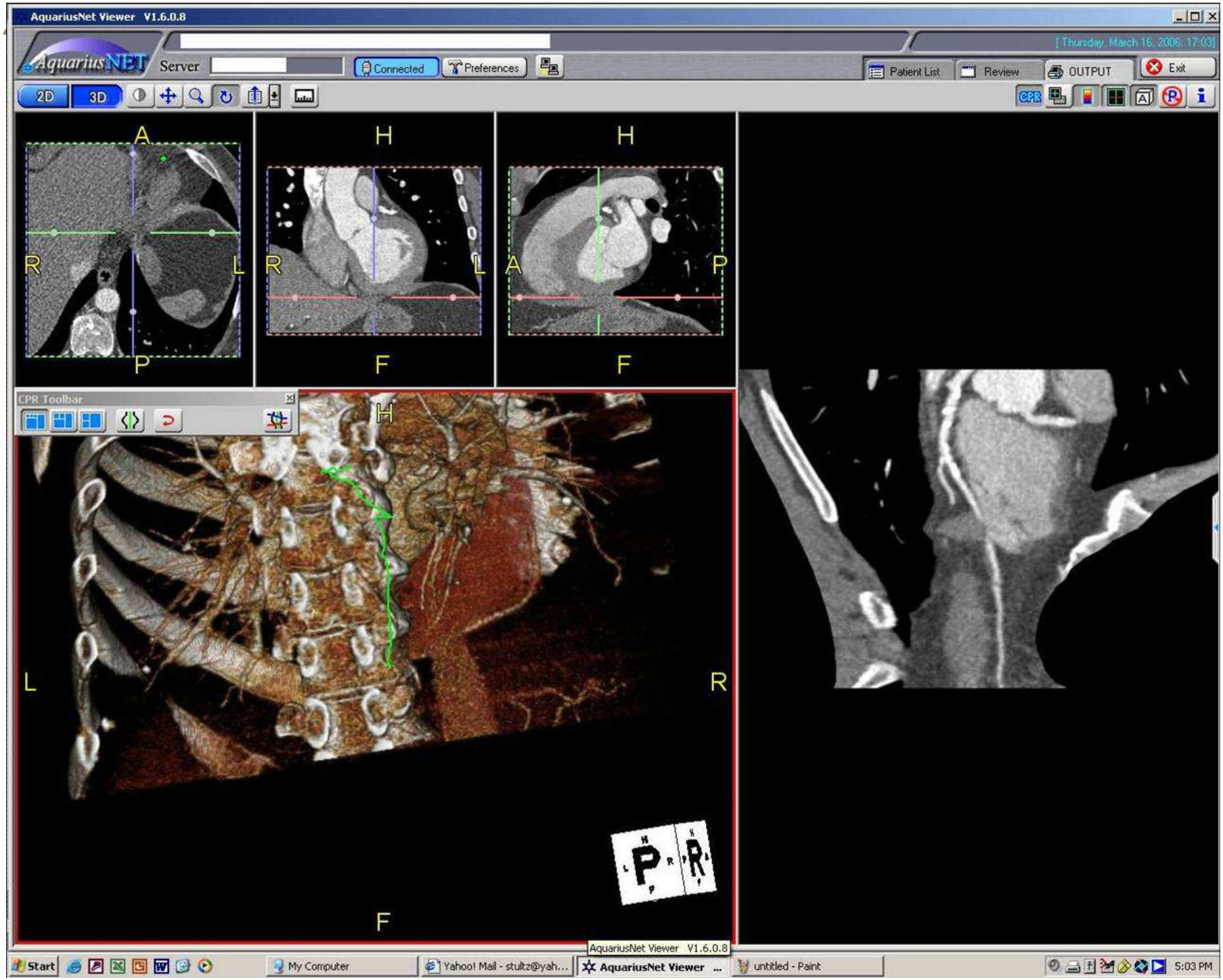
AquariusNet Viewer V1.6.0.8
AquariusNET
Server
Connected
Preferences
Patient List
Review
OUTPUT
Exit
2D
3D
A
R
L
P
H
F
CPR Toolbar
Start
My Computer
Yahoo! Mail - stultz@yah...
untitled - Paint
5:03 PM

CPR of LAD – artifact mid LAD

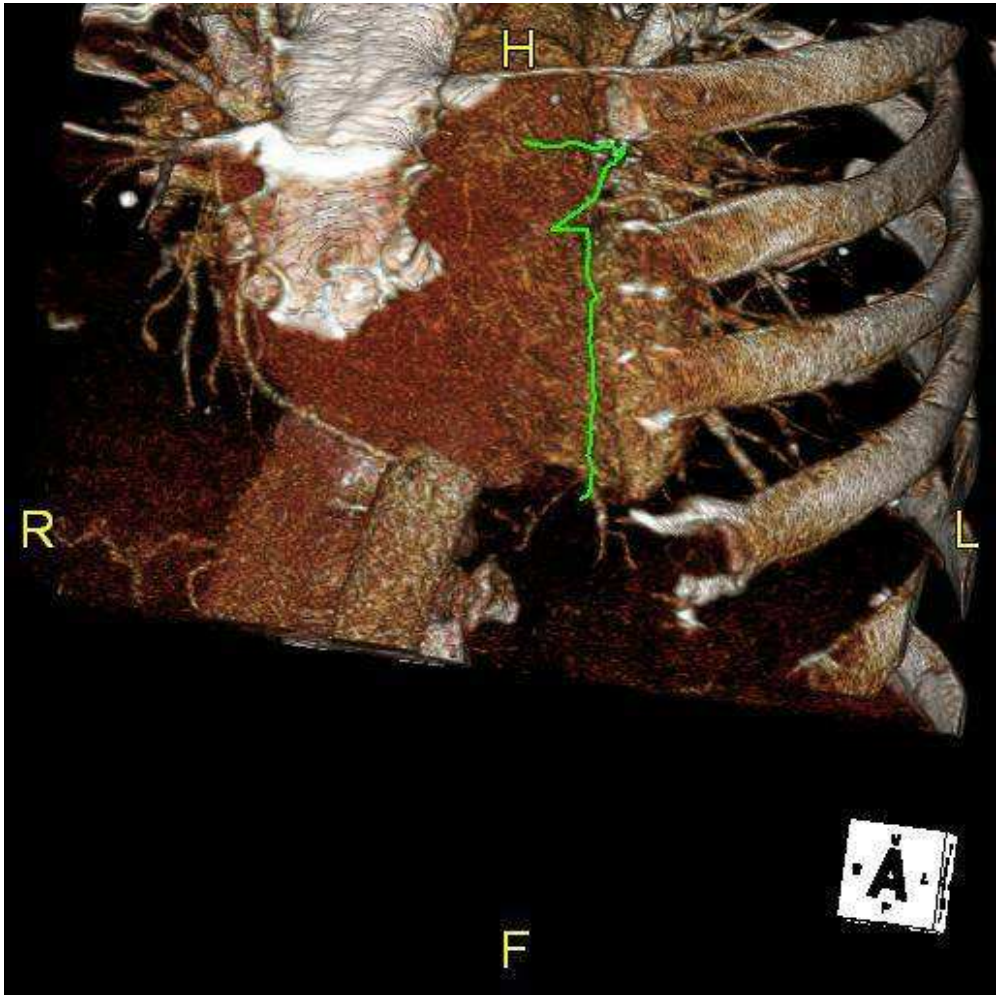

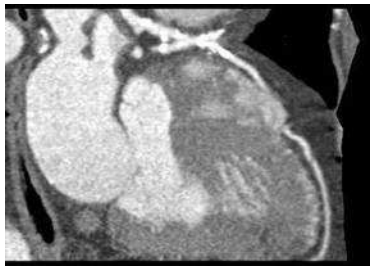

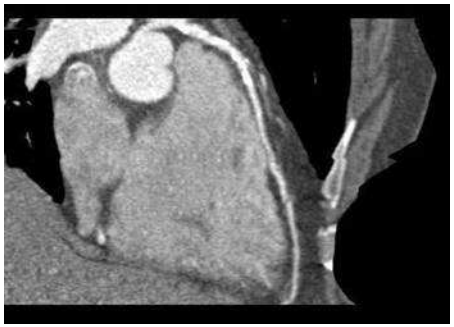

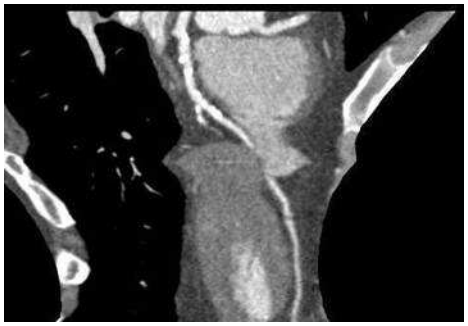

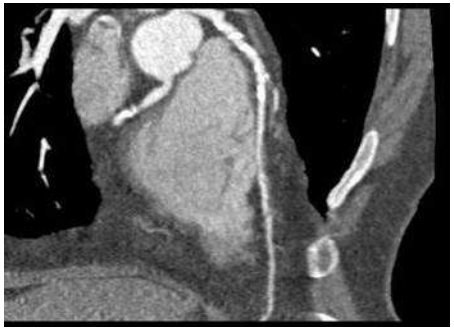

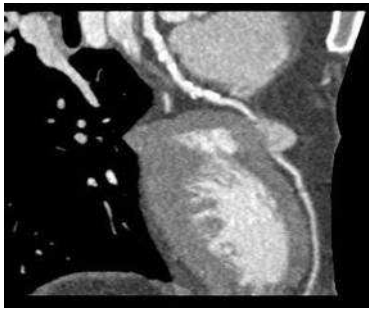

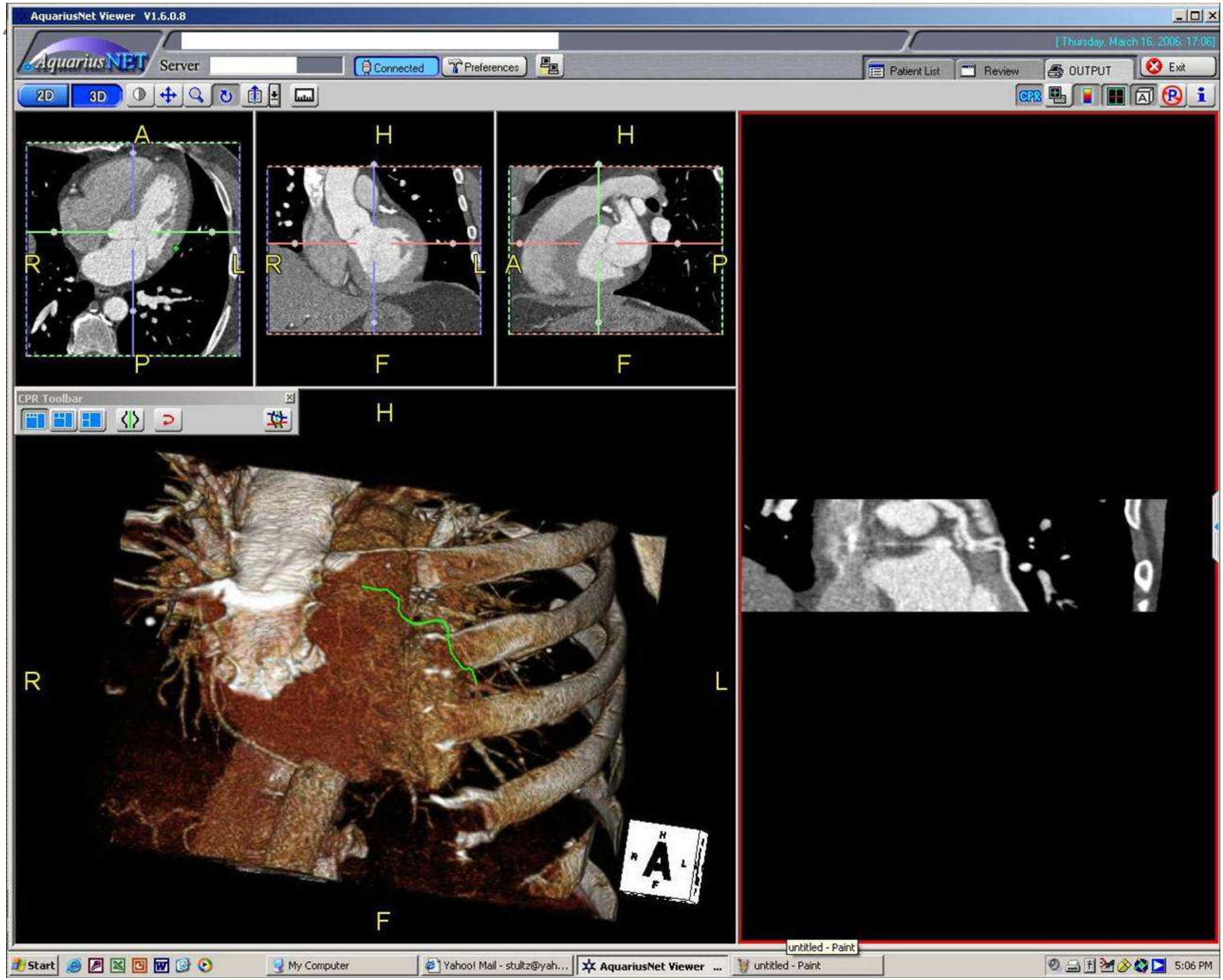
AquariusNet Viewer V1.6.0.8
AquariusNET
Server
Connected
Preferences
Patient List
Review
OUTPUT
Exit
2D
3D
CPR
A
R
L
P
H
F
CPR Toolbar
untitled - Paint
Start
My Computer
Yahoo! Mail - stultz@yah...
AquariusNet Viewer ...
untitled - Paint
5:06 PM

CPR of OM and RCA

OM CPR

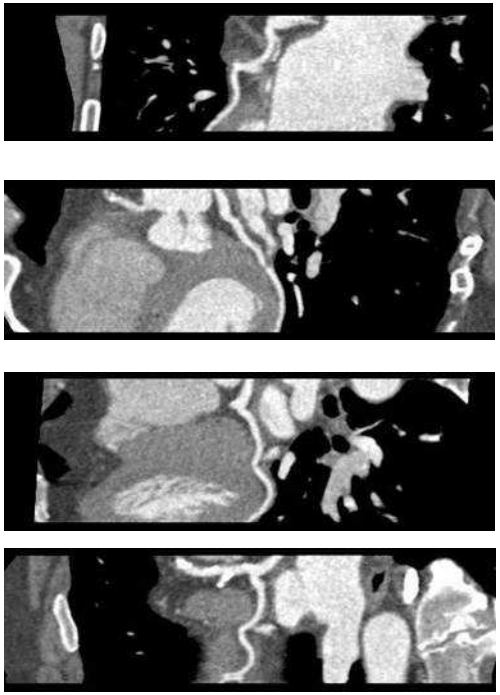

RCA CPR

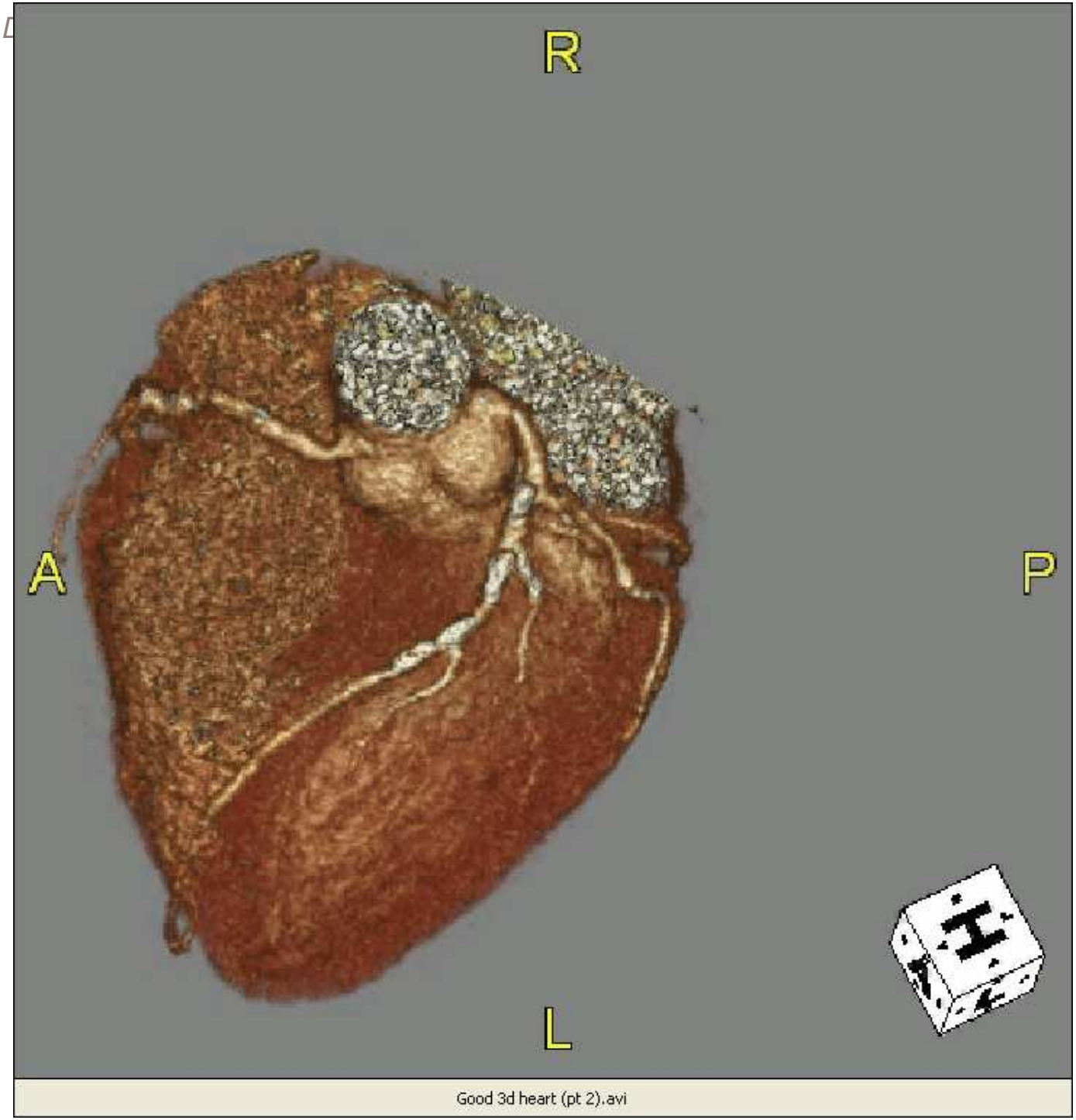

Courtesy Tom Kracus
Kettering Medical Center

VR MIP of Coronary Tree

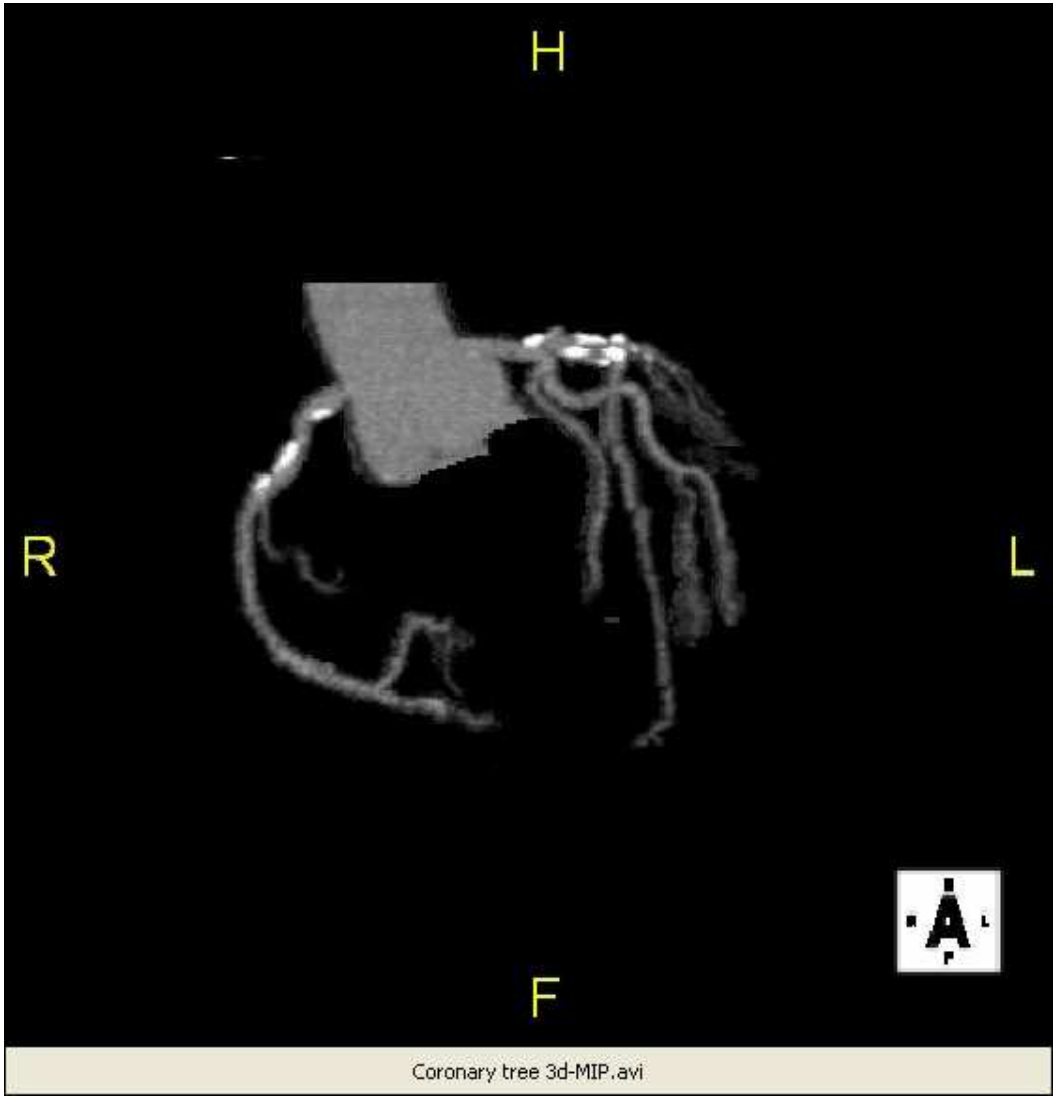

Courtesy Tom Kracus
Kettering Medical Center


AquariusNet Viewer V1.6.0.8
AquariusNET
Server
Connected
Preferences
Patient List
Review
OUTPUT
Exit
2D
3D
CPR
3D
Angle
A P H F R L
Reset
Continue
Template
3D Settings
Slab
Mask
Light
Option
Slab
Lock CrossHairs
Half Space
Invert MIP
Slab fixed to screen
Thickness (mm)
Slab Cine
MPR
Abd1
Abd2
Head
Lung
Bone
Reset
Window Level
Position / Cine
RaySum
WW 1200
WL 375
ColorTemplate
Invert
3D
MIP
3D
MIP
A Axial
S Sagittal
C Coronal
Start
untitled - Paint
C:\Documents and Settin...
AquariusNet Viewer ...
4:14 PM

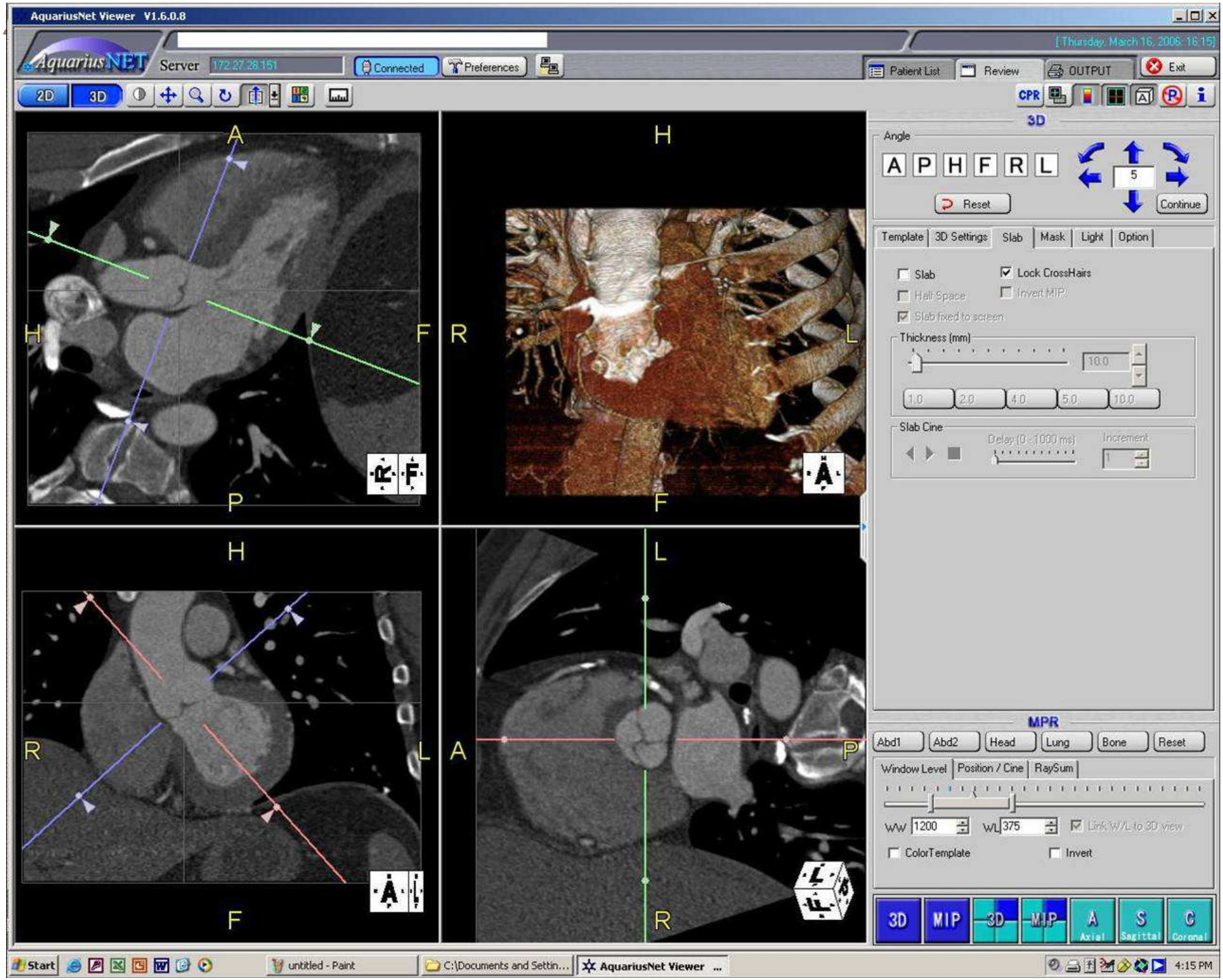
AquariusNet Viewer V1.6.0.8
AquariusNET
Server
172.27.28.151
Connected
Preferences
Patient List
Review
OUTPUT
Exit
2D
3D
CPR
3D
Angle
A P H F R L
5
Reset
Continue
Template
3D Settings
Slab
Mask
Light
Option
Slab
Lock CrossHairs
Half Space
Invert MIP
Slab fixed to screen
Thickness (mm)
10.0
1.0
2.0
4.0
5.0
10.0
Slab Cine
Delay (0 - 1000 ms)
Increment
MPR
Abd1
Abd2
Head
Lung
Bone
Reset
Window Level
Position / Cine
RaySum
WW 1200
WL 375
Link W/L to 3D view
ColorTemplate
Invert
3D
MIP
3D
MIP
A Axial
S Sagittal
C Coronal
Start
untitled - Paint
C:\Documents and Settin...
AquariusNet Viewer ...
4:15 PM

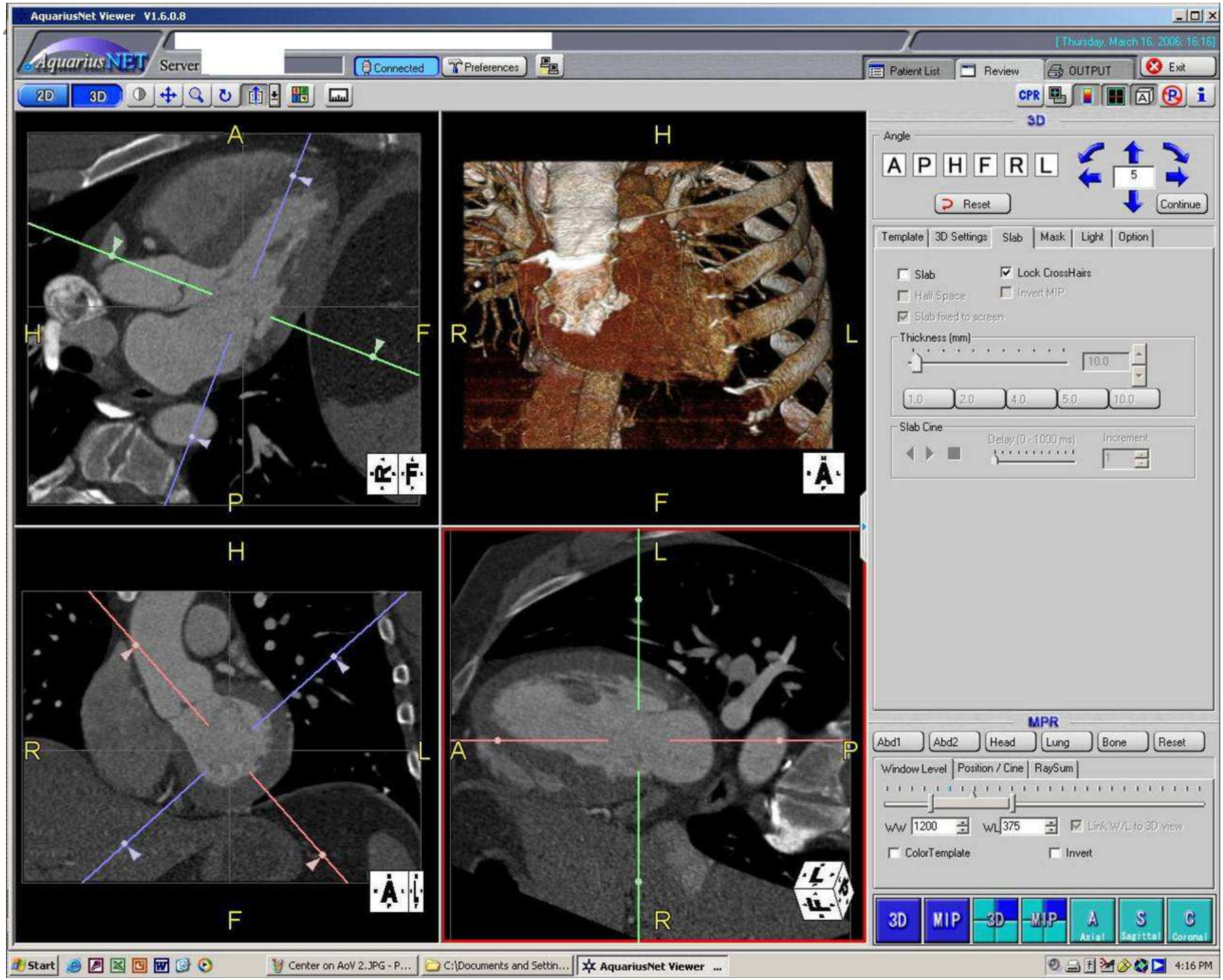
AquariusNet Viewer V1.6.0.8
AquariusNET
Server
Connected
Preferences
Patient List
Review
OUTPUT
Exit
2D
3D
CPR
3D
Angle
A P H F R L
5
Reset
Continue
Template
3D Settings
Slab
Mask
Light
Option
Slab
Lock CrossHairs
Half Space
Invert MIP
Slab fixed to screen
Thickness (mm)
Slab Cine
MPR
Abd1
Abd2
Head
Lung
Bone
Reset
Window Level
Position / Cine
RaySum
WW 1200
WL 375
ColorTemplate
Invert
3D
MIP
3D
MIP
A Axial
S Sagittal
C Coronal
Start
Center on AoV 2.JPG - P...
C:\Documents and Settin...
AquariusNet Viewer ...
4:16 PM

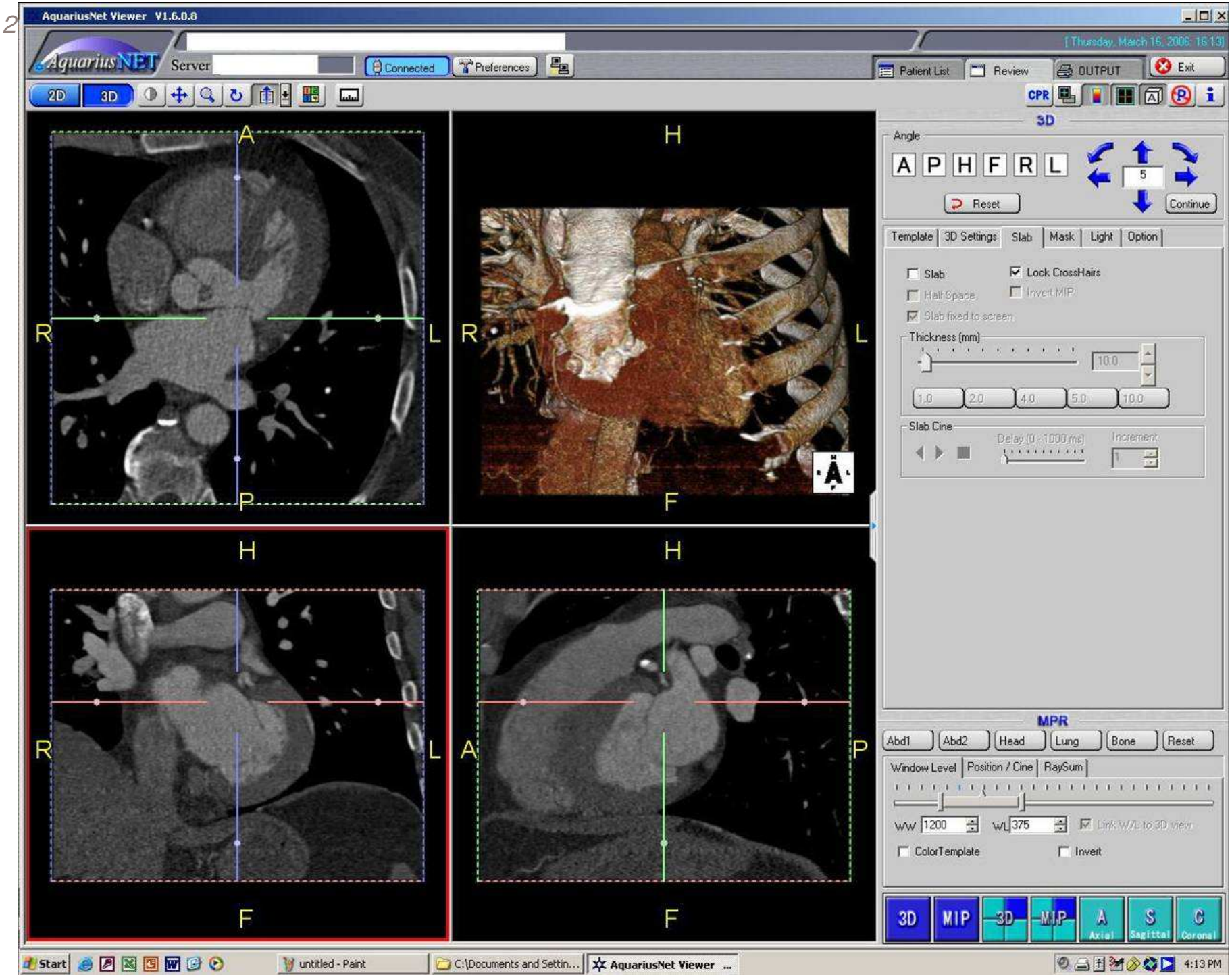
AquariusNet Viewer V1.6.0.8
AquariusNET
Server
Connected
Preferences
Patient List
Review
OUTPUT
Exit
2D
3D
CPR
3D
Angle
A P H F R L
5
Reset
Continue
Template
3D Settings
Slab
Mask
Light
Option
Slab
Lock CrossHairs
Half Space
Invert MIP
Slab fixed to screen
Thickness (mm)
10.0
1.0
2.0
4.0
5.0
10.0
Slab Cine
Delay (0 - 1000 ms)
Increment
MPR
Abd1
Abd2
Head
Lung
Bone
Reset
Window Level
Position / Cine
RaySum
WW 1200
WL 375
Link W/L to 3D view
ColorTemplate
Invert
3D
MIP
3D
MIP
A Axial
S Sagittal
C Coronal
Start
untitled - Paint
C:\Documents and Settin...
AquariusNet Viewer ...
4:13 PM

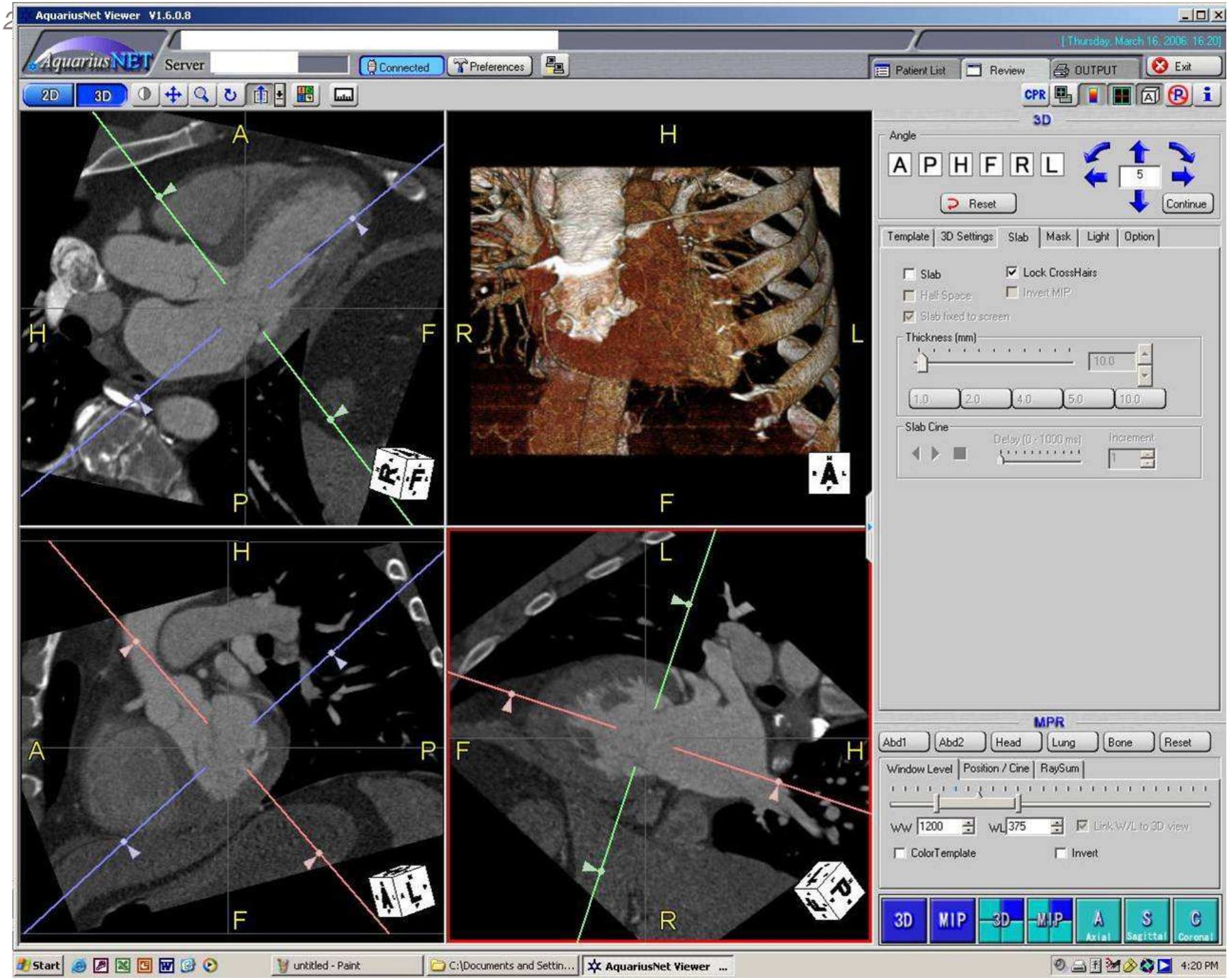
AquariusNet Viewer V1.6.0.8
AquariusNET
Server
Connected
Preferences
Patient List
Review
OUTPUT
Exit
2D
3D
CPR
3D
Angle
A P H F R L
5
Reset
Continue
Template
3D Settings
Slab
Mask
Light
Option
Slab
Lock CrossHairs
Half Space
Invert MIP
Slab fixed to screen
Thickness (mm)
10.0
1.0
2.0
4.0
5.0
10.0
Slab Cine
Delay (0 - 1000 ms)
Increment
MPR
Abd1
Abd2
Head
Lung
Bone
Reset
Window Level
Position / Cine
RaySum
WW 1200
WL 375
Link W/L to 3D view
ColorTemplate
Invert
3D
MIP
3D
MIP
A Axial
S Sagittal
C Coronal
Start
untitled - Paint
C:\Documents and Settin...
AquariusNet Viewer ...
4:20 PM

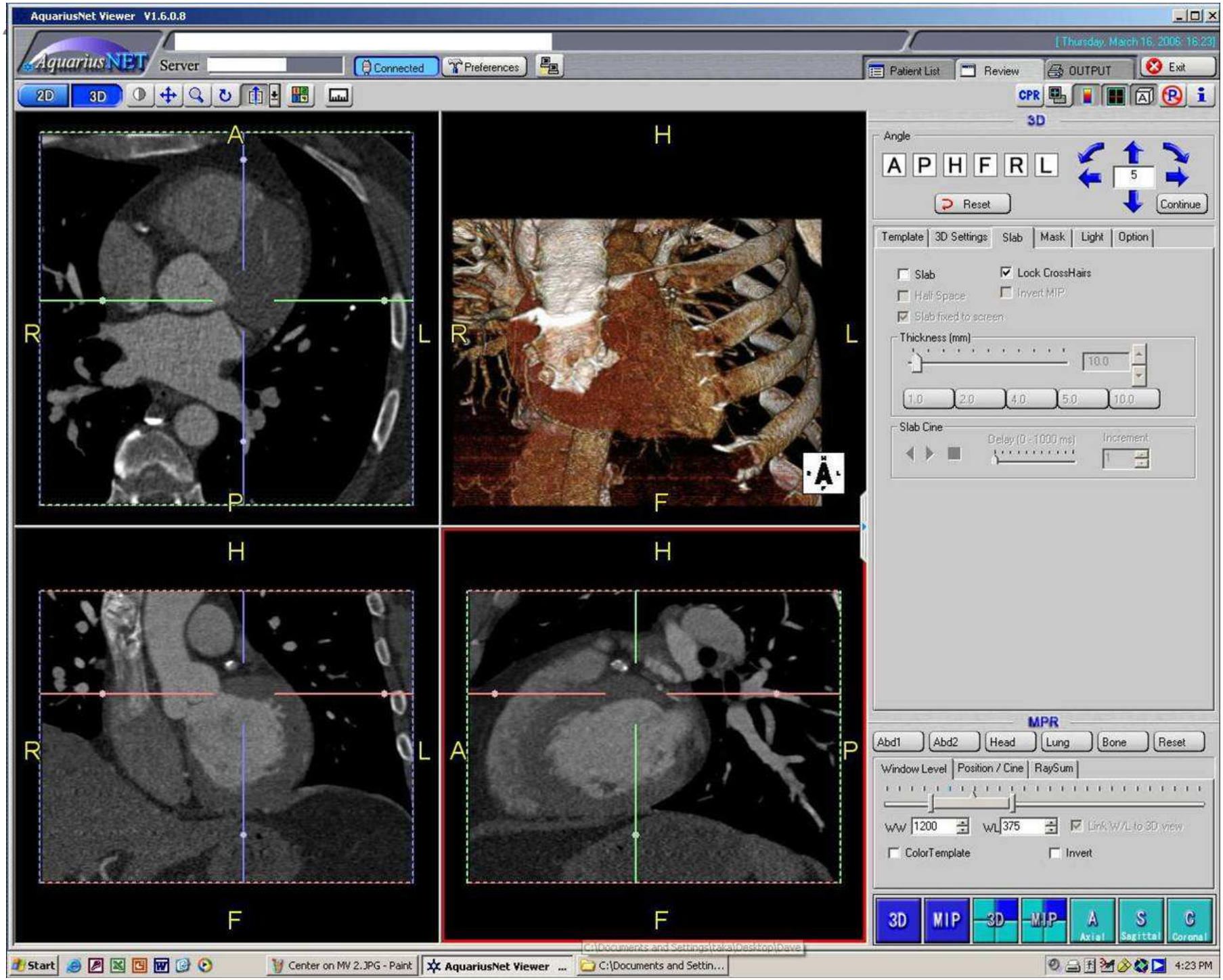
AquariusNet Viewer V1.6.0.8
AquariusNET
Server
Connected
Preferences
Patient List
Review
OUTPUT
Exit
2D
3D
CPR
3D
Angle
A P H F R L
5
Reset
Continue
Template
3D Settings
Slab
Mask
Light
Option
Slab
Lock CrossHairs
Half Space
Invert MIP
Slab fixed to screen
Thickness (mm)
10.0
1.0
2.0
4.0
5.0
10.0
Slab Cine
Delay (0 - 1000 ms)
Increment
MPR
Abd1
Abd2
Head
Lung
Bone
Reset
Window Level
Position / Cine
RaySum
WW 1200
WL 375
Link W/L to 3D view
ColorTemplate
Invert
3D
MIP
3D
MIP
A Axial
S Sagittal
C Coronal
A
R
L
P
H
F
Start
Center on MV 2.JPG - Paint
AquariusNet Viewer ...
C:\Documents and Settin...
4:23 PM

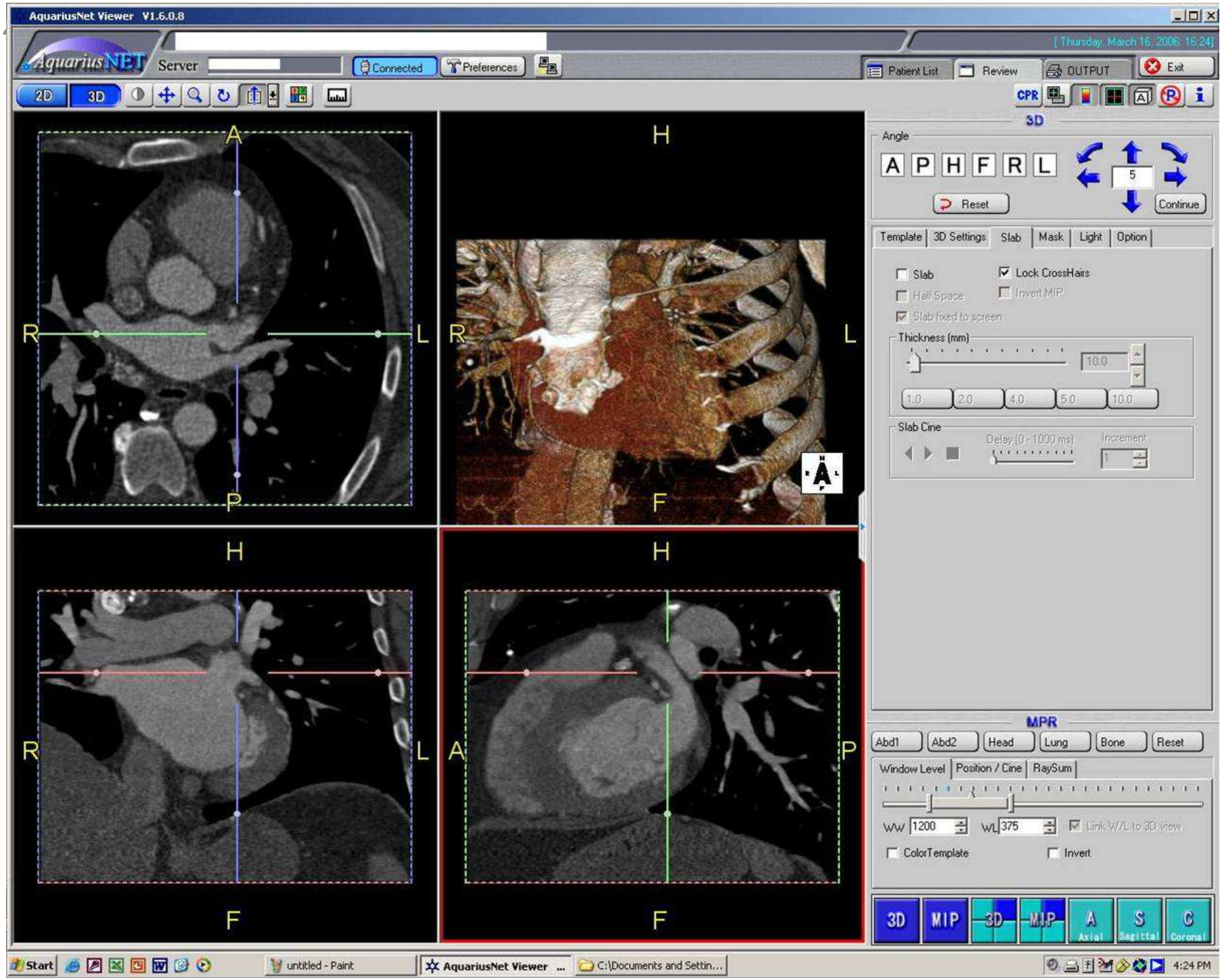
AquariusNet Viewer V1.6.0.8
AquariusNET
Server
Connected
Preferences
[Thursday, March 16, 2006 16:24]
Patient List
Review
OUTPUT
Exit
2D
3D
CPR
A
R
L
P
H
F
3D
Angle
A P H F R L
5
Reset
Continue
Template
3D Settings
Slab
Mask
Light
Option
Slab
Half Space
Slab fixed to screen
Lock CrossHairs
Invert MIP
Thickness (mm)
10.0
1.0
2.0
4.0
5.0
10.0
Slab Cine
Delay (0 - 1000 ms)
Increment
MPR
Abd1
Abd2
Head
Lung
Bone
Reset
Window Level
Position / Cine
RaySum
WW 1200
WL 375
Link W/L to 3D view
ColorTemplate
Invert
3D
MIP
3D
MIP
A
Axial
S
Sagittal
C
Coronal
Start
untitled - Paint
AquariusNet Viewer ...
C:\Documents and Settin...
4:24 PM

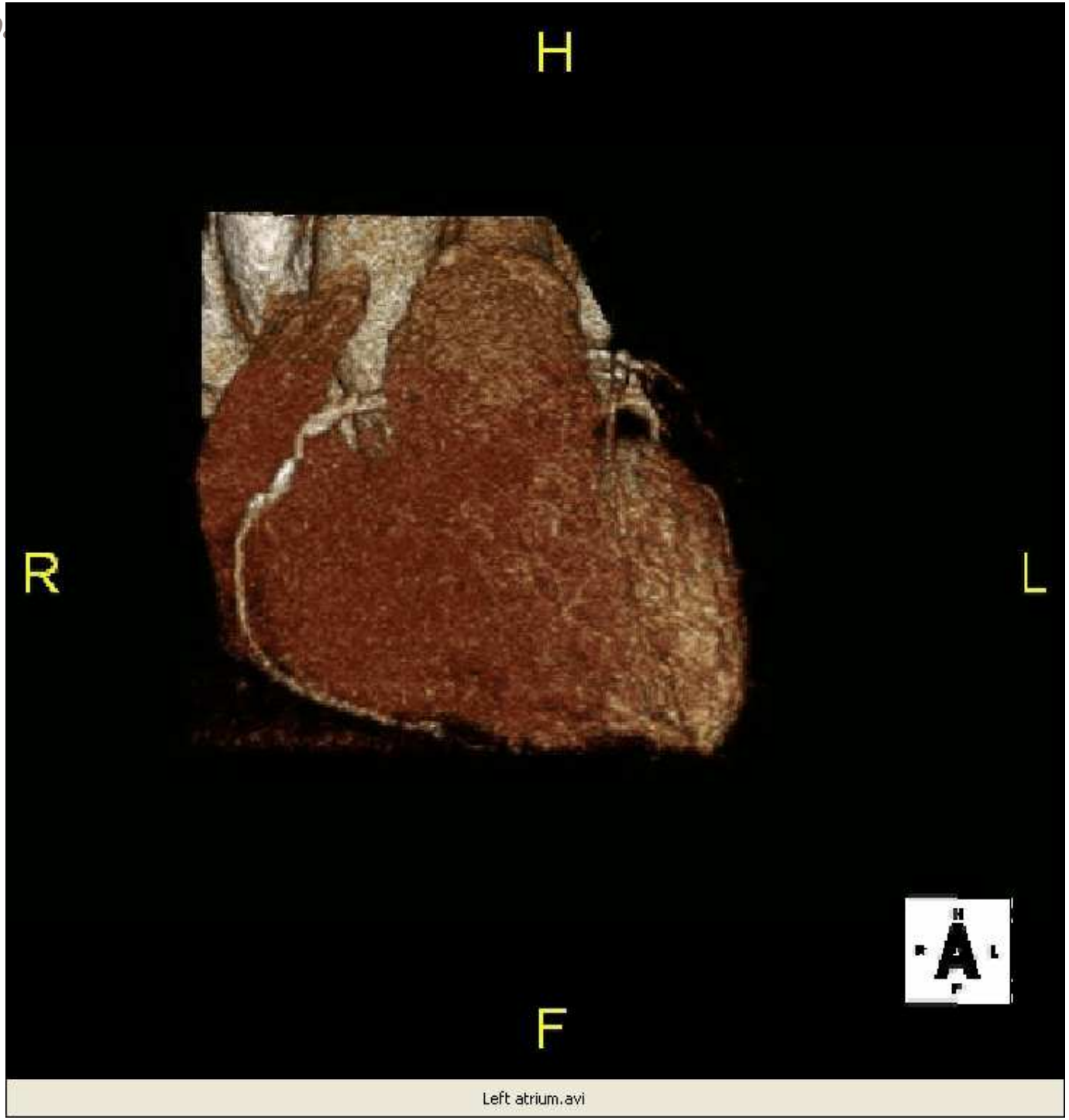

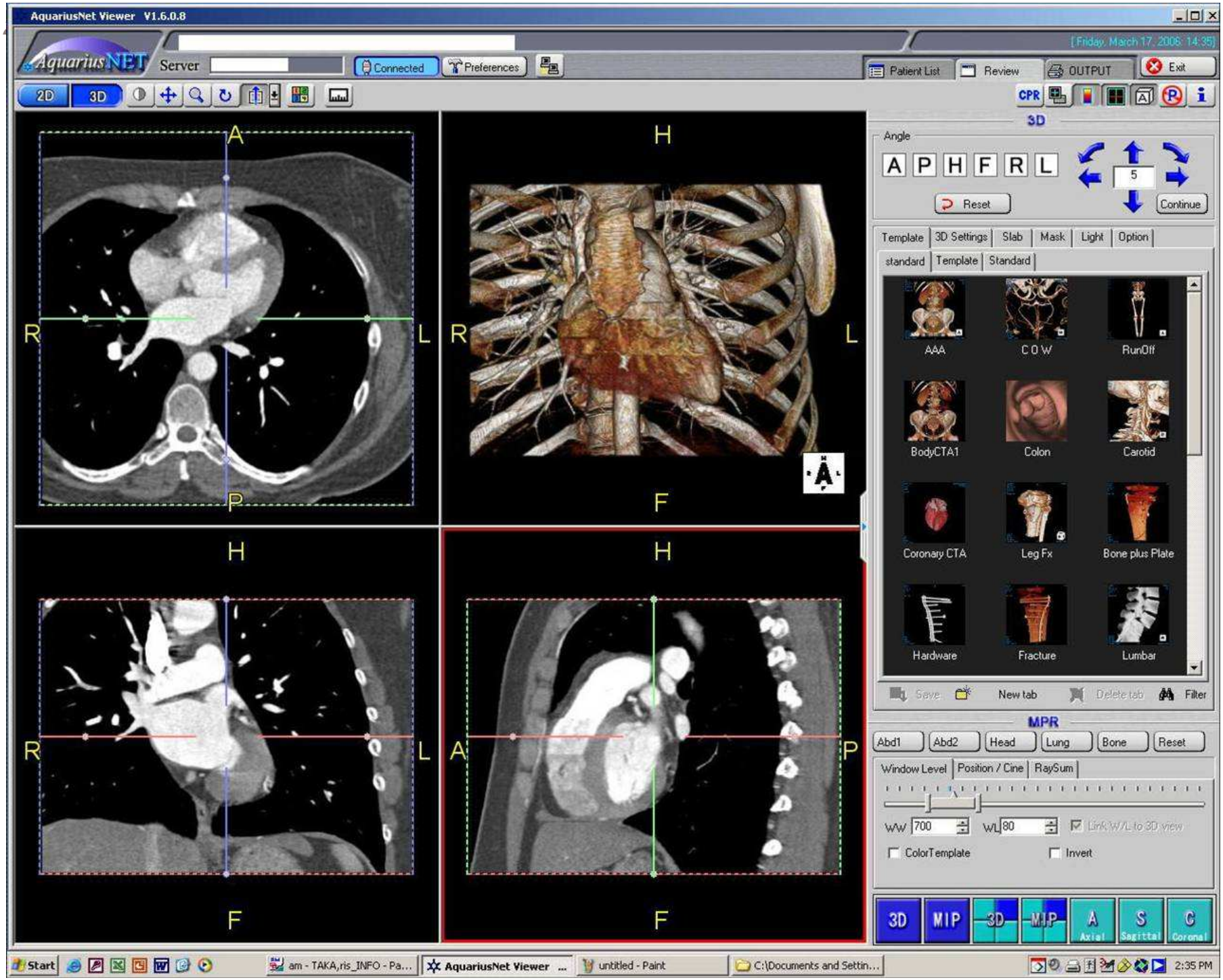
AquariusNet Viewer V1.6.0.8
AquariusNET
Server
Connected
Preferences
Patient List
Review
OUTPUT
Exit
2D
3D
CPR
3D
Angle
A P H F R L
5
Reset
Continue
Template
3D Settings
Slab
Mask
Light
Option
standard
Template
Standard
AAA
C O W
RunOff
BodyCTA1
Colon
Carotid
Coronary CTA
Leg Fx
Bone plus Plate
Hardware
Fracture
Lumbar
Save
New tab
Delete tab
Filter
MPR
Abd1
Abd2
Head
Lung
Bone
Reset
Window Level
Position / Cine
RaySum
WW 700
WL 80
Link W/L to 3D view
ColorTemplate
Invert
3D
MIP
3D
MIP
A Axial
S Sagittal
C Coronal
Start
am - TAKA,ris_INFO - Pa...
AquariusNet Viewer ...
untitled - Paint
C:\Documents and Settin...
2:35 PM


AquariusNet Viewer V1.6.0.8
AquariusNET
Server
Connected
Preferences
Patient List
Review
OUTPUT
Exit
2D
3D
CPR
A
R
L
P
H
F
3D
Angle
A P H F R L
5
Reset
Continue
Template
3D Settings
Slab
Mask
Light
Option
standard
Template
Standard
AAA
C O W
RunOff
BodyCTA1
Colon
Carotid
Coronary CTA
Leg Fx
Bone plus Plate
Hardware
Fracture
Lumbar
Save
New tab
Delete tab
Filter
MPR
Abd1
Abd2
Head
Lung
Bone
Reset
Window Level
Position / Cine
RaySum
WW 700
WL 80
Link W/L to 3D view
ColorTemplate
Invert
3D
MIP
3D
MIP
A Axial
S Sagittal
C Coronal
Start
am - TAKA,ris_INFO - Pa...
AquariusNet Viewer ...
untitled - Paint
C:\Documents and Settin...
2:37 PM

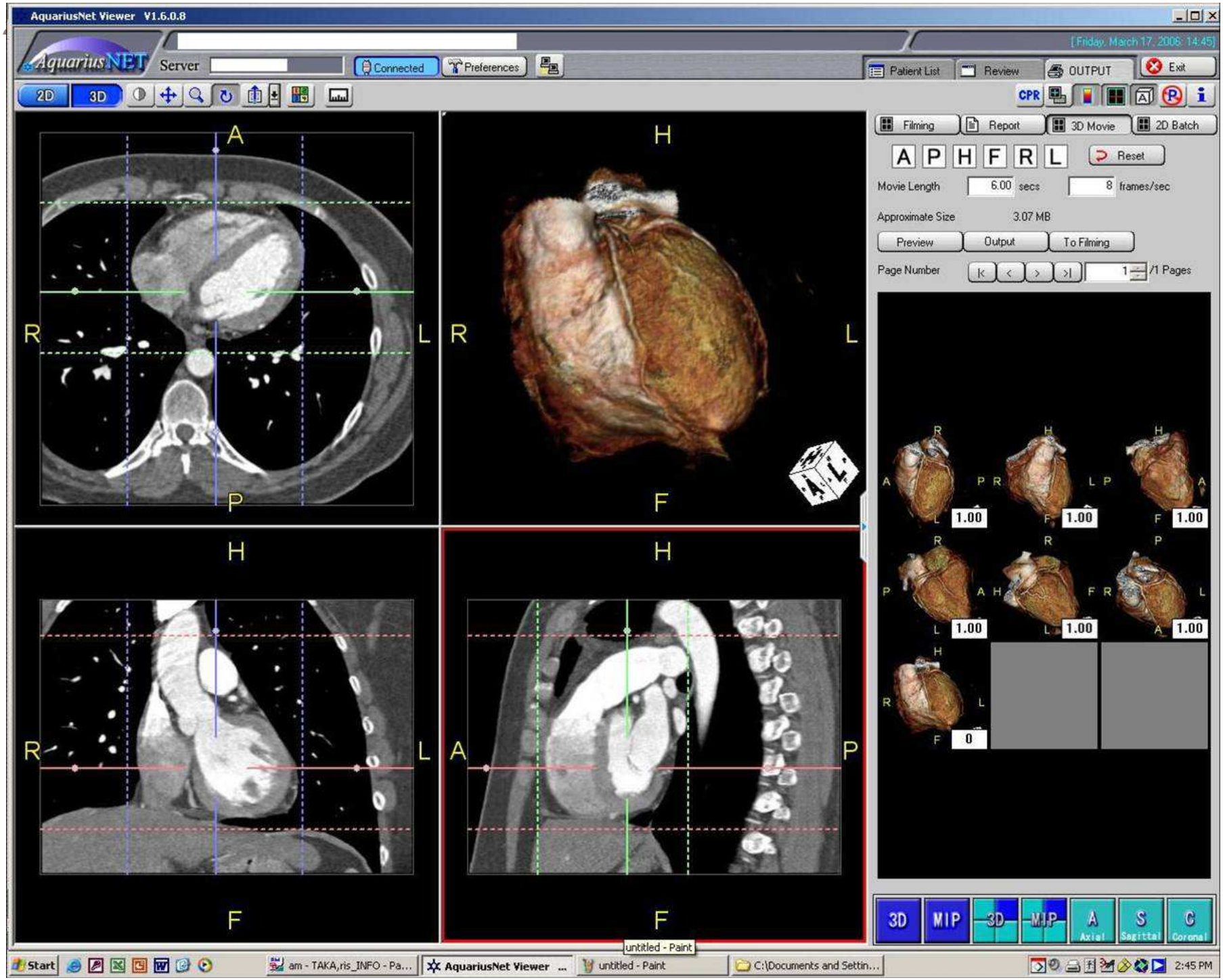
AquariusNet Viewer V1.6.0.8
AquariusNET
Server
Connected
Preferences
Patient List
Review
OUTPUT
Exit
2D
3D
CPR
Filming
Report
3D Movie
2D Batch
A P H F R L
Reset
Movie Length
6.00
secs
8
frames/sec
Approximate Size
3.07 MB
Preview
Output
To Filming
Page Number
1
/1 Pages
3D
MIP
3D
MIP
A
Axial
S
Sagittal
C
Coronal
Start
untitled - Paint
AquariusNet Viewer
2:45 PM

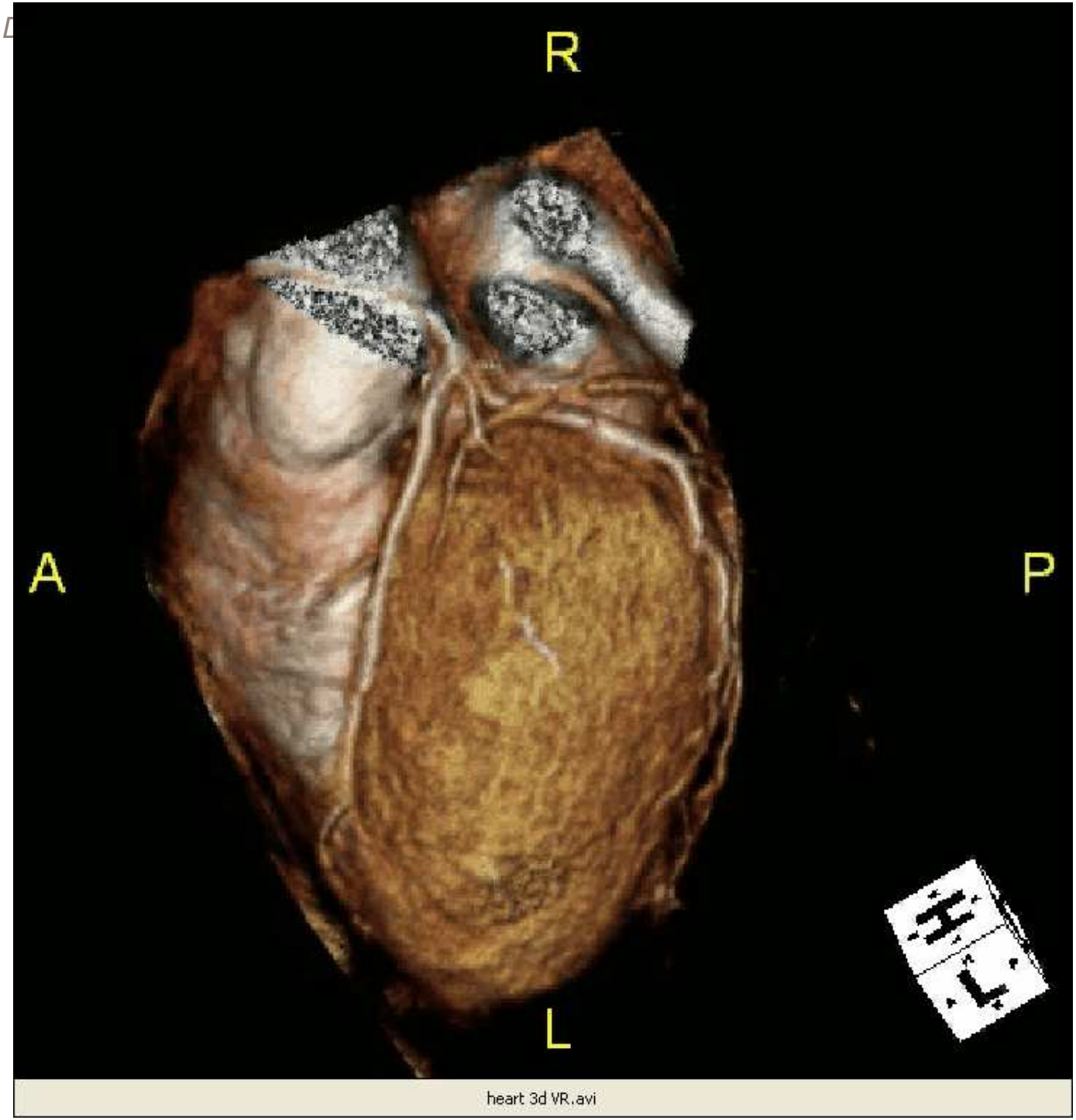

LAD MIP – 10 mm

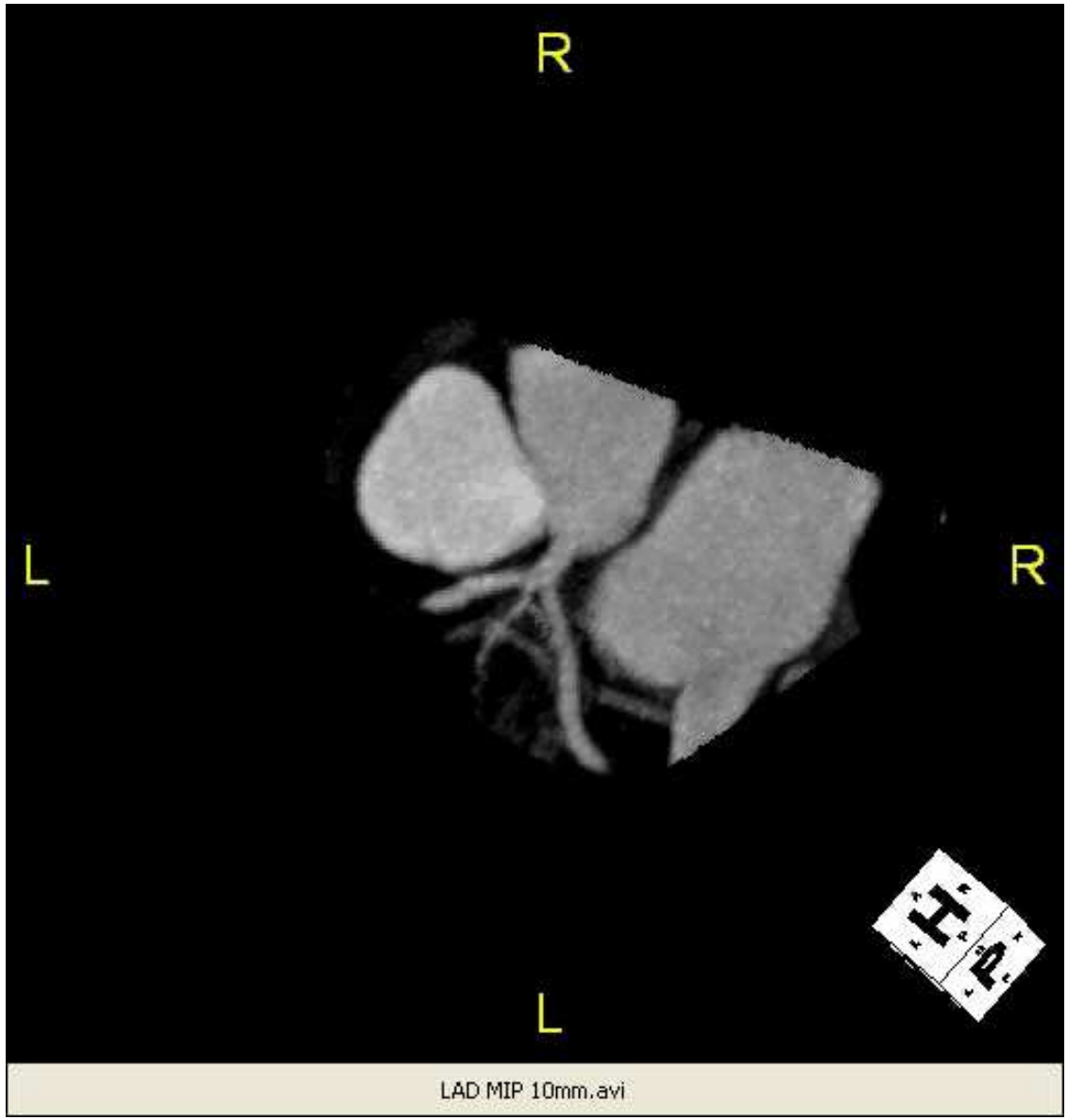

RCA MIP – 10mm

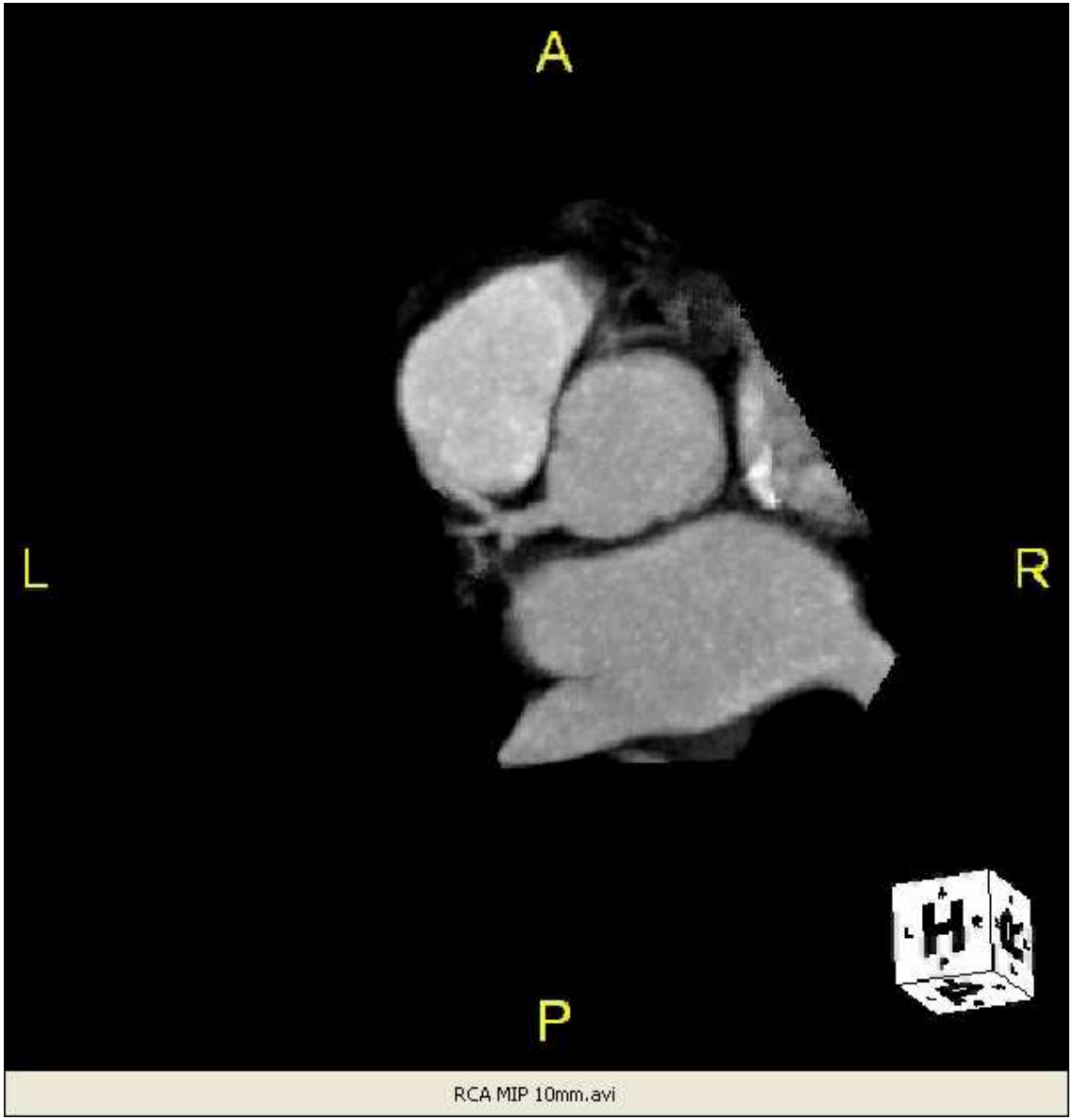

Cx MIP – 10mm

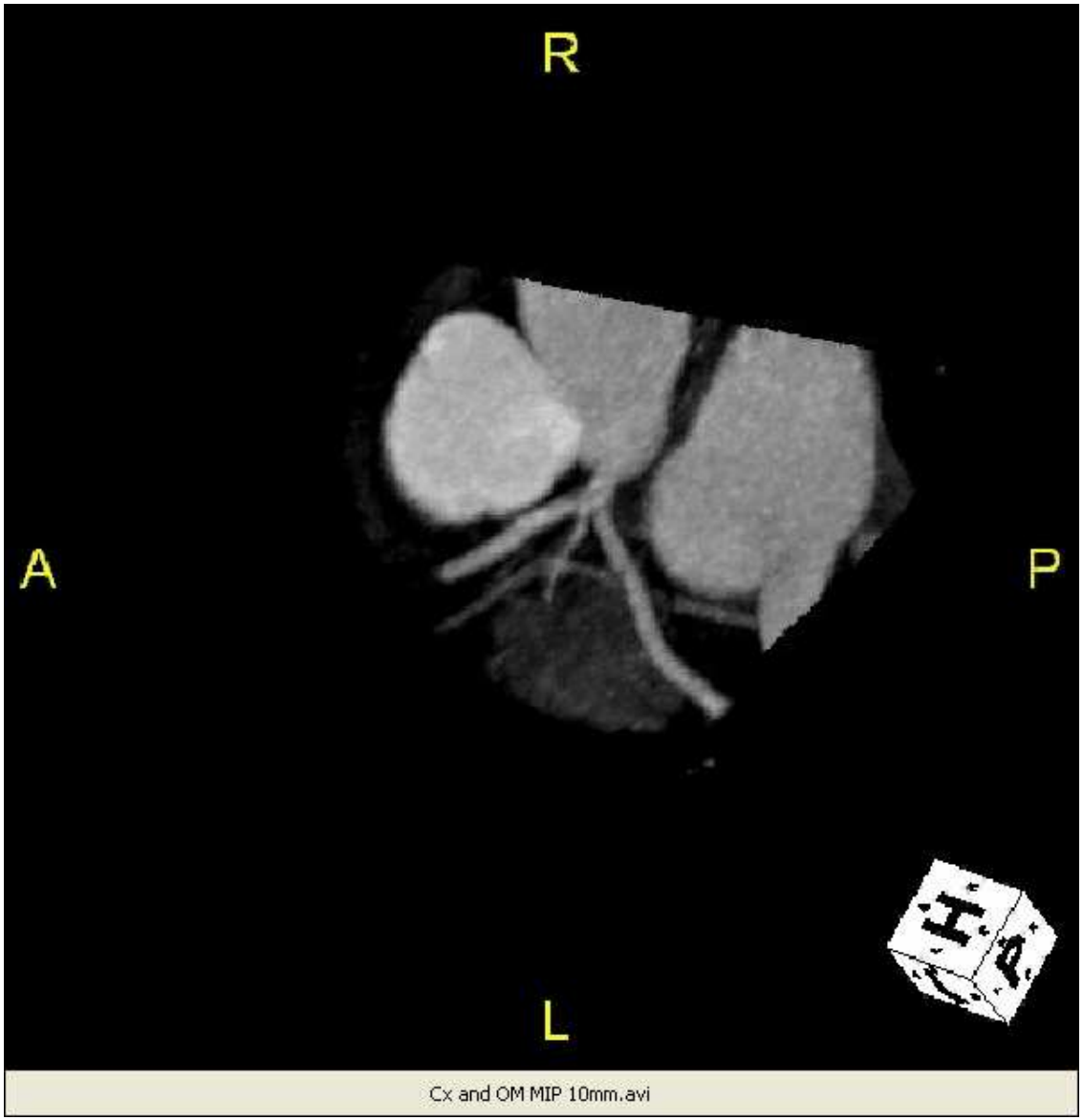

Cx MPR – 1mm

CPR of Cx

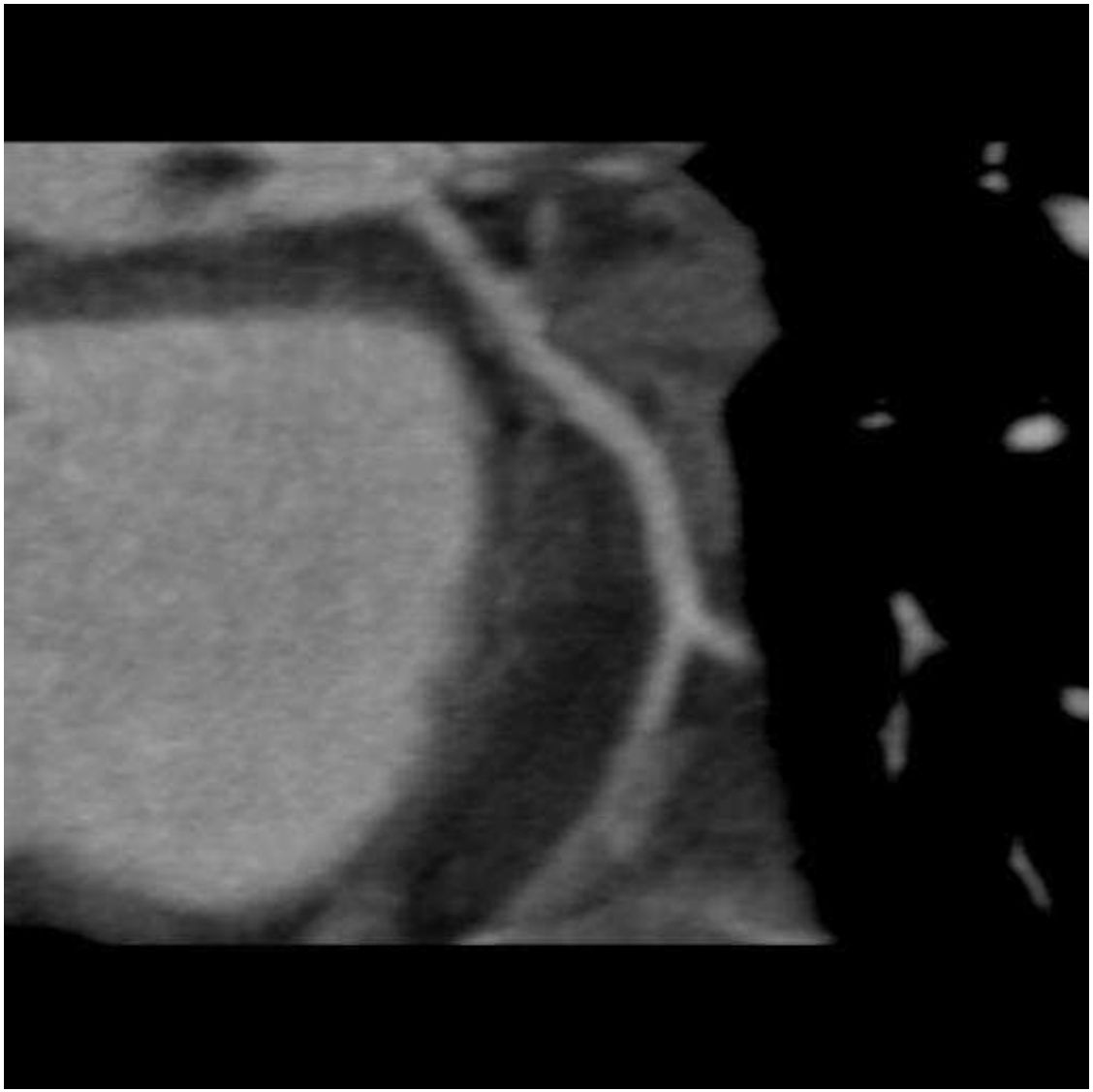

RAO slices

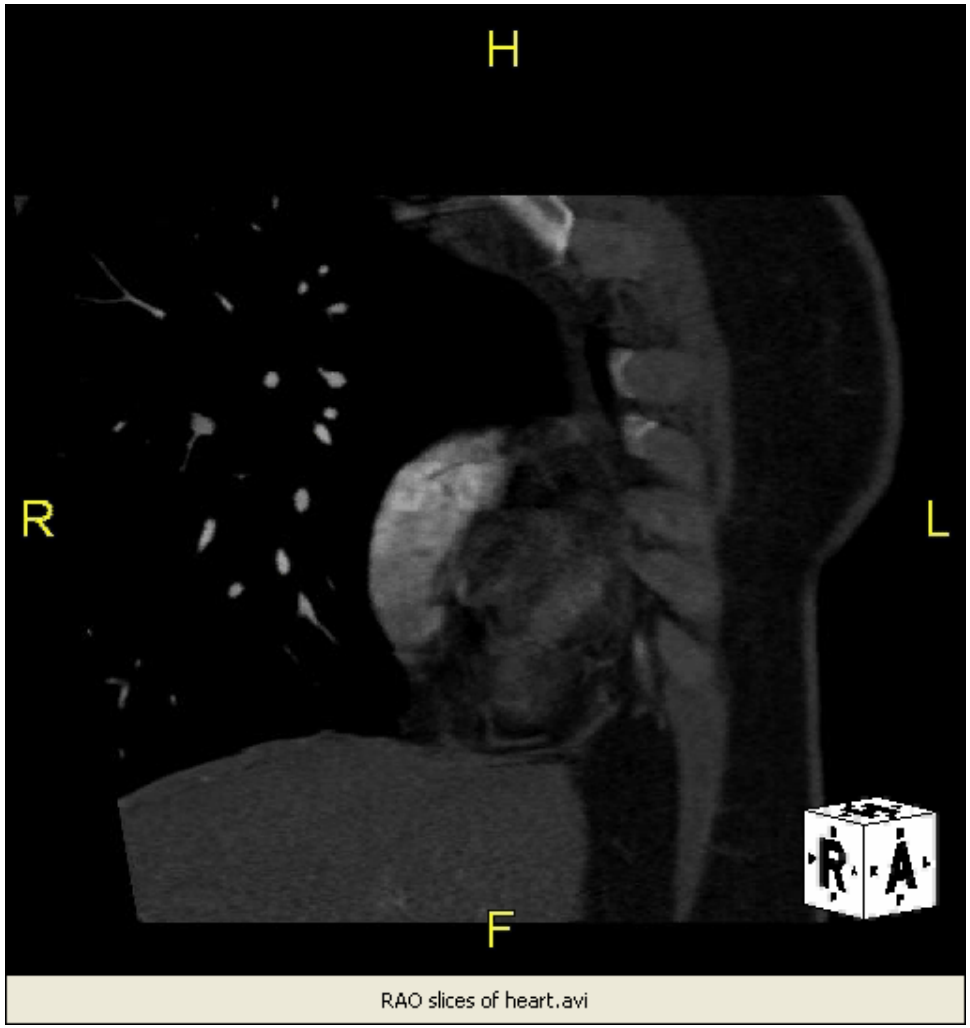

LAO slices

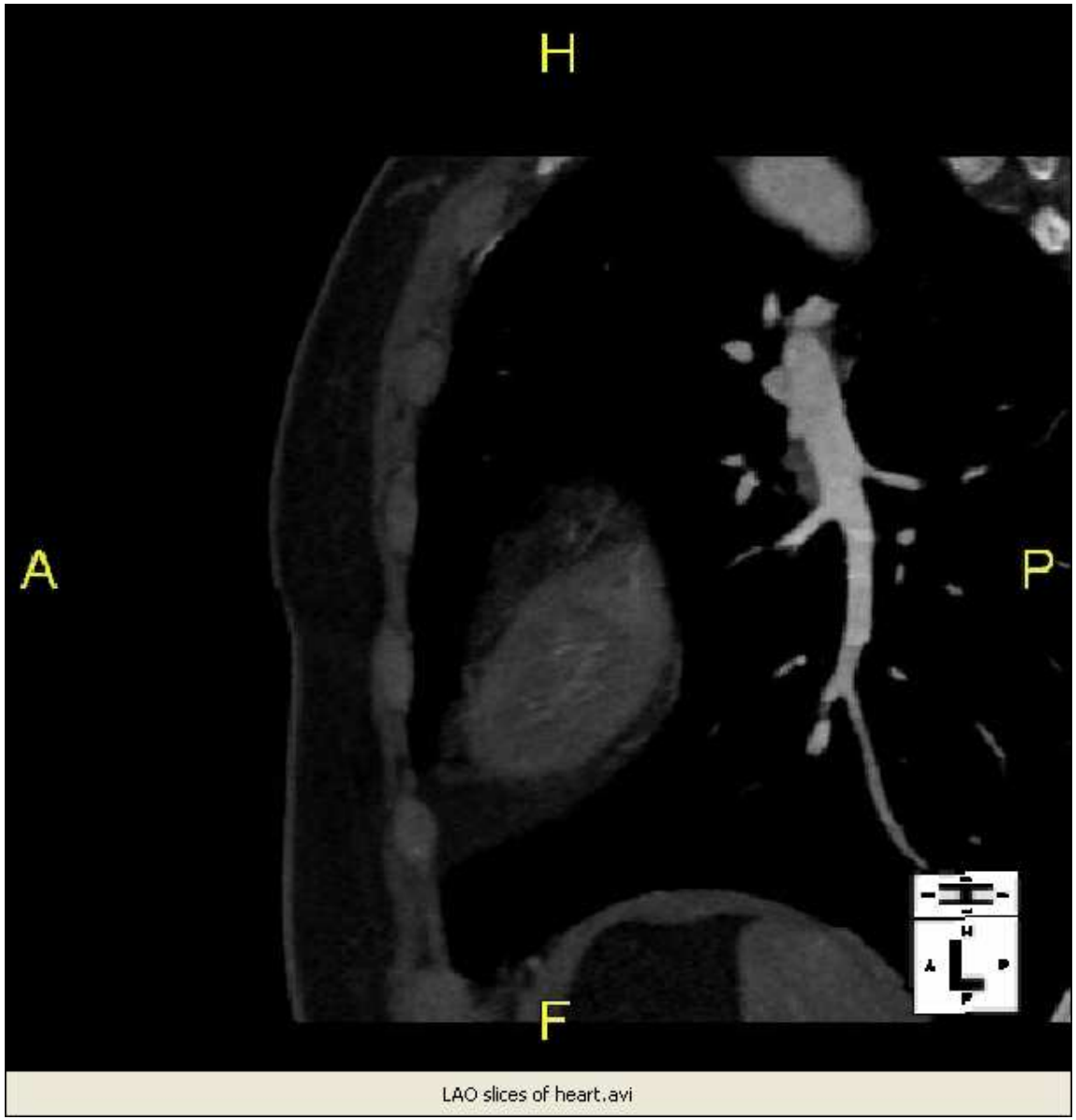

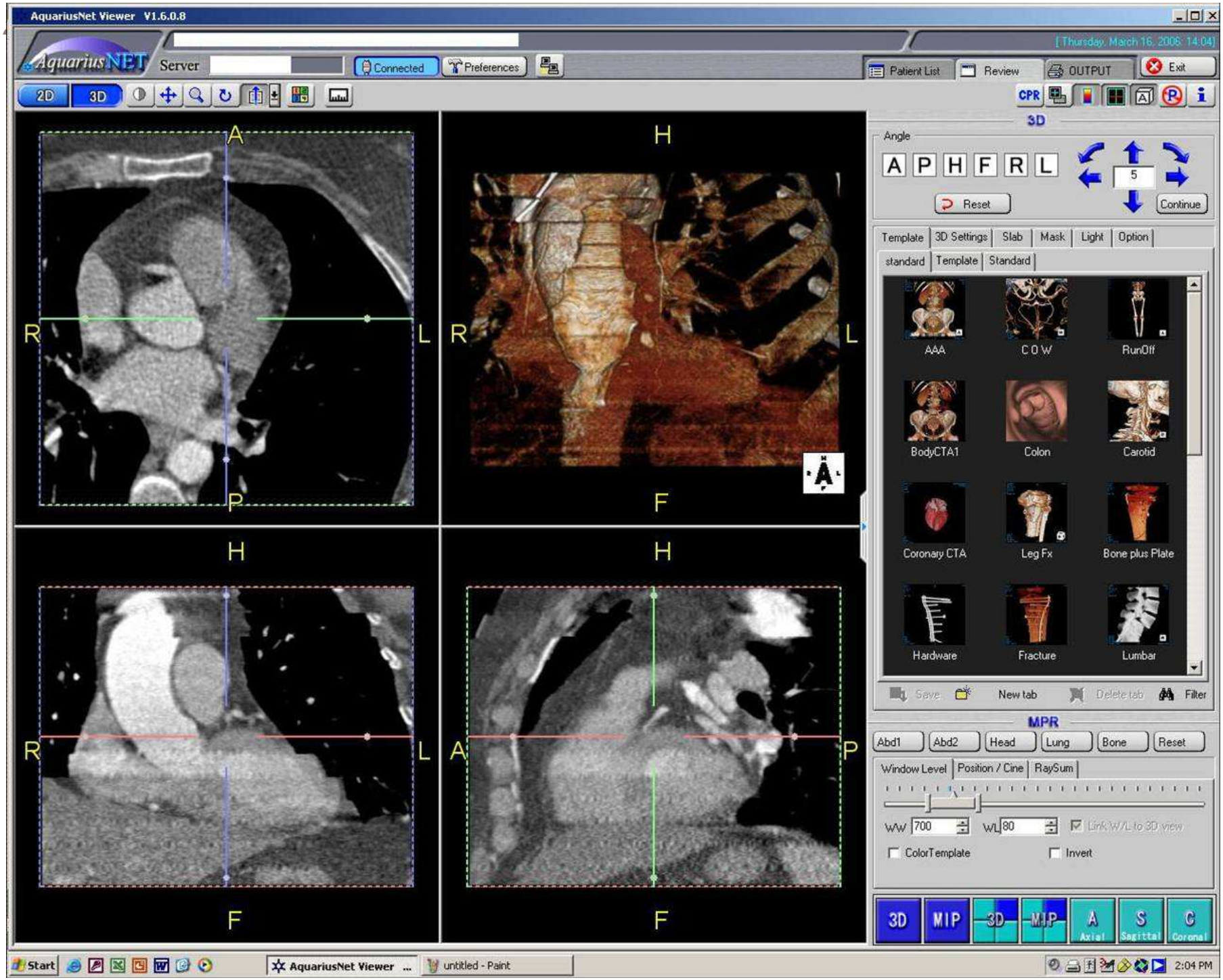
AquariusNet Viewer V1.6.0.8
AquariusNET
Server
Connected
Preferences
Patient List
Review
OUTPUT
Exit
2D
3D
CPR
3D
Angle
A P H F R L
5
Reset
Continue
Template
3D Settings
Slab
Mask
Light
Option
standard
Template
Standard
AAA
C O W
RunOff
BodyCTA1
Colon
Carotid
Coronary CTA
Leg Fx
Bone plus Plate
Hardware
Fracture
Lumbar
Save
New tab
Delete tab
Filter
MPR
Abd1
Abd2
Head
Lung
Bone
Reset
Window Level
Position / Cine
RaySum
WW 700
WL 80
Link W/L to 3D view
ColorTemplate
Invert
3D
MIP
3D
MIP
A Axial
S Sagittal
C Coronal
Start
AquariusNet Viewer ...
untitled - Paint
2:04 PM

Raw Axial Slices

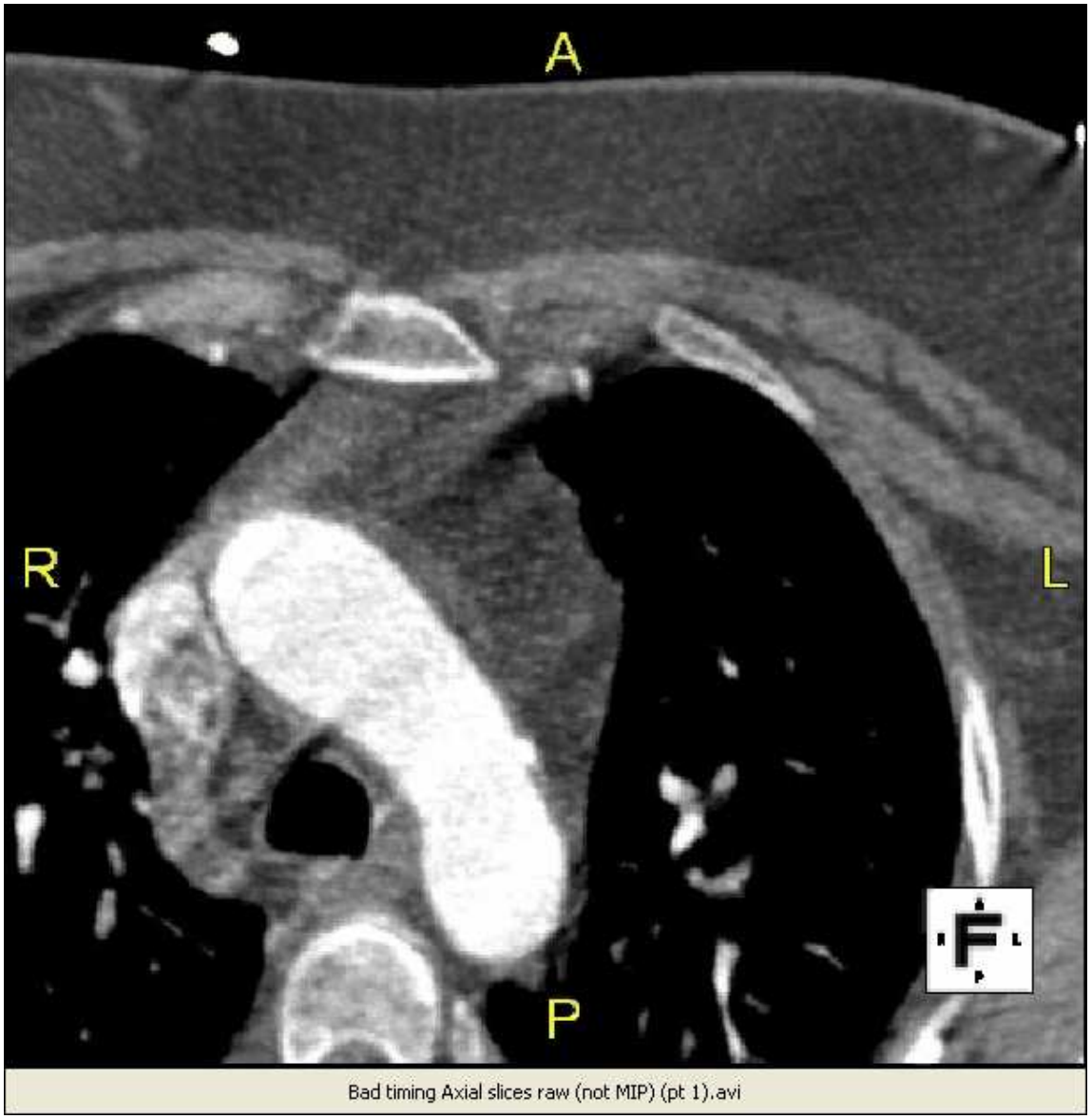

MIP axial slices

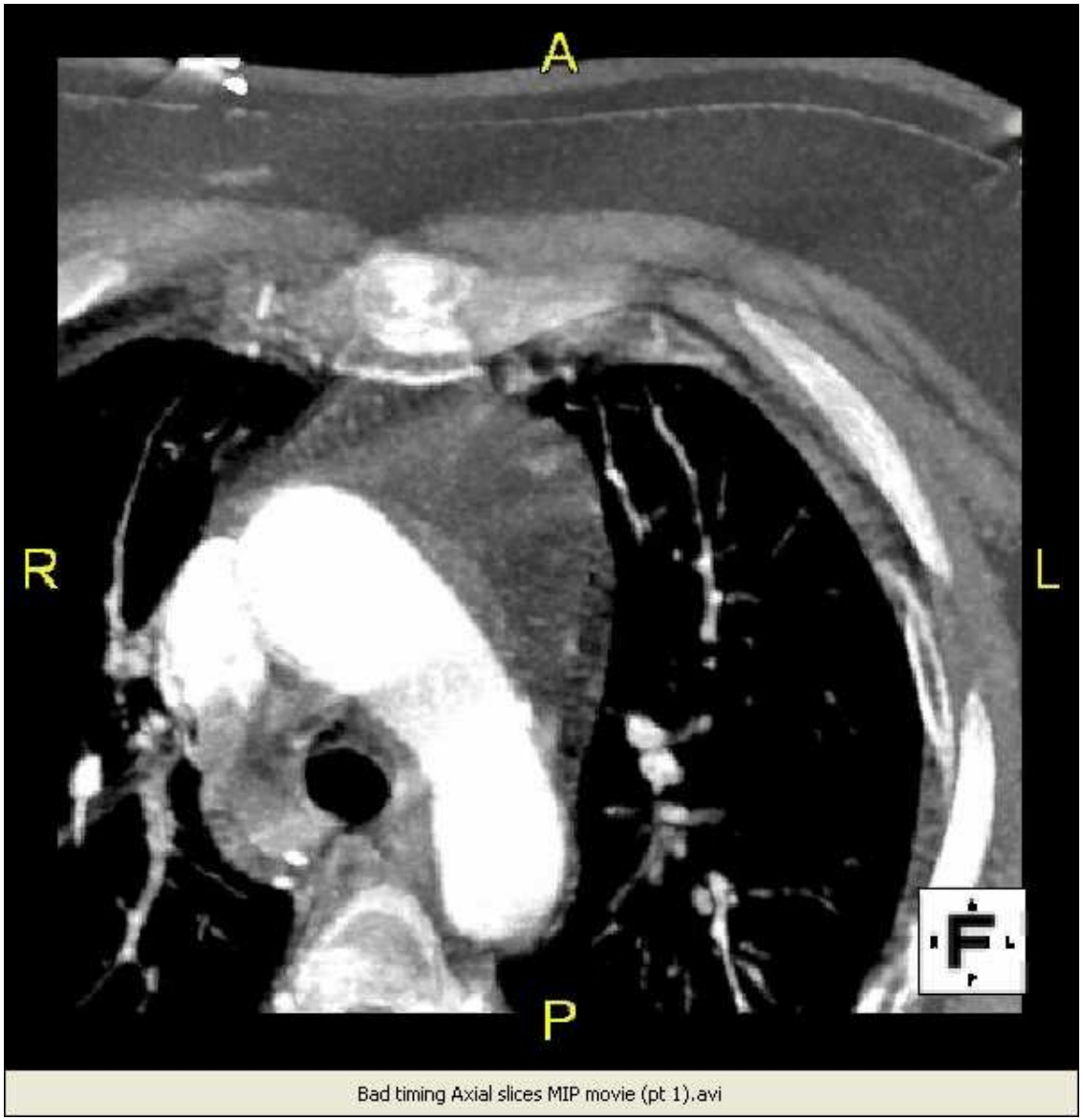

Another patient
LAD mid aneurysm and stenosis

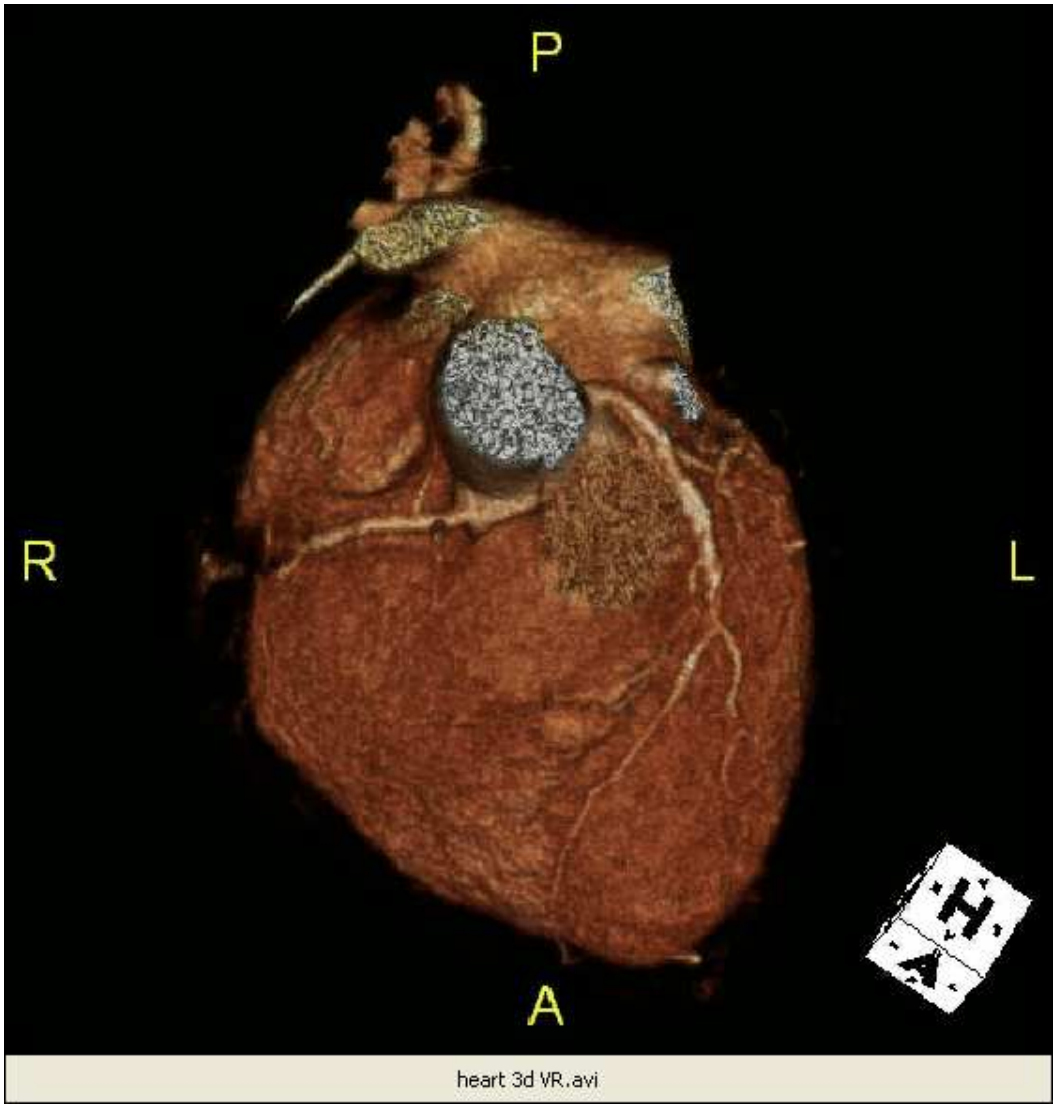

LAD MIP – 10 mm

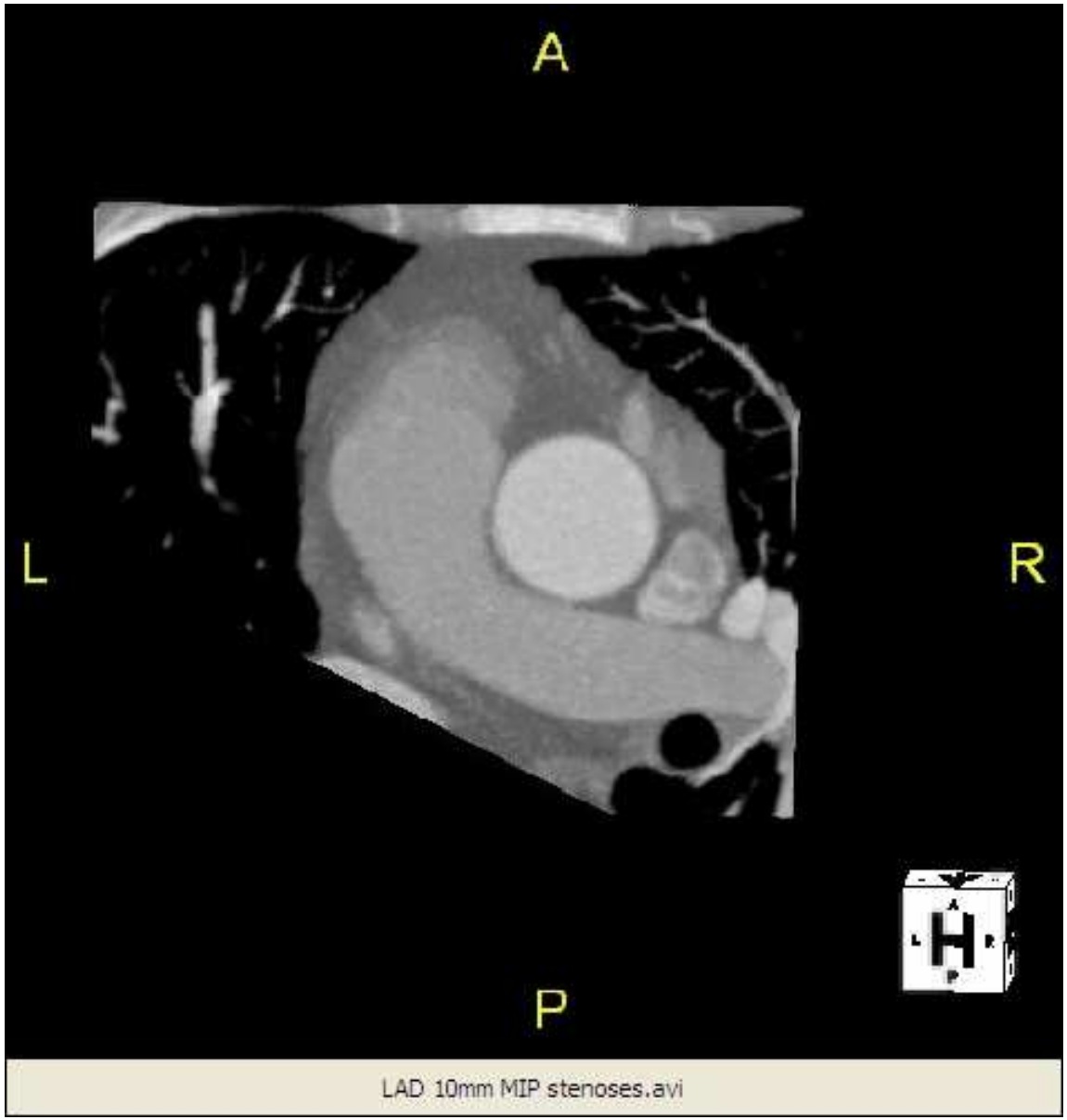

LAD – MPR 1mm

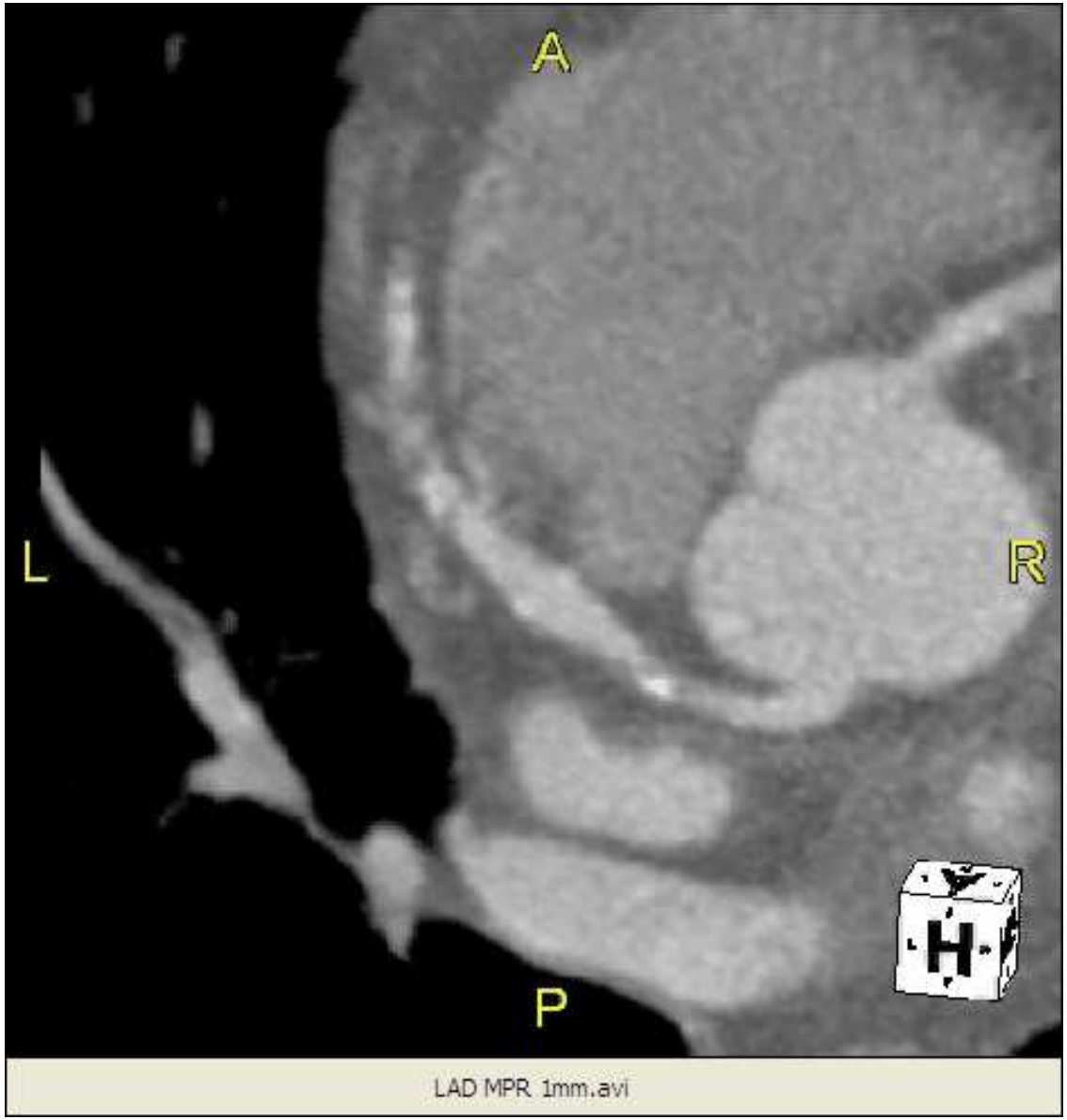

Cx MIP – 10mm

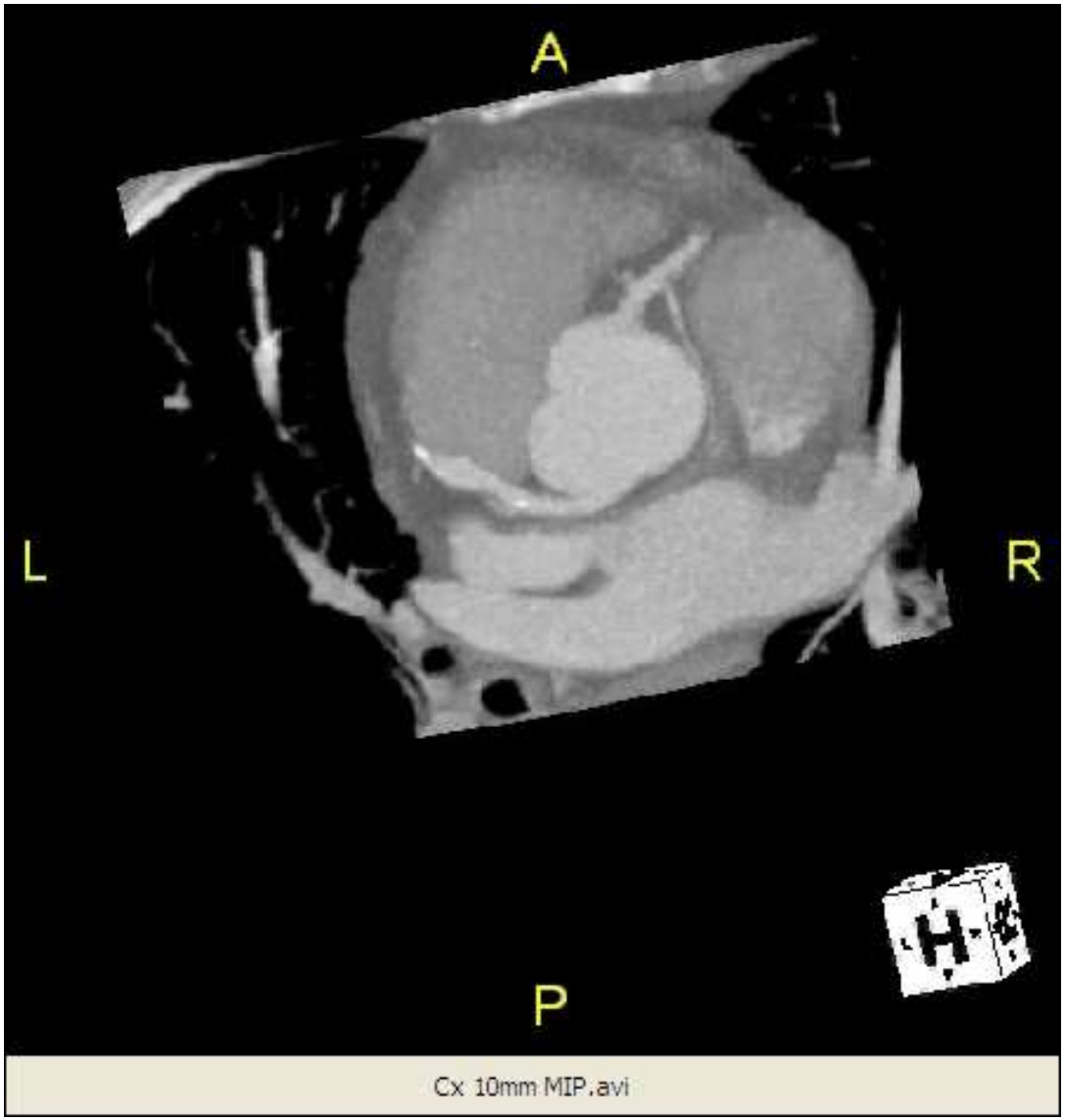

RCA MIP – 10mm

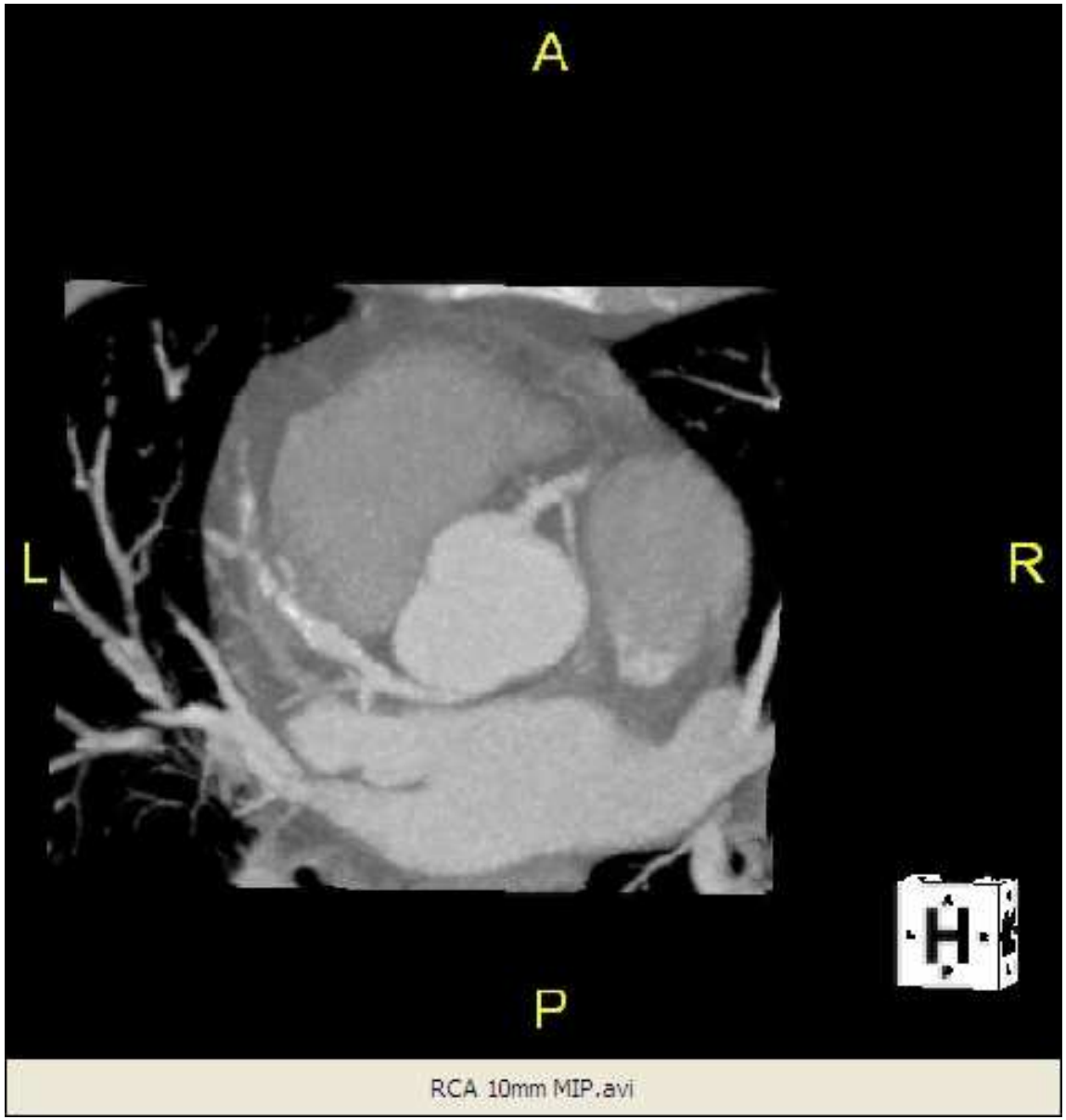

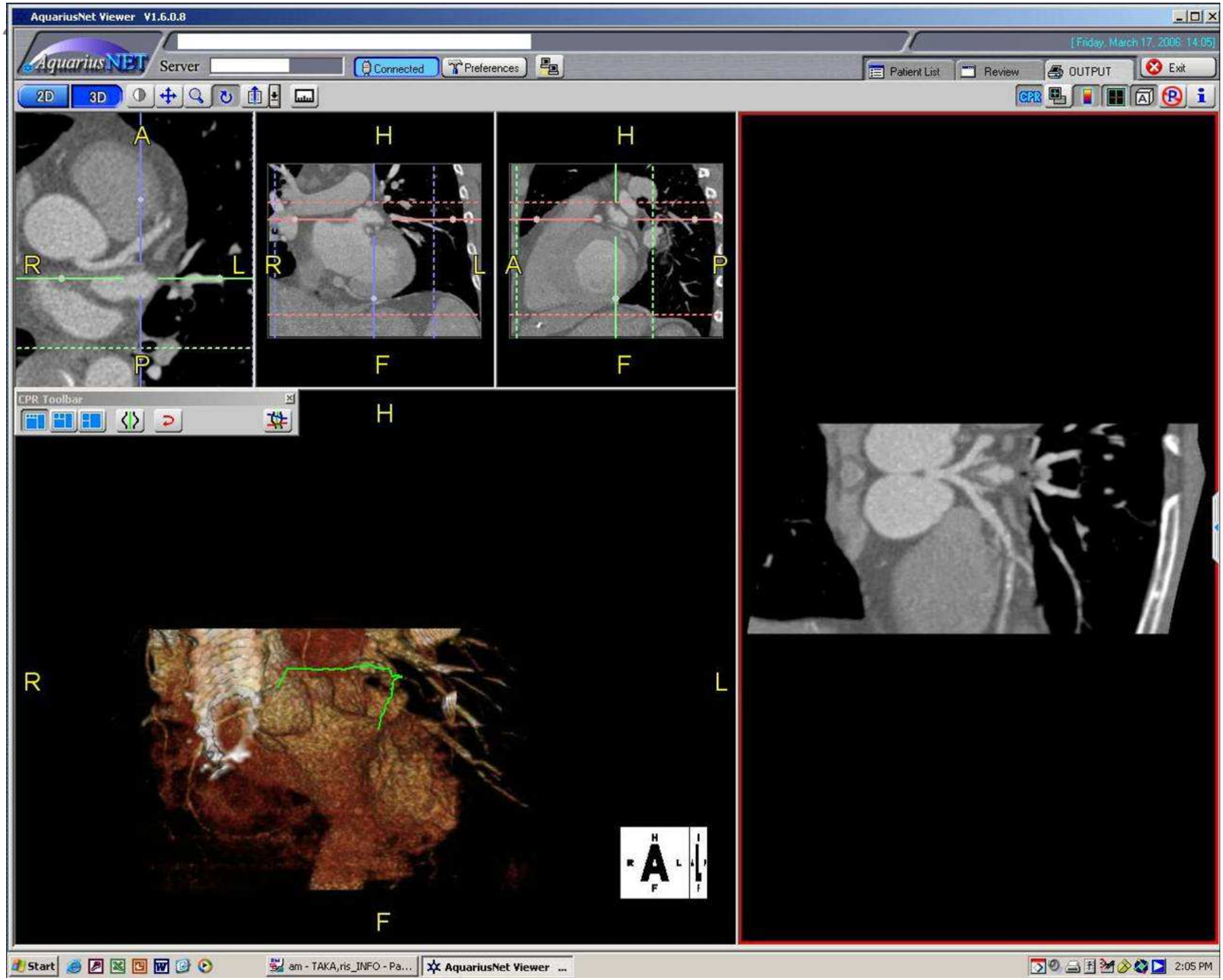
AquariusNet Viewer V1.6.0.8
AquariusNET
Server
Connected
Preferences
Patient List
Review
OUTPUT
Exit
2D
3D
CPR
CPR Toolbar
A
R
L
P
H
F
Start
AquariusNet Viewer
2:05 PM

MPR of Anuerysm
CPR of LAD

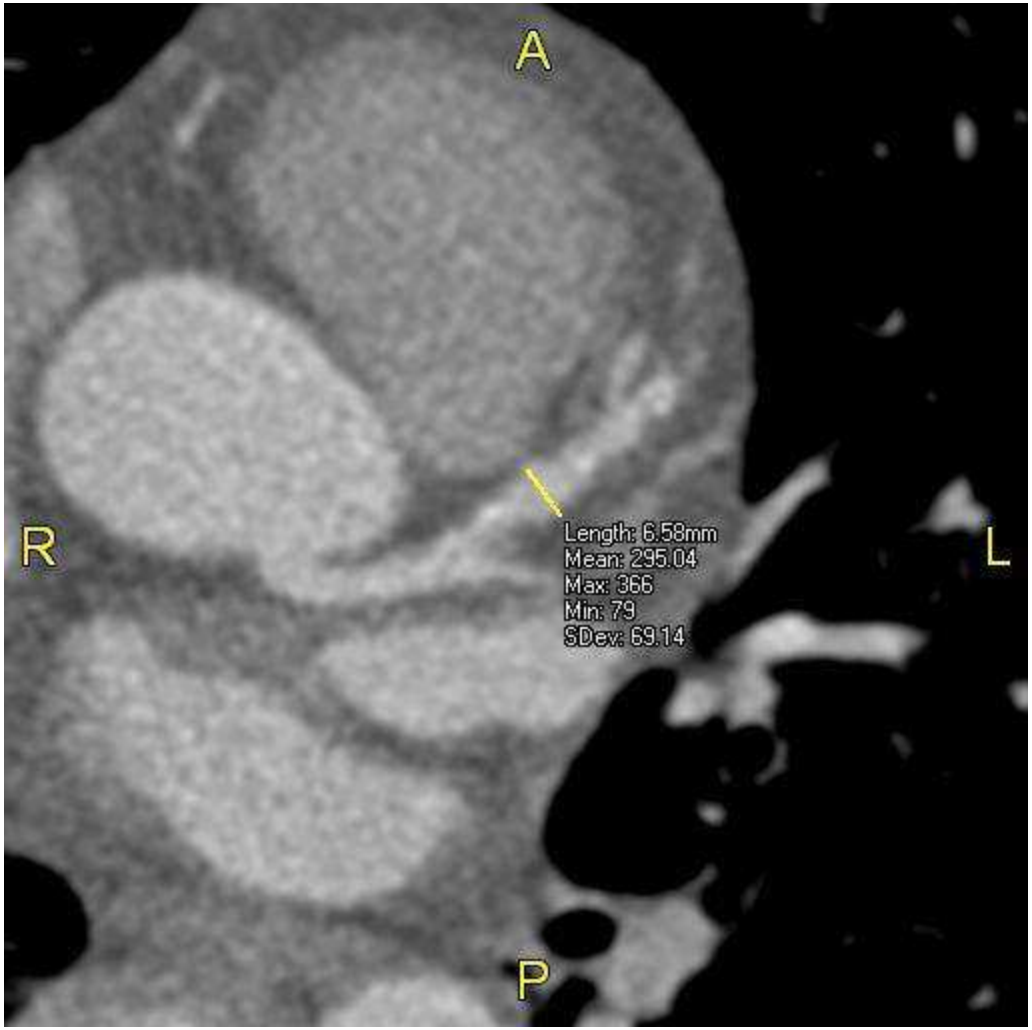

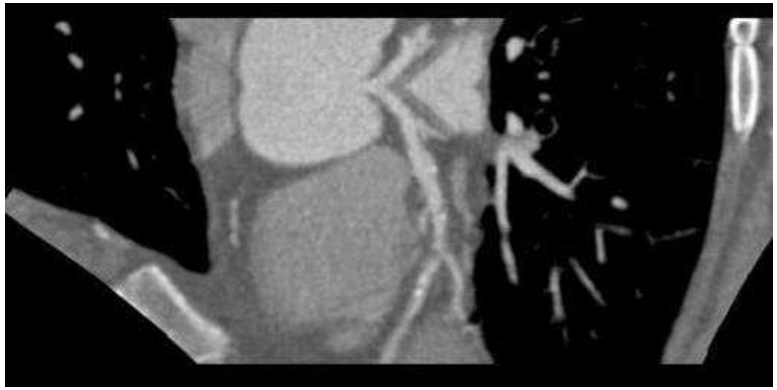


AquariusNet Viewer V1.6.0.8
AquariusNET
Server
Connected
Preferences
Patient List
Review
OUTPUT
Exit
2D
3D
CPR
A
R
L
P
H
F
3D
Angle
A P H F R L
5
Reset
Continue
Template
3D Settings
Slab
Mask
Light
Option
Auto
FreeROI
Free ROI
Cut
Keep
Smoothing
Clear Curve
Clear All ROI
Mask
Clear
Reverse
Undo
MPR
Abd1
Abd2
Head
Lung
Bone
Reset
Window Level
Position / Cine
RaySum
WW 715
WL 75
ColorTemplate
Invert
3D
MIP
3D
MIP
A Axial
S Sagittal
C Coronal
Start
AquariusNet Viewer
3:26 PM

VR heart from obese patient

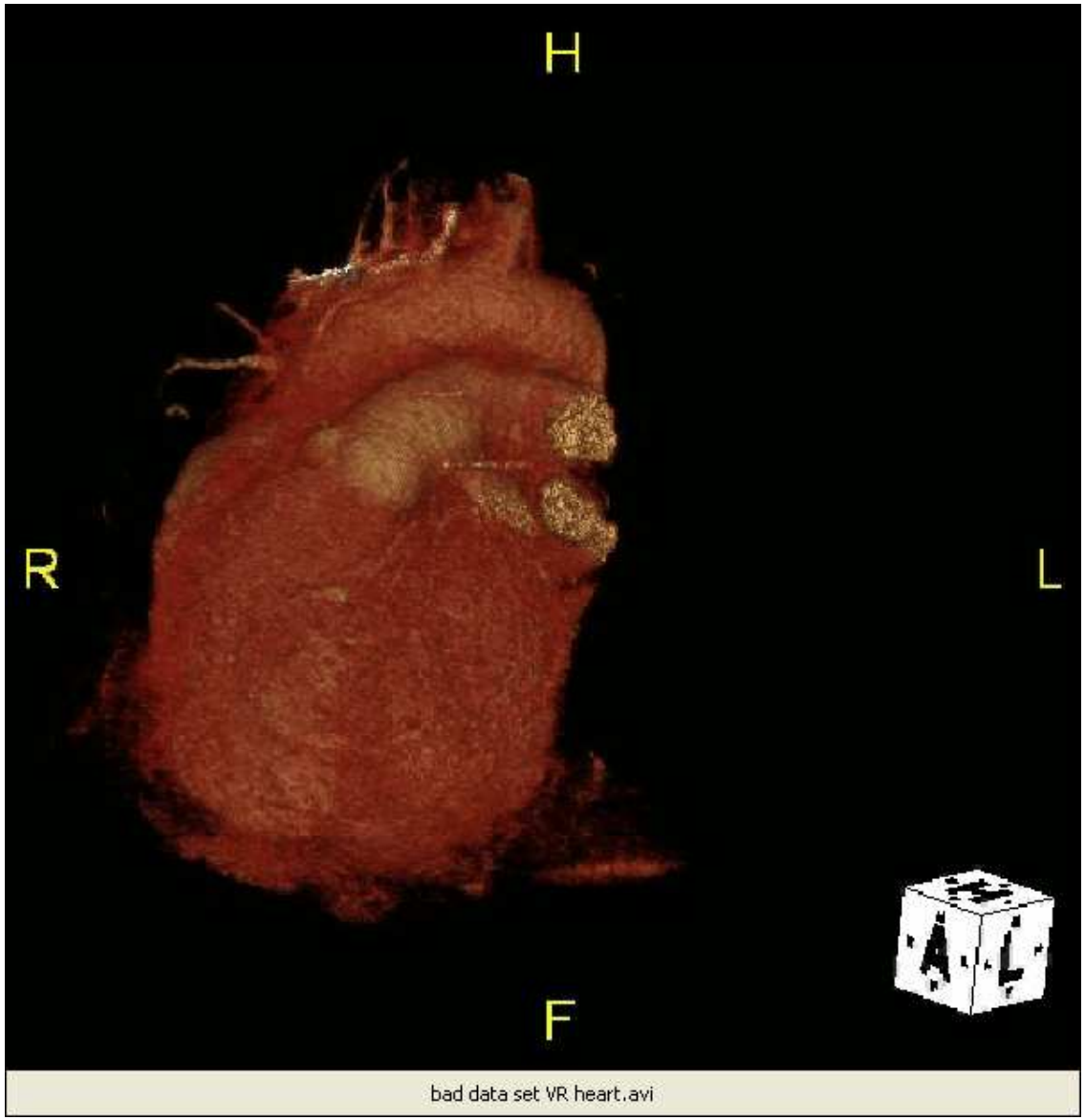

Next patient has grafts
Axial raw slices

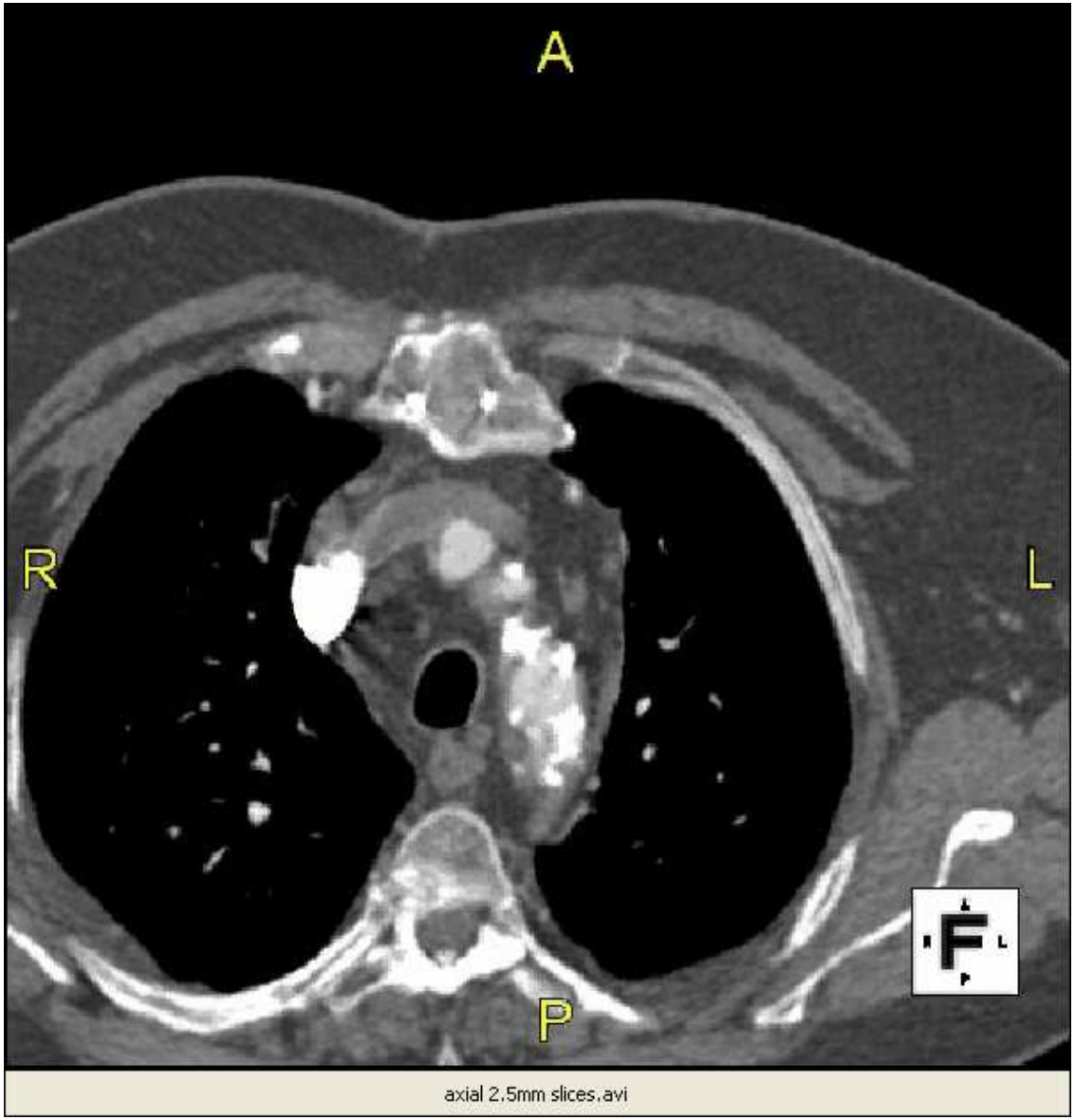

LAD and Cx MIP – 10mm

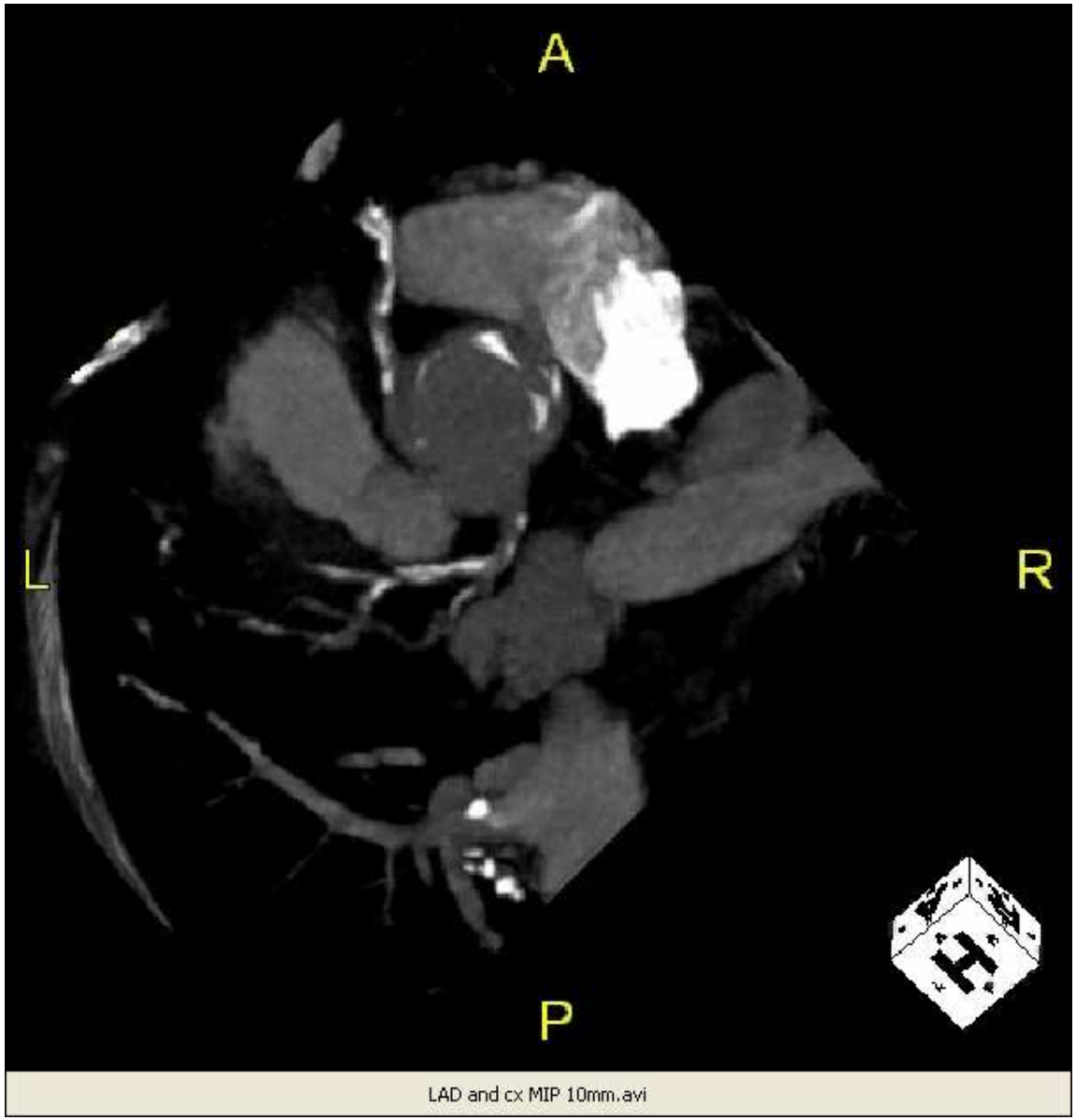

RCA MIP – 10mm

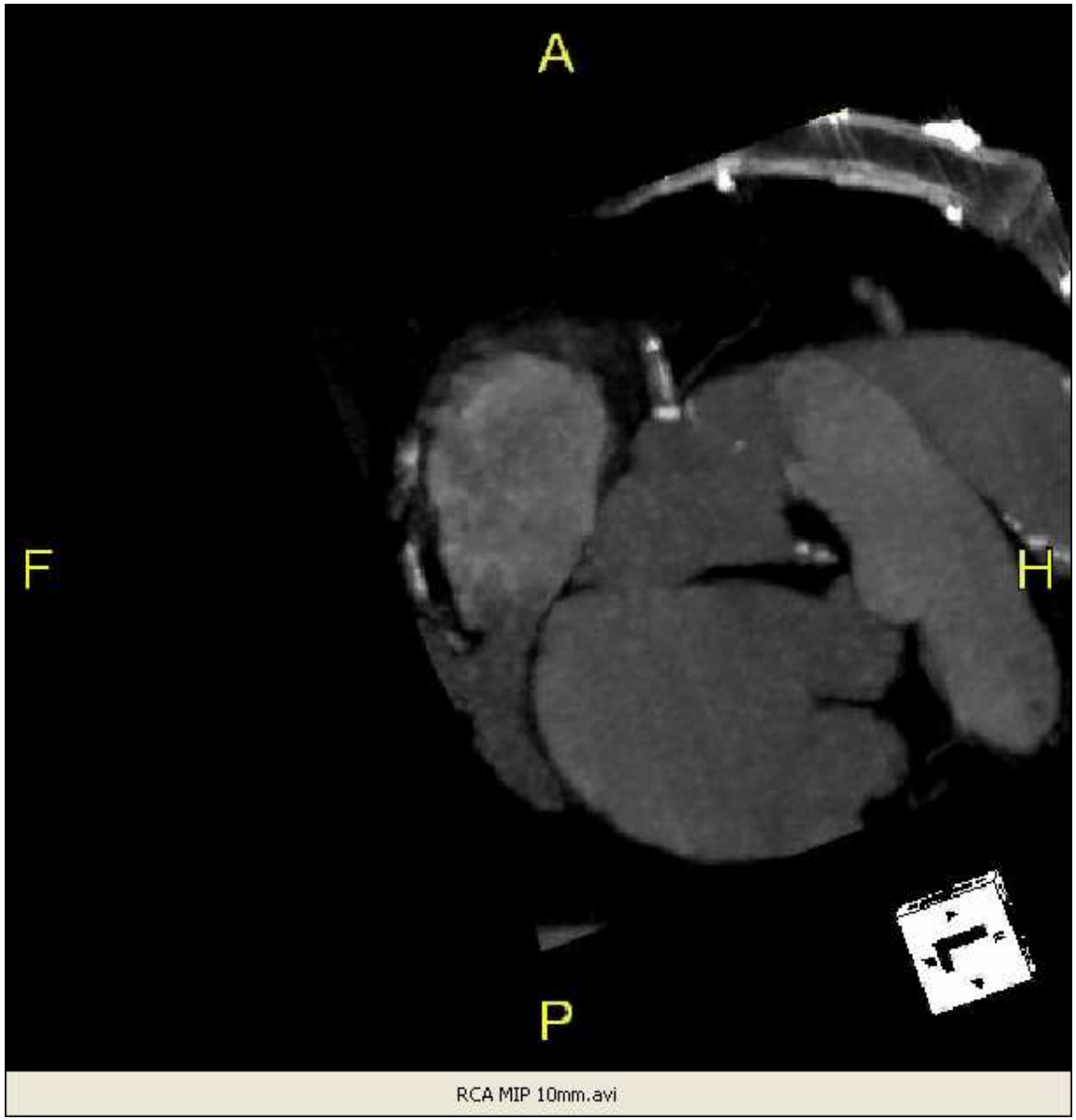

SVG-Dx MIP – 10mm

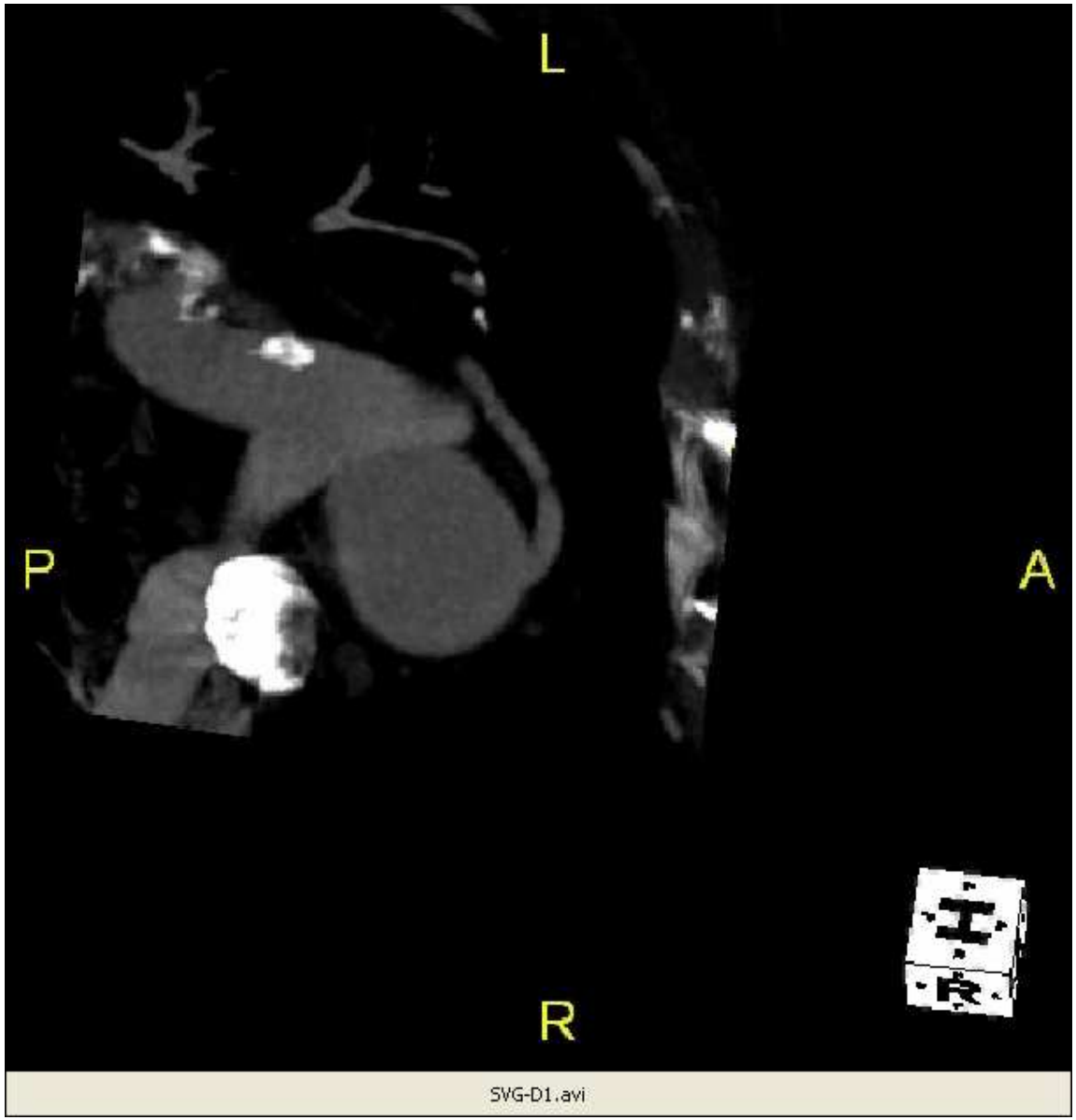

VR heart with grafts

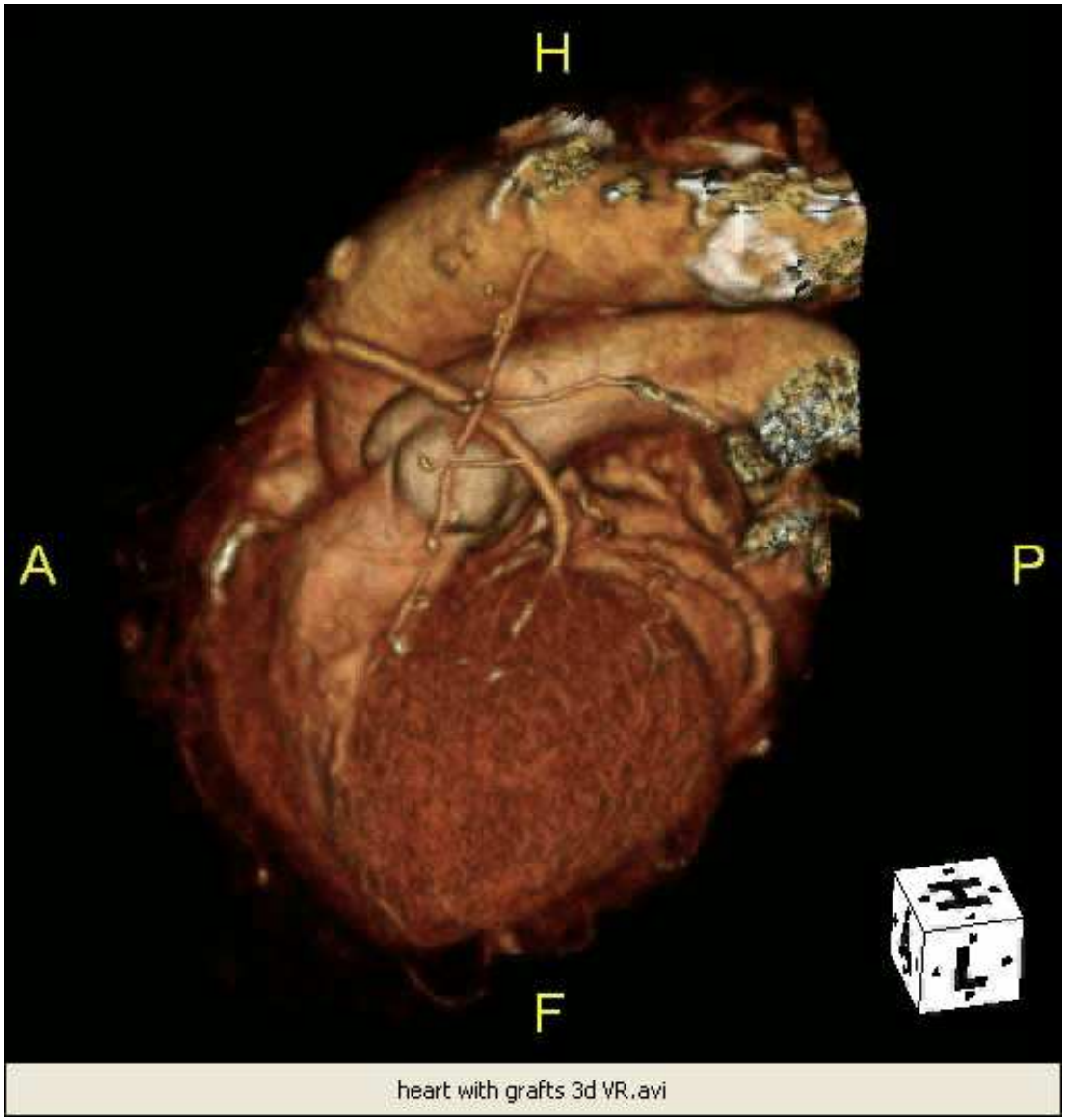

Next patient with Calcium in RCA and LAD

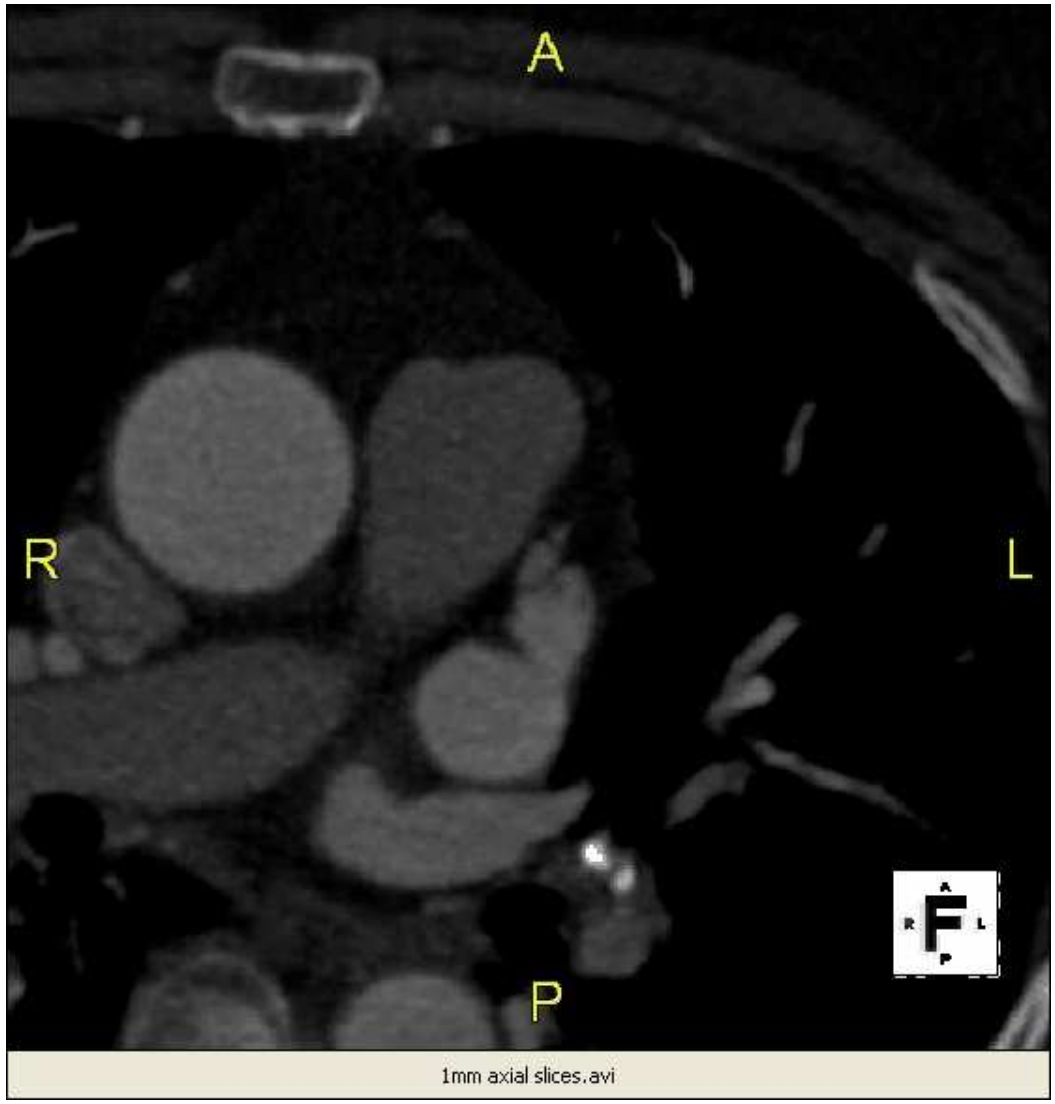

Left Coronary MIP – 10mm

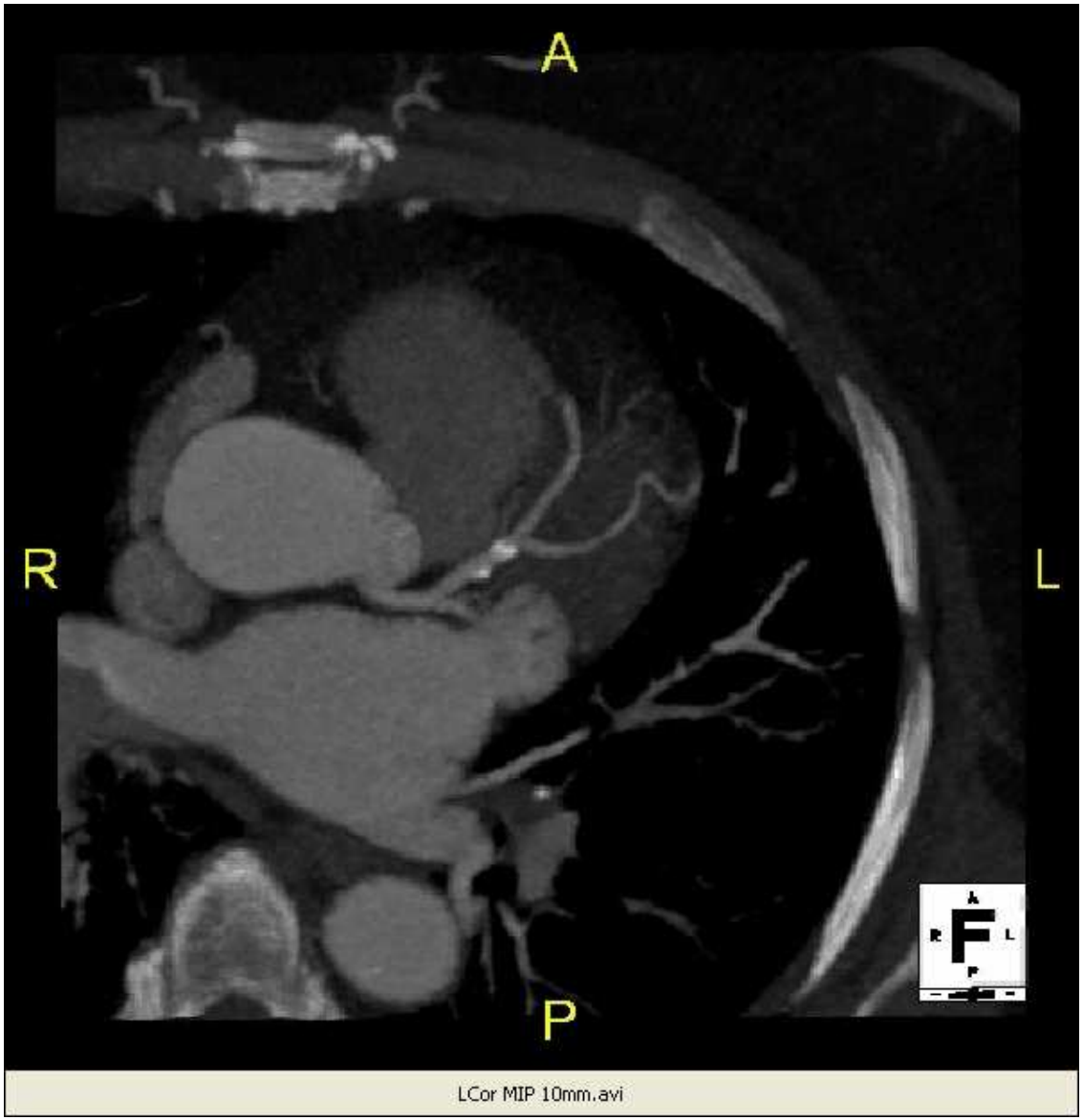

RCA MIP – 10mm

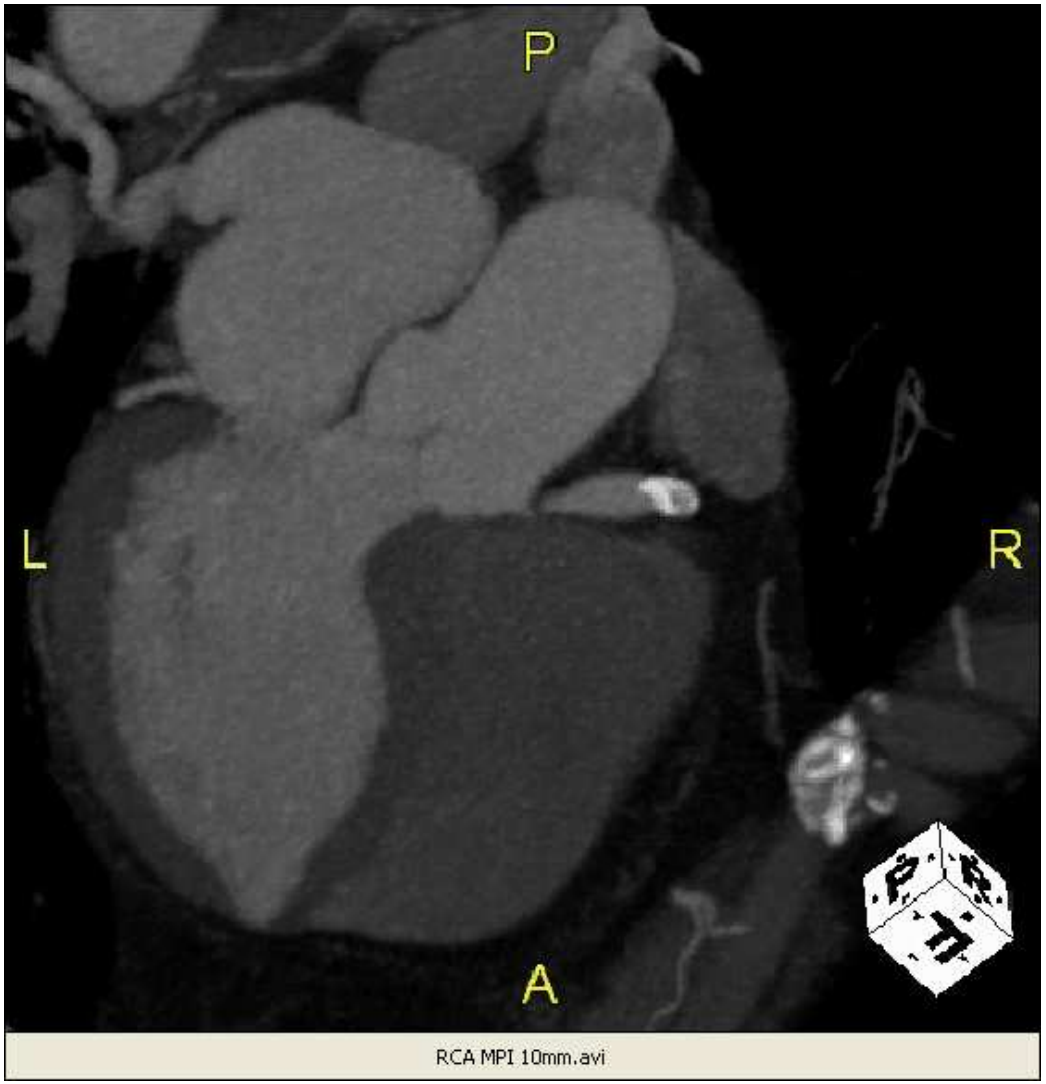

CPR RCA

VR Heart

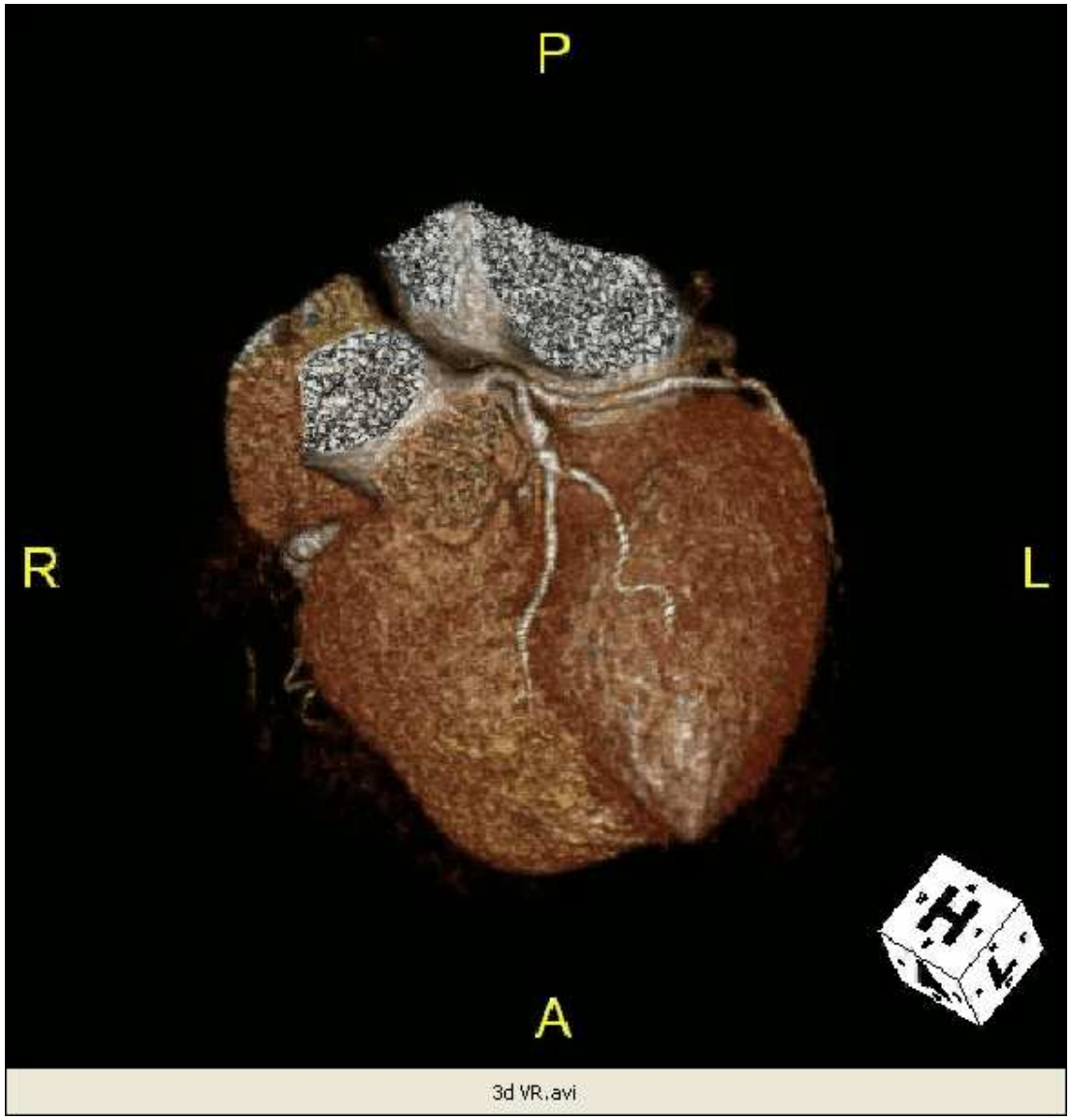

VR RCA Ostium

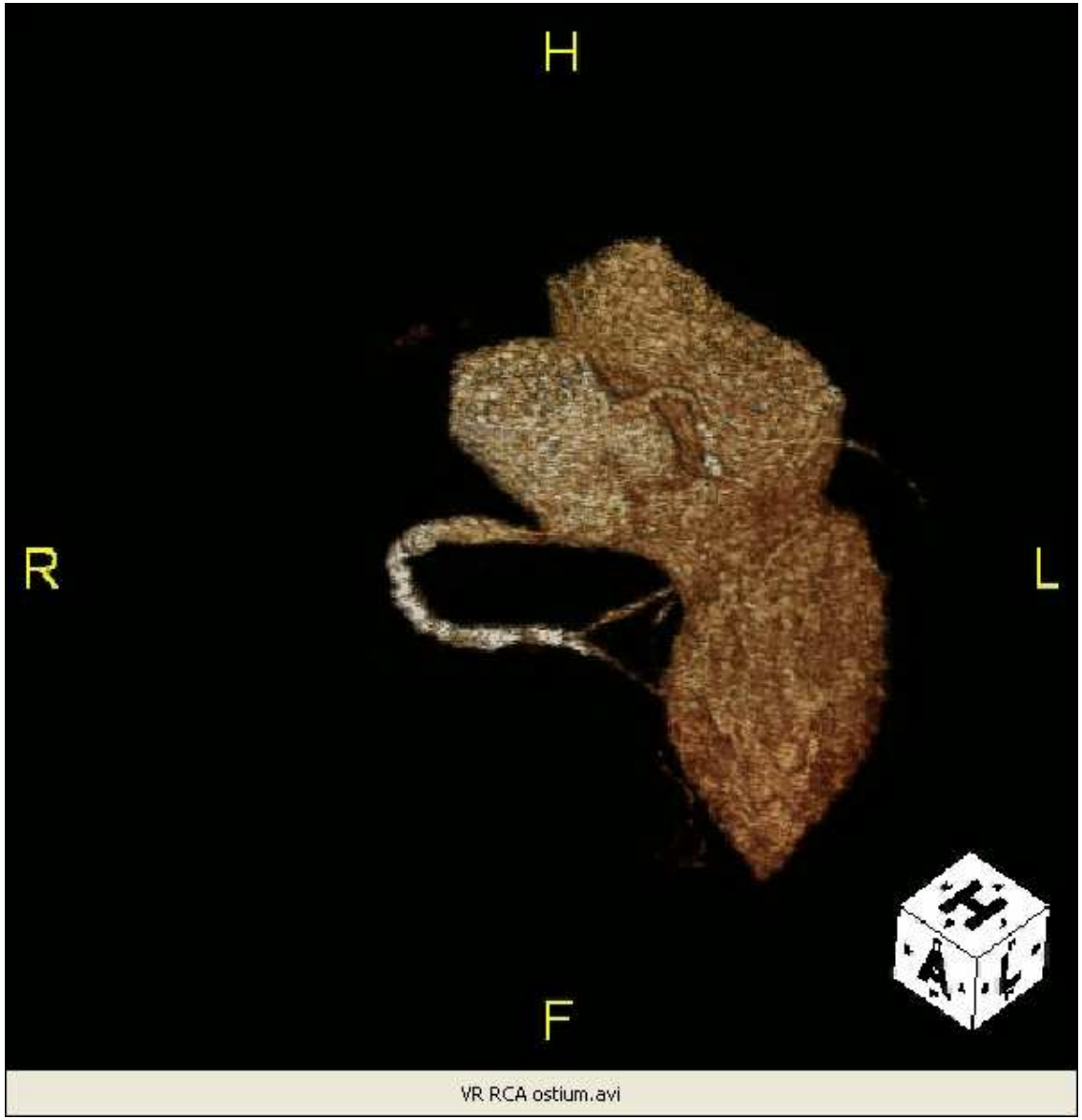

Aortic Arch Calcification

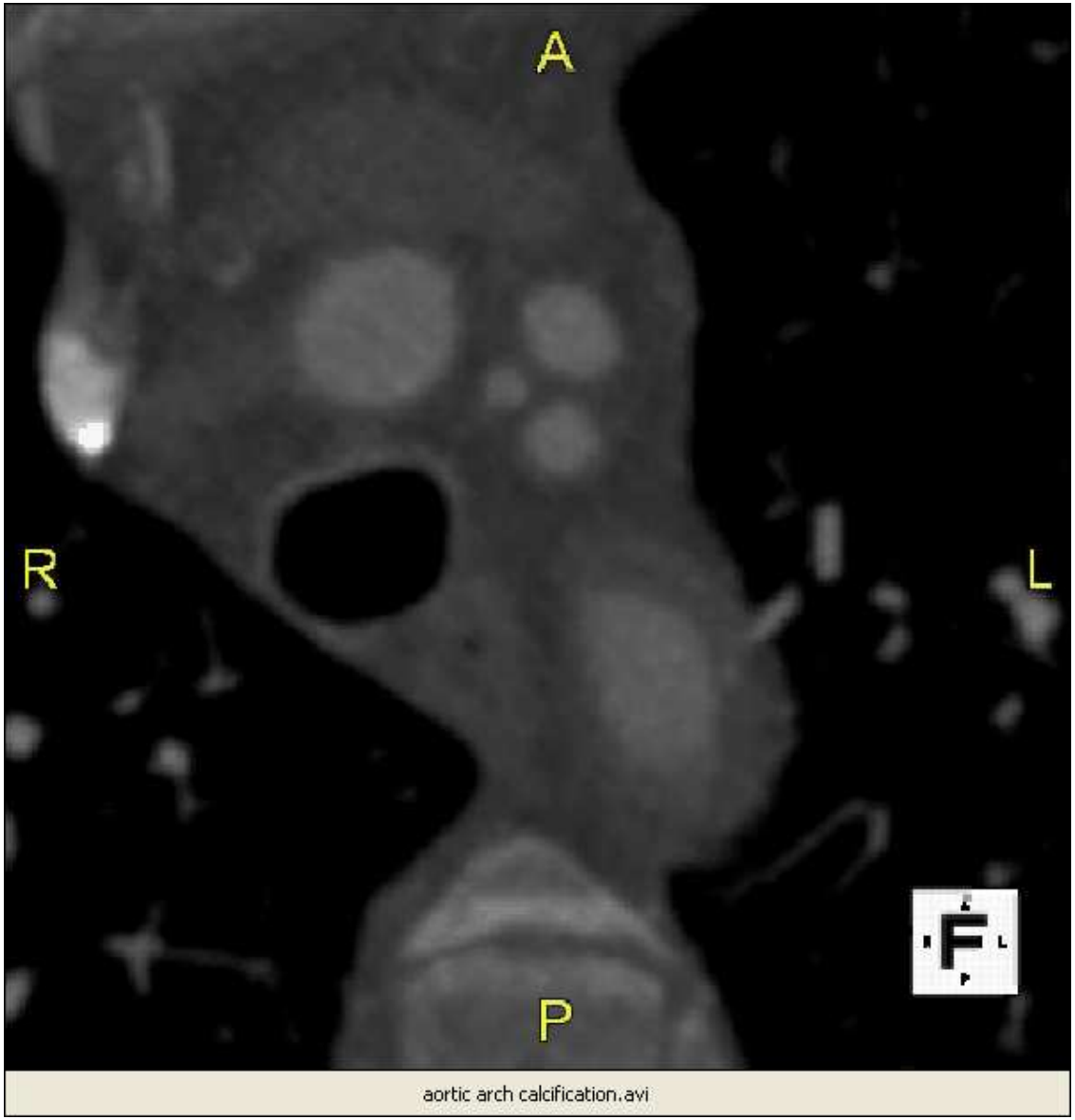

Mitral Valve Calcification

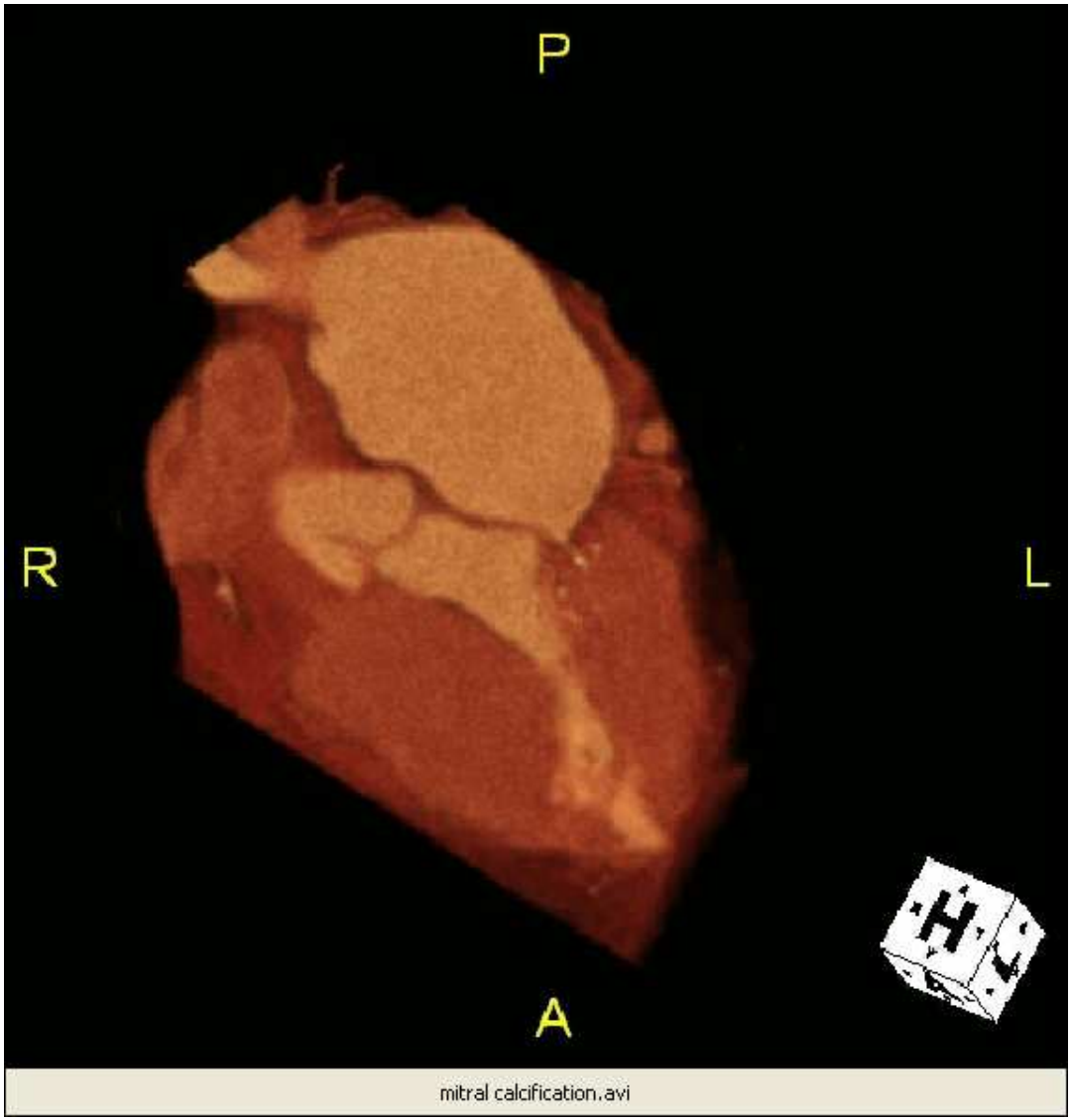

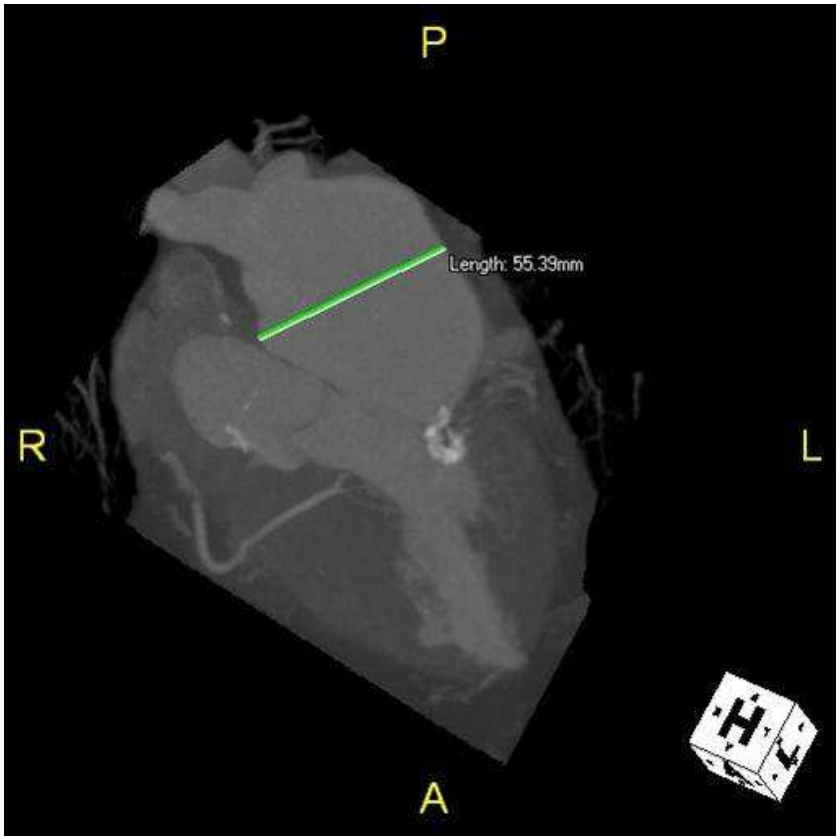

Left Main from Right coronary cusp

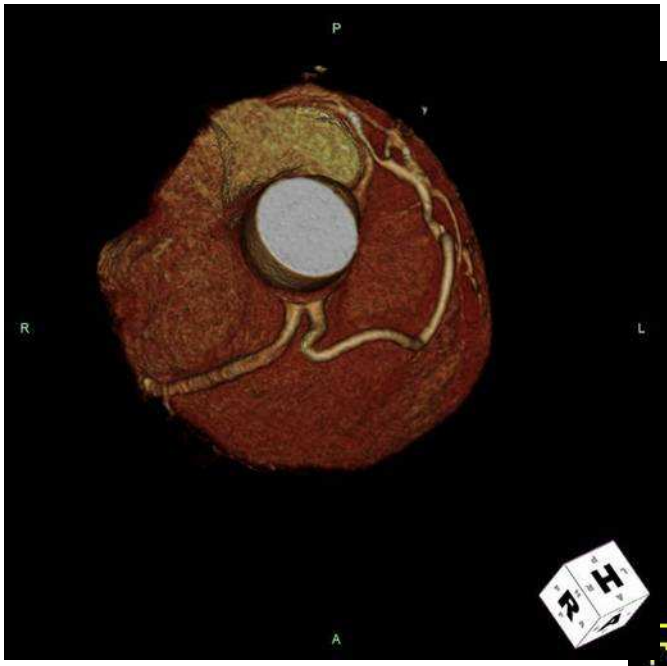

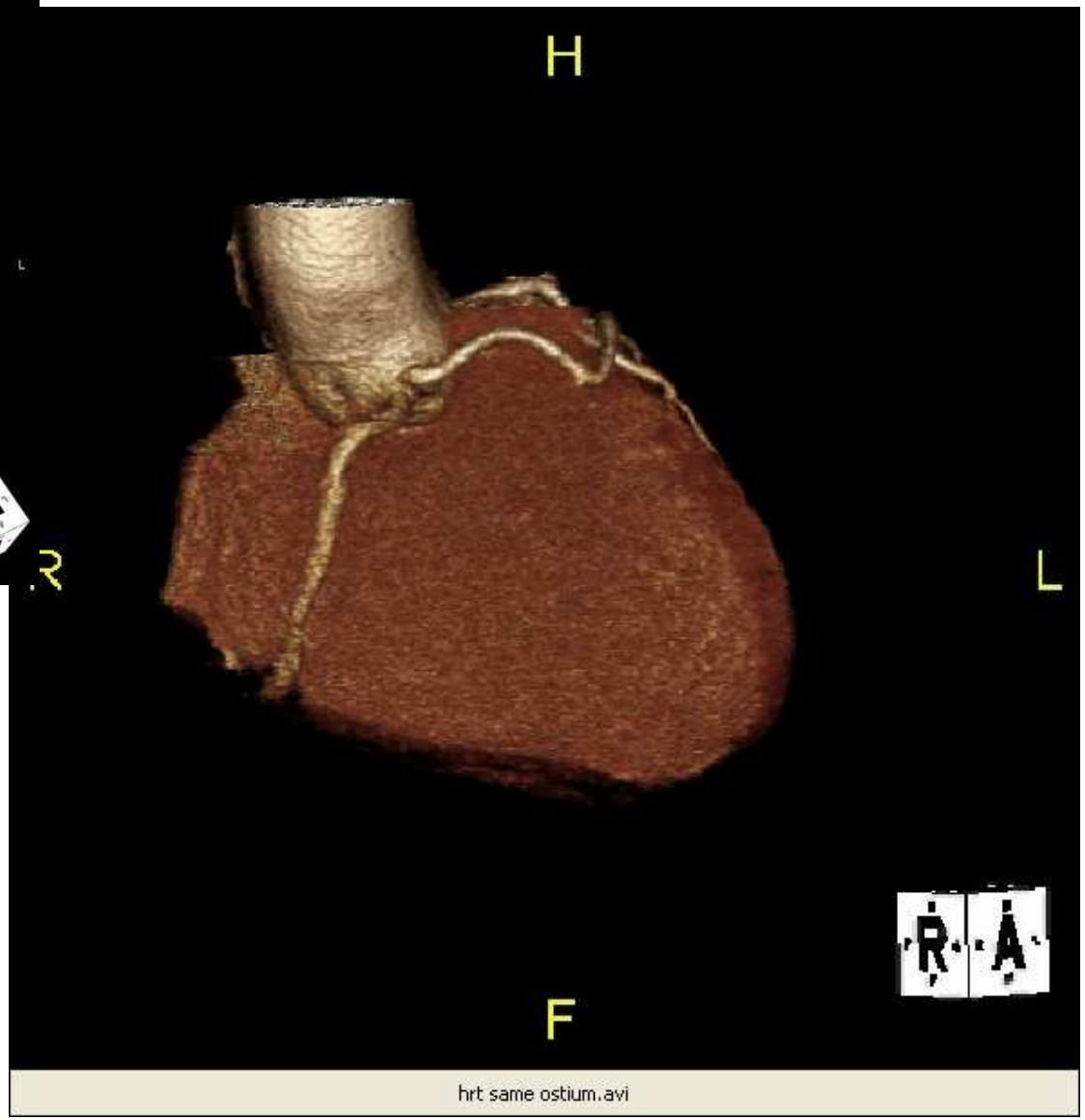

Courtesy Tom Kracus
Kettering Medical Center

RCA stenosis VR

Courtesy Tom Kracus
Kettering Medical Center

Left Circumflex graft VR

Courtesy Tom Kracus
Kettering Medical Center

Cardiac Mass

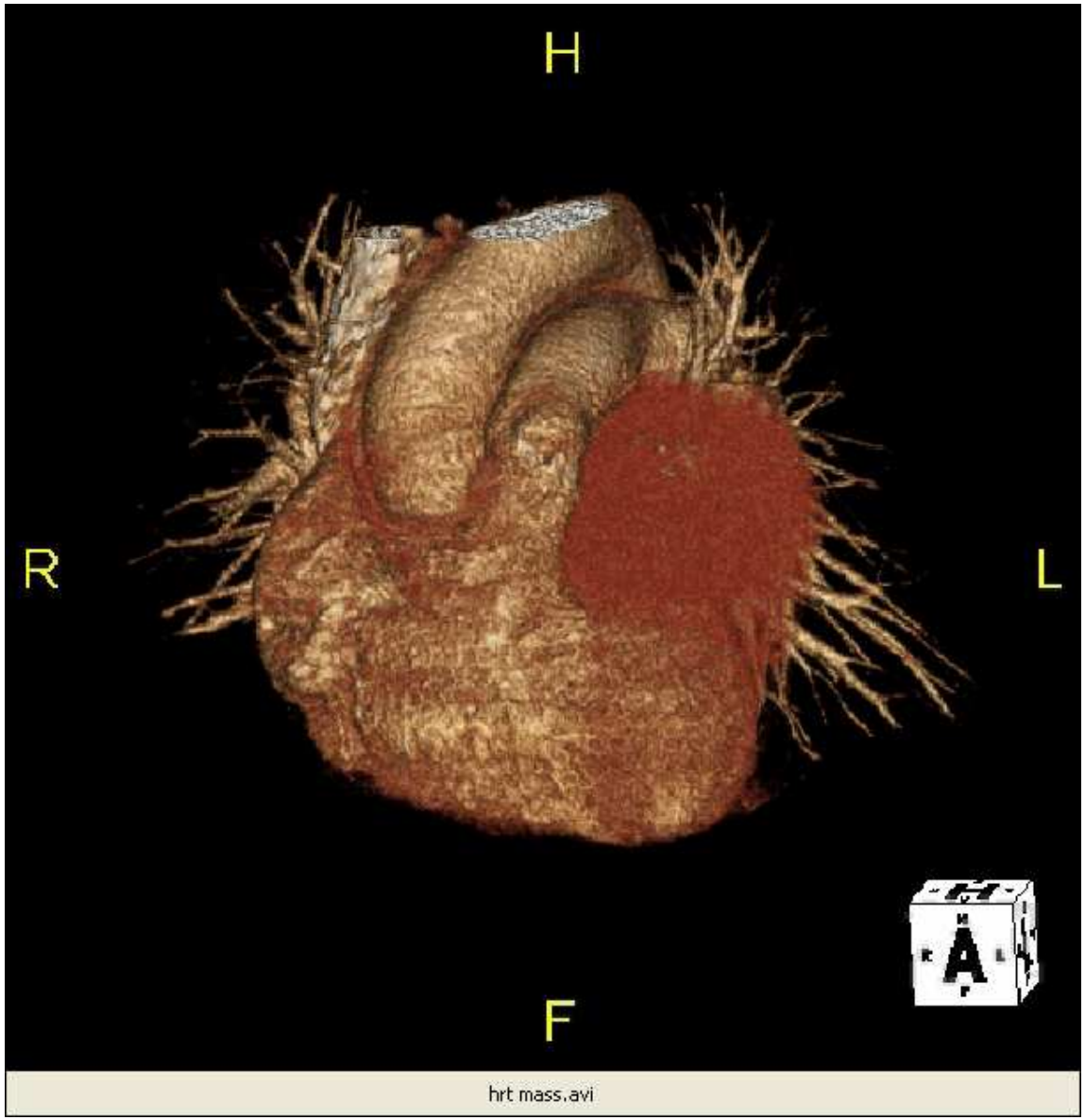

Courtesy Tom Kracus
Kettering Medical Center

References

- Mollet NR, Cademartiri F, van Mieghem CA, Runza G, McFadden EP, Baks T, Serruys PW, Krestin GP, de Feyter PJ. High-resolution spiral computed tomography coronary angiography in patients referred for diagnostic conventional coronary angiography. Circulation. 2005 Oct 11;112(15):2318-23. Epub 2005 Oct 3.
- Schoenhagen P. Atlas and Manual of Cardiovascular Multidetector Computed Tomography. Taylor & Francis: 2005.