# Aortic Valve Disease

## Illustrative Cases

December 8, 2009

David Stultz, MD, FACC
Southwest Cardiology, Inc

Handout available at http://www.drstultz.com

# Disclosures

- Nothing to disclose

# Objectives

- Understand the use of echocardiography to assess aortic valve disease
- Apply clinical guidelines to management of aortic valve disease

# Aortic Valve Anatomy

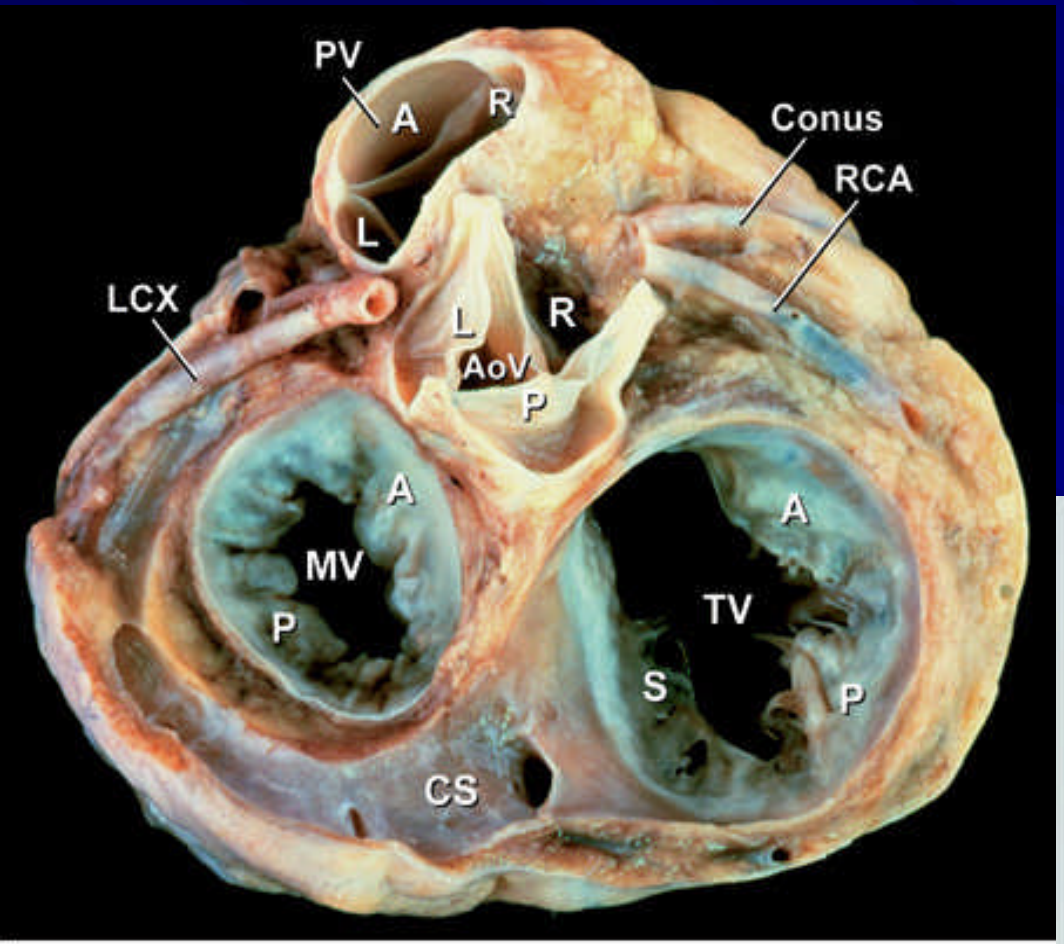


A

Source: Fuster V, O'Rourke RA, Walsh RA, Poole-Wilson
P: *Hurst's The Heart*, 12th Edition: http://www.accessmedicine.com



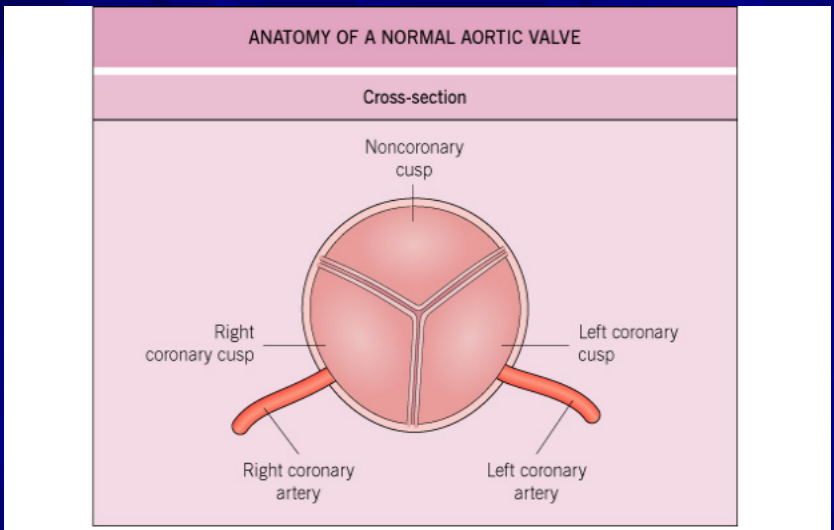




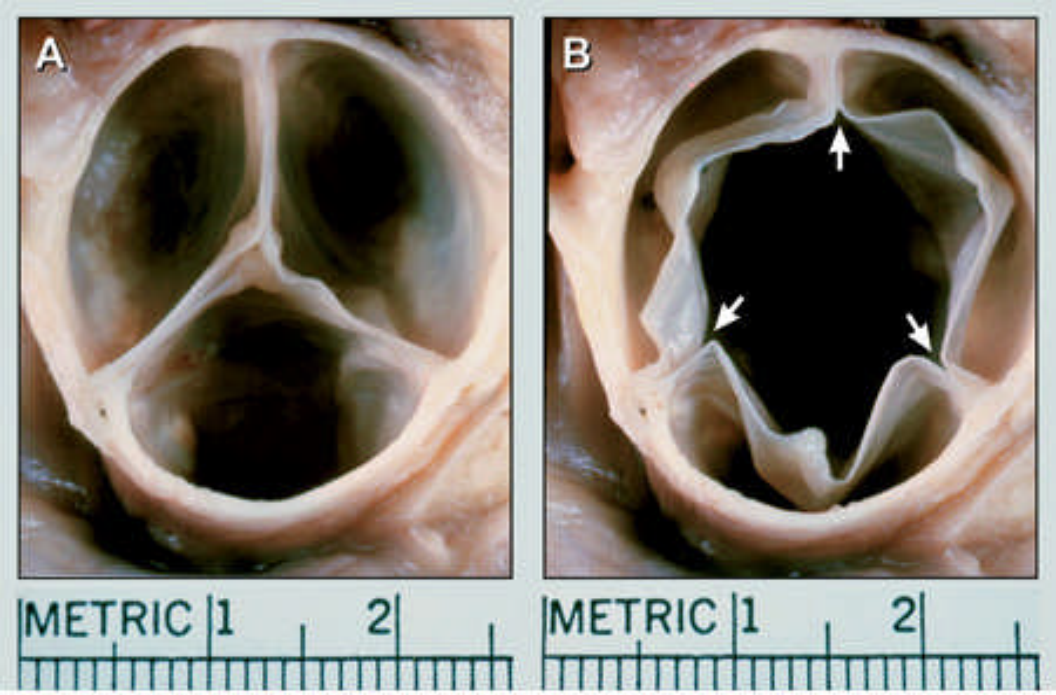


Source: Fuster V, O'Rourke RA, Walsh RA, Poole-Wilson
P: *Hurst's The Heart*, 12th Edition: http://www.accessmedicine.com



Hurst 12th ed.

# Selected Abnormalities of Aortic Valve

- Aortic Stenosis
  - Narrowing of the valve orifice
- Aortic Regurgitation
  - Incompetence of the valve
  - Blood “leaks” from aorta to left ventricle in ventricular diastole
- Bicuspid Aortic Valve
- Endocarditis

# How to Assess the Aortic Valve

- Clinical History
- Physical Examination
- Echocardiography
  - Transthoracic
  - Transesophageal
- Angiography
- Cardiac CT (not regurgitation, though)
- MRI

# Why do aortic valves become stenotic?

- Valvular Stenosis
  - Bicuspid valve with calcification
  - Age-related calcific aortic stenosis
  - Rheumatic
  - Rare causes: Congenital, Rheumatoid, Severe atherosclerosis (Hyperlipidemia), alkaptonuria
- Supravalvular Stenosis
- Subvalvular Stenosis
  - Discrete
  - Hypertrophic Cardiomyopathy

Braunwald 8th ed.

Normal aortic valve

Bicuspid aortic stenosis

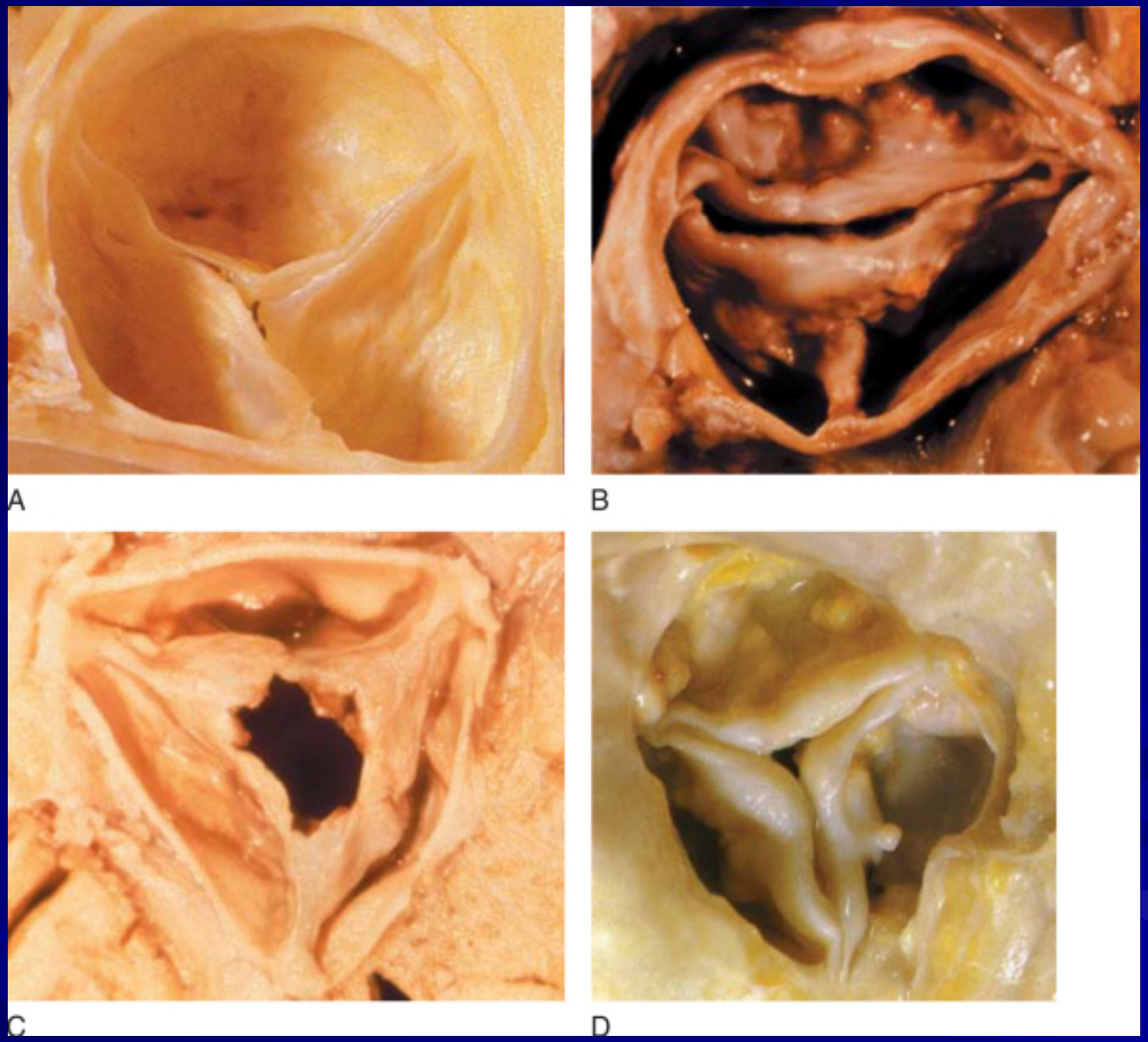


Rheumatic aortic stenosis

Age related aortic stenosis

Braunwald 8th ed.

# Normal trileaflet aortic valve echo

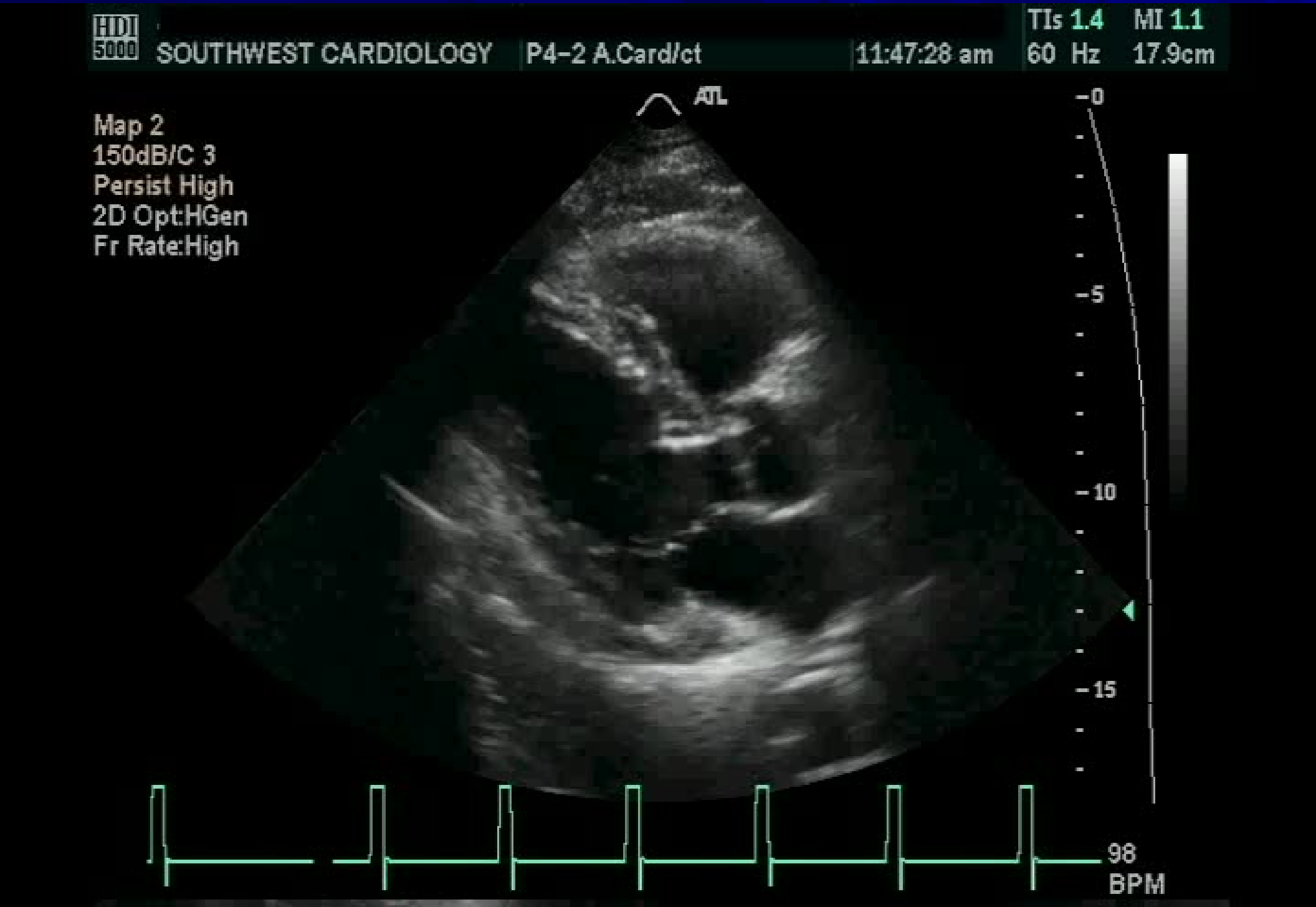

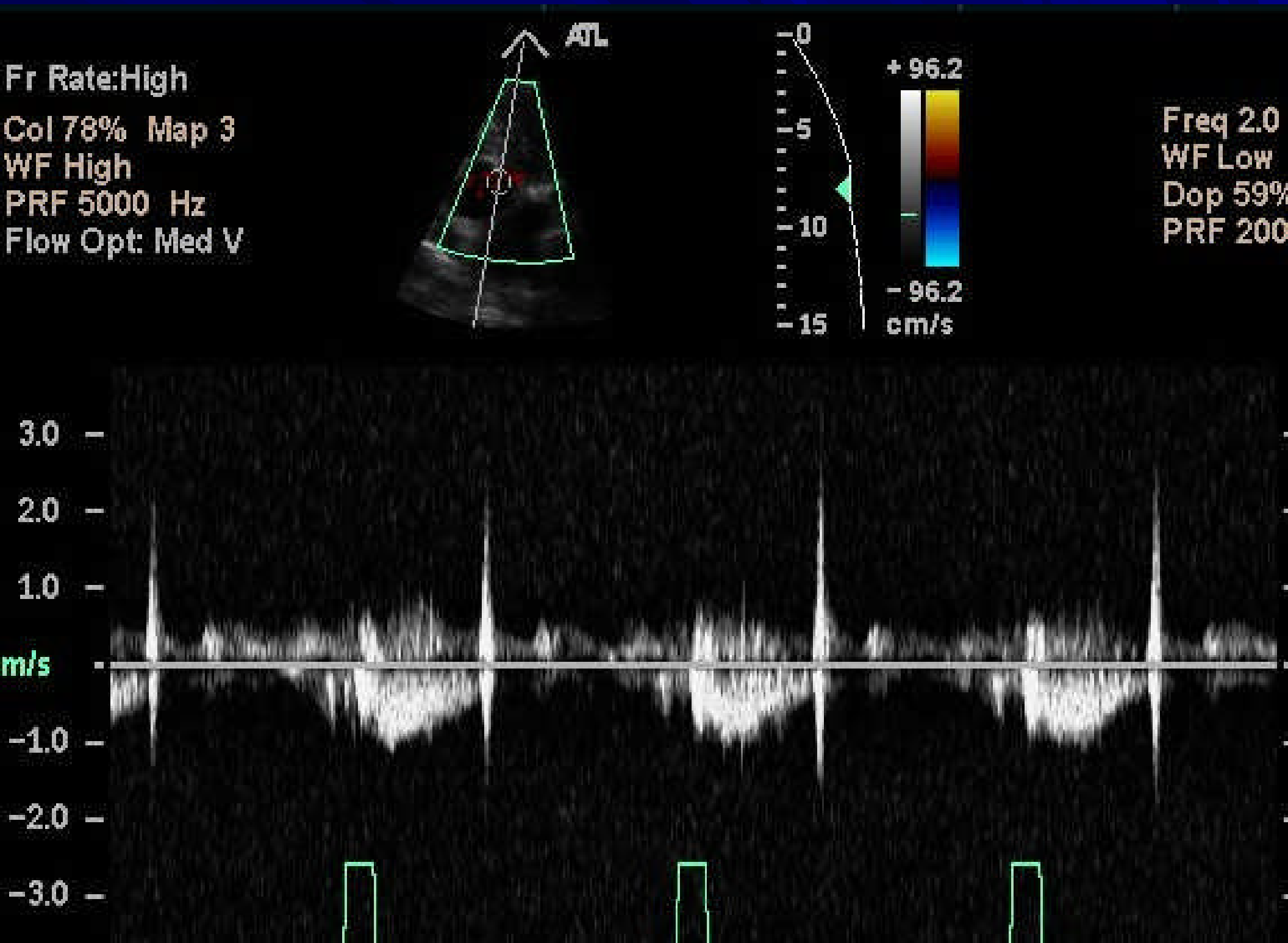

# How to assess aortic stenosis by echo

- 2-D echo
  - Planimetry – measure the valve orifice
- Doppler Hemodynamics
  - Continuity equation
  - Peak/Mean pressure gradient

# Planimetry

Transthoracic

Transesophageal


Technically difficult, may overestimate valve area

# Echo Doppler

- Echo probe generates sound wave
- Sound wave reflects off tissue/blood
- Echo probe has a time window to listen for these reflections
- Moving targets (blood) will create a frequency shift in the sound wave
- This frequency shift can be translated into a velocity
- Can measure the velocity of blood flow

# Continuity equation



- Without a nozzle, the water velocity inside the hose (1/2”) is the same as after the hose

# Continuity equation

- With a nozzle, the water velocity inside the hose (1/2”) is lower than after the nozzle
- Nozzle reduces the orifice area

- Know diameter of hose (1/2”)
- Can measure velocity of water in the hose
- Can measure the velocity of water after the nozzle
- What is the effective orifice created by the nozzle?

# Continuity equation

- Conservation of mass
- Flow before nozzle = Flow after nozzle
- Area of hose * velocity of water in hose = Orifice area * velocity of water after hose
  - Area = $(\frac{1}{2} * \text{diameter})^2 * 3.14(\pi)$
- Can solve equation for orifice area

# Continuity equation

- Now think of the aortic valve
- Can measure LVOT diameter
- Can measure LVOT velocity (or TVI)
- Can measure velocity (or TVI) after aortic valve

- Can solve for aortic valve orifice
- Simplified Bernoulli equation
  - $4v^2$ = mmHg pressure gradient

## DETERMINING THE STENOTIC AREA BY THE CONTINUITY EQUATION

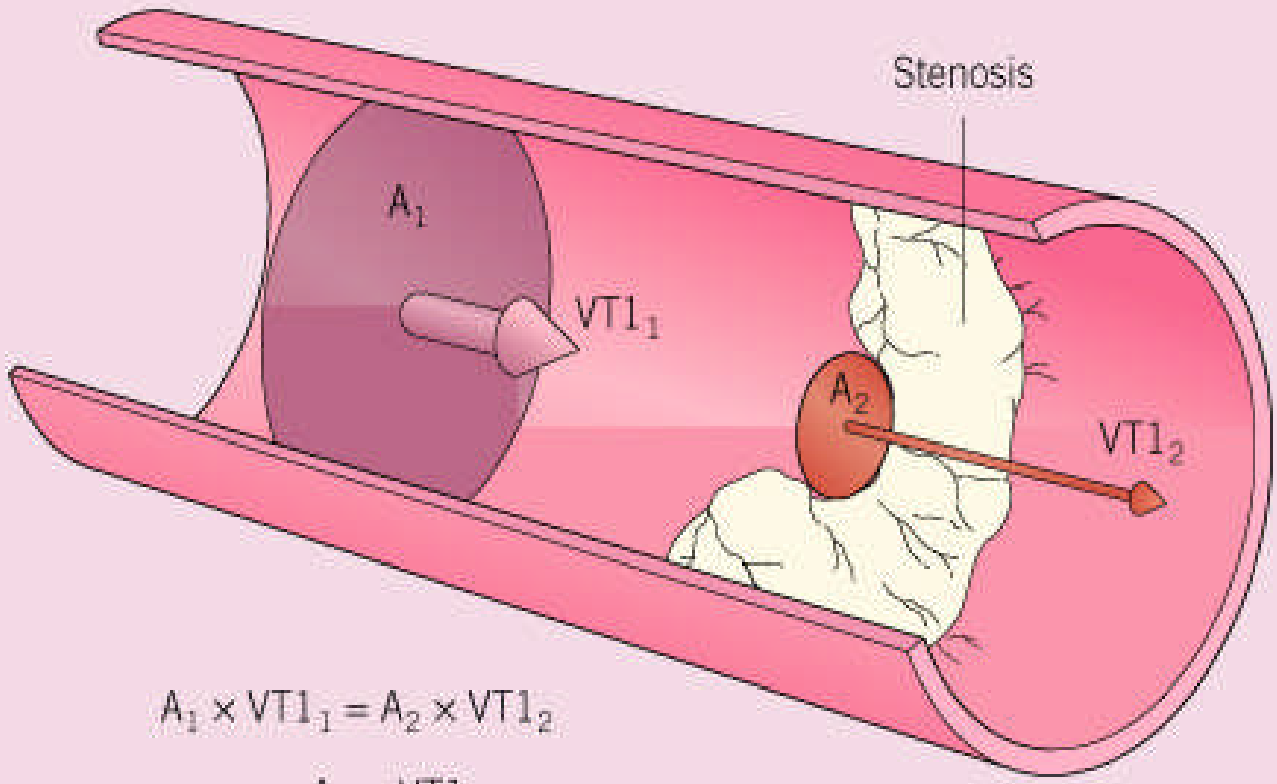


$$A_1 \times VTI_1 = A_2 \times VTI_2$$

$$\therefore A_2 = \frac{A_1 \times VTI_1}{VTI_2}$$

# Case 1

- 77 year old African American Male
- Referred for evaluation of murmur
- Medical history: HTN
- Asymptomatic, able to walk up and down stairs, shovel snow
- BP 146/86
- Crescendo/Descrescendo 3/6 systolic murmur at left lower sternal border

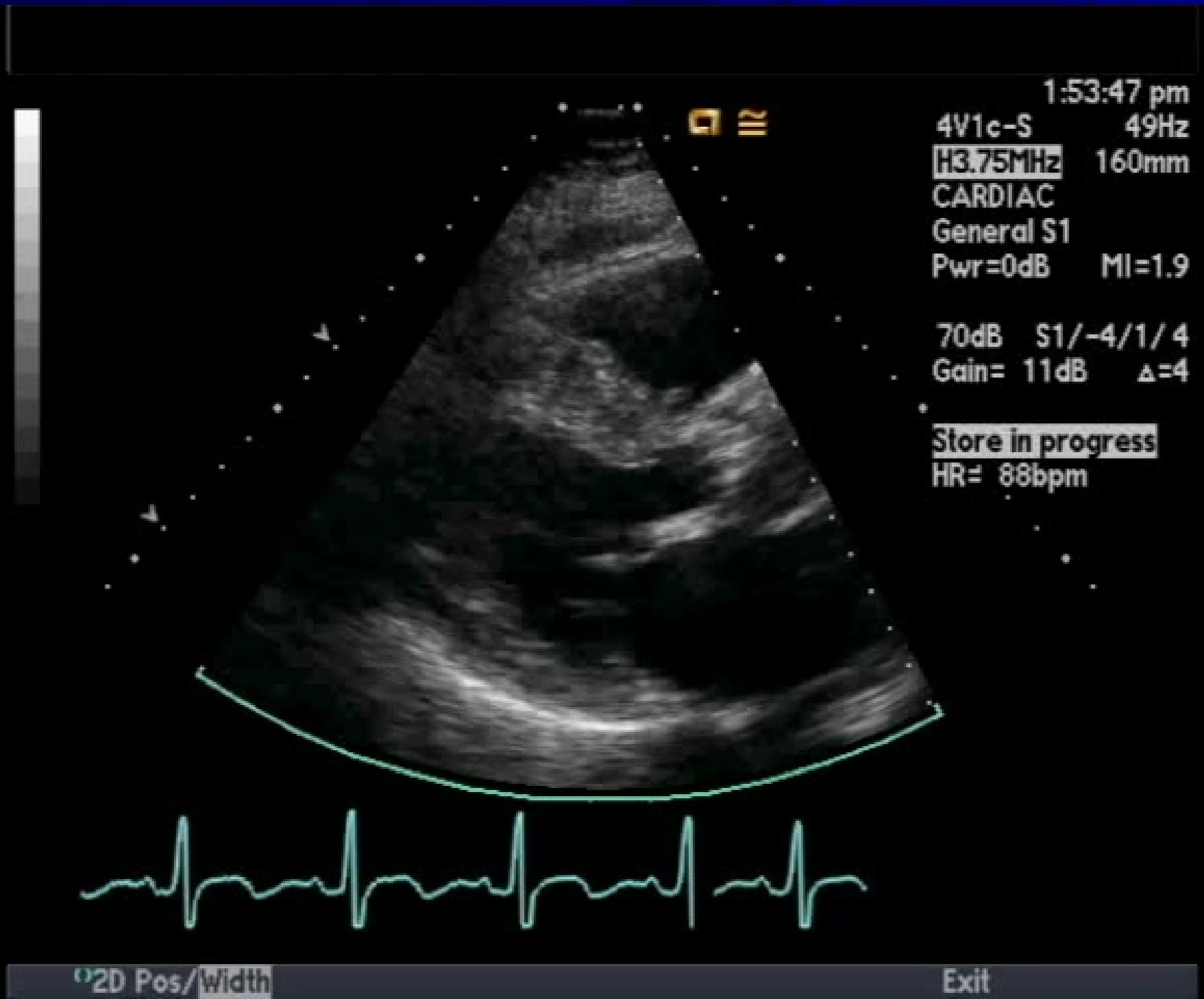

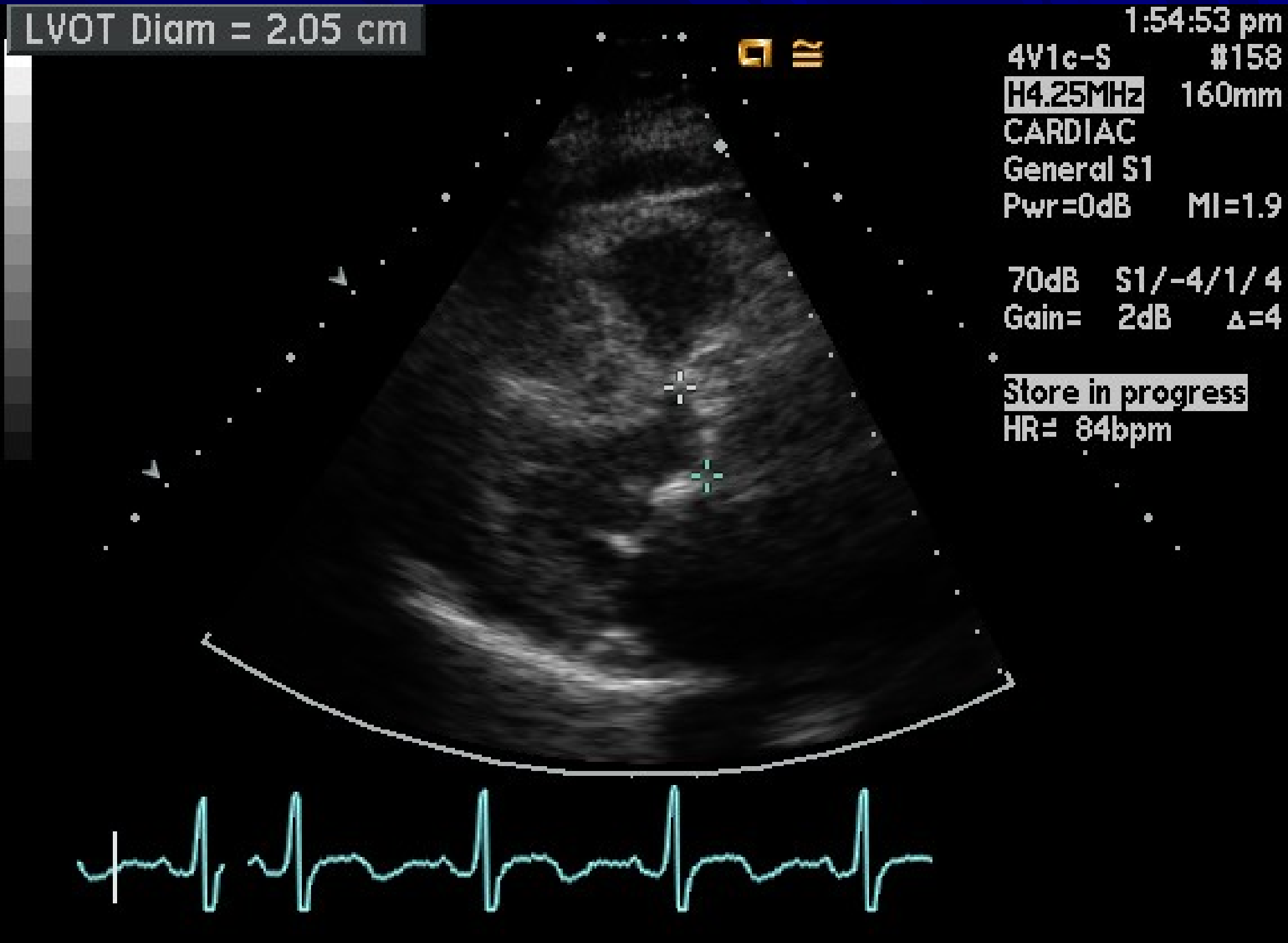

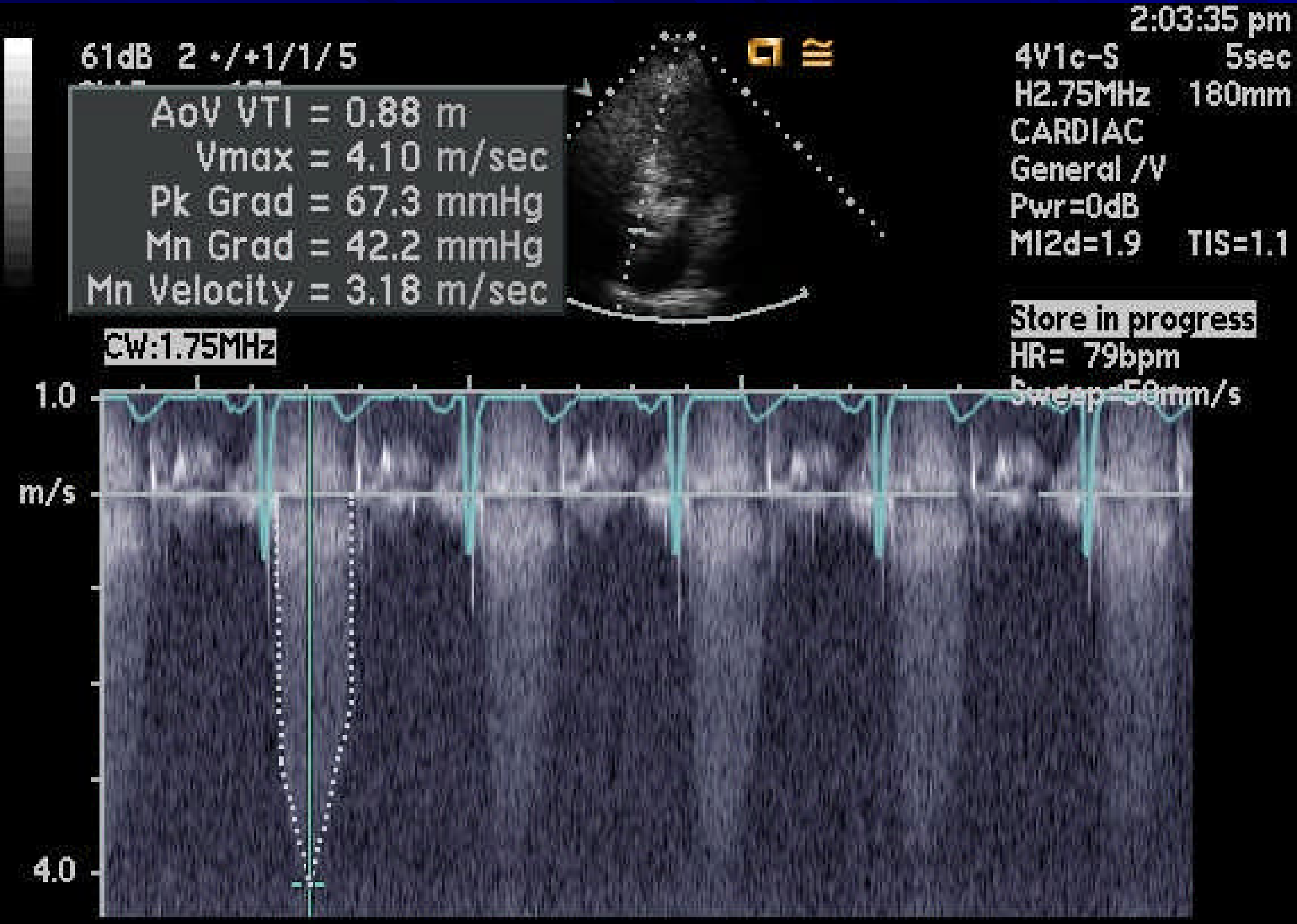

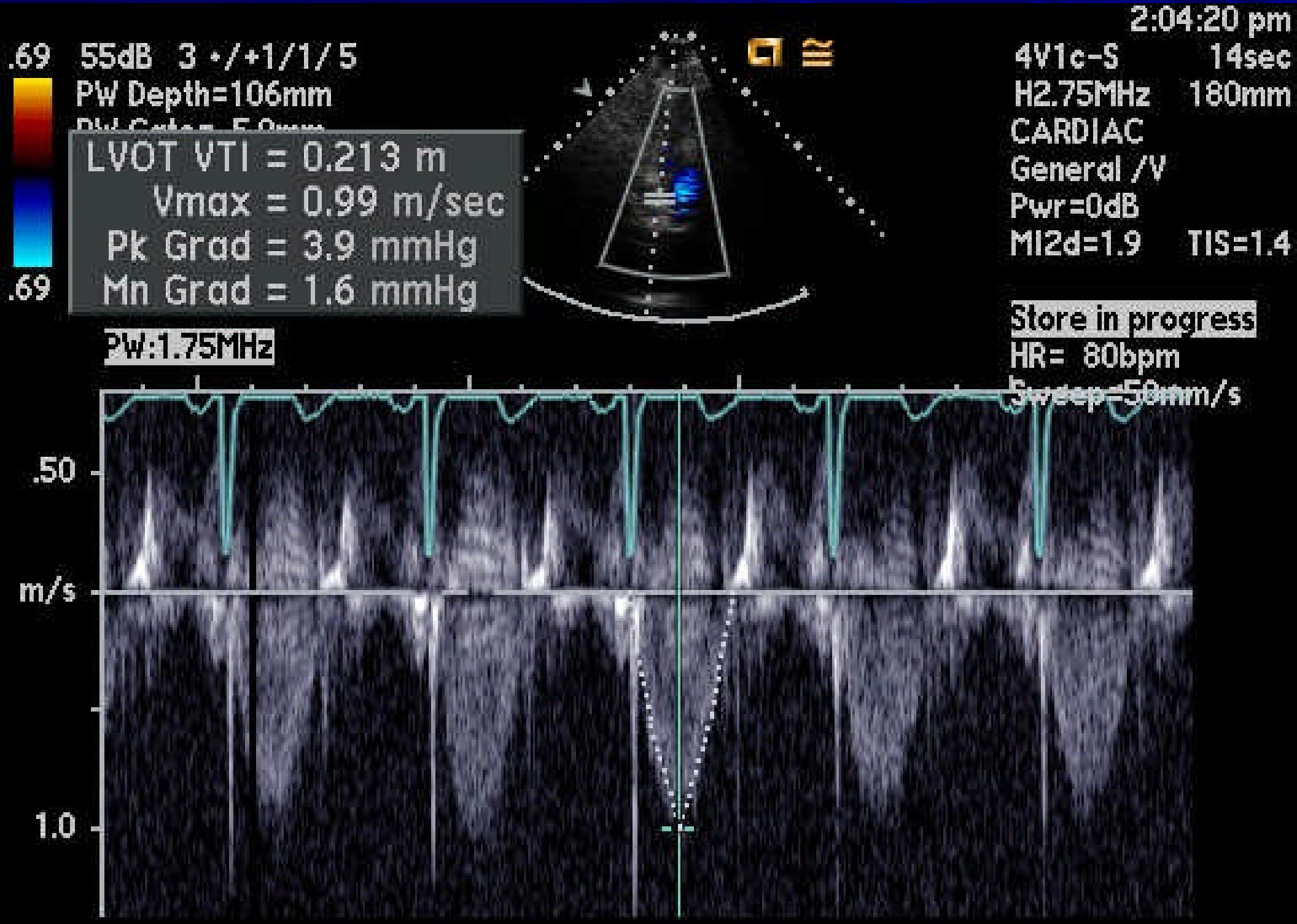

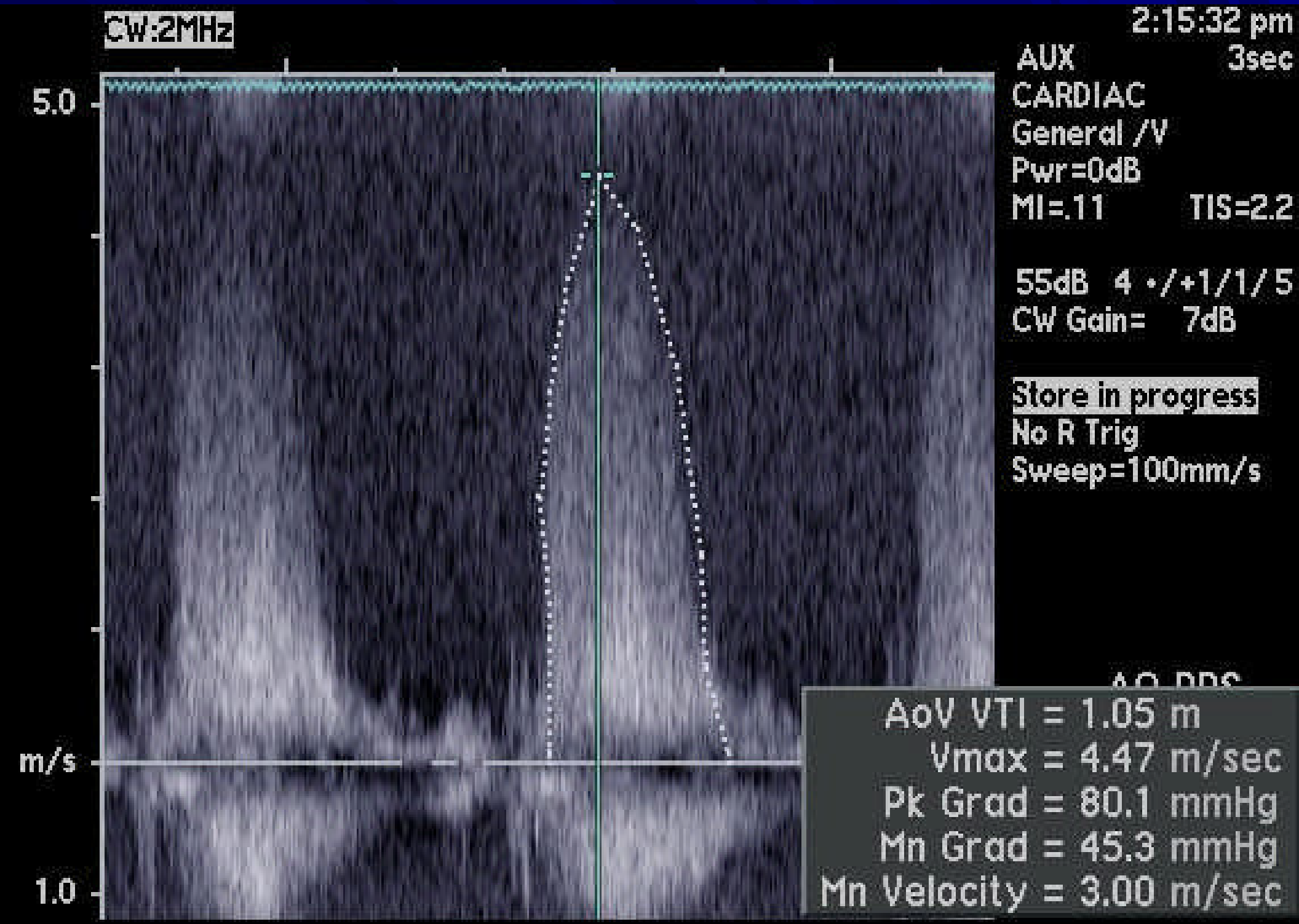

BSA 2.38 $m^2$ Ht. 188.0 cm Wt. 112.493 kg Age 77Years BP

## Aortic Valve — Aortic Doppler

| | | | | | |
|---|---|---|---|---|---|
| AoV Vmax | 4.47 | m/sec | AoV Pk Grad | 79.9 | mmHg |
| AoV VTI | 1.050 | m | AoV Mn Grad | 45.3 | mmHg |

## Aortic Valve — AoV Continuity Equation

| | AoV | LVOT | | | | |
|---|---|---|---|---|---|---|
| VTI | 1.050 | 0.213 | m | AoV Area, VTI | 0.77 | $cm^2$ |
| Vmax | 4.47 | 0.99 | m/sec | AoV Area, Vmax | 0.84 | $cm^2$ |
| Vmean | 3.000 | 0.568 | m/sec | AoV Area, Vmean | 0.72 | $cm^2$ |
| LVOT Diam | | 2.20 | cm | AoV Area/BSA, VTI | 0.32 | $cm^2/m^2$ |
| | | | | AoV Area/BSA, Vmax | 0.35 | $cm^2/m^2$ |
| | | | | AoV Area/BSA, Vmean | 0.30 | $cm^2/m^2$ |

See Reference Manual for information on editing measurements, results and calculations

# Severe aortic stenosis

- Aortic valve area <1.0cm$^2$
- Peak aortic velocity >4.0m$^2$
- Mean aortic valve gradient >40 mmHg

# Pathphysiology of Aortic Stenosis

- Previously felt to occur as a normal process of aging, related to mechnical stress on normal valve
- Current theory involves inflammatory process with T lymphocyte and macrophage infiltration with lipid accumulation, resulting in bone formation (calcification)

Braunwald 8th ed.

# Prevalence of Aortic Stenosis

- At age 65
  - 29% have aortic sclerosis
    - Irregular thickening of leaflets
    - Mild/early form of stenosis
  - 2% have aortic stenosis

Braunwald 8th ed.

# Risk factors for AS

- Genetic – familial clustering noted in some cases
- Elevated LDL
- Elevated Lp(a)
- Diabetes
- Smoking
- Hypertension

Braunwald 8th ed.

# Pathphysiology of Aortic Stenosis

- Valve orifice area slowly declines over time
- Symptoms progress gradually
- LV pressure overload results in concentric hypertrophy
- Increased LV wall mass, diastolic dysfunction

Braunwald 8th ed.

# Symptoms of AS (Severe)

- Exertional Dyspnea/Heart failure
- Chest pain
  - 50% with significant coronary atherosclerosis
- Syncope
  - Vasodilation with fixed cardiac output

# Physical Examination of AS

- Palpation of the carotid upstroke
  - *Parvus et tardus*
- Systolic murmur
  - Crescendo-decrescendo
- Heart failure
  - Crackles in lung fields
  - Jugular venous distension
  - Edema

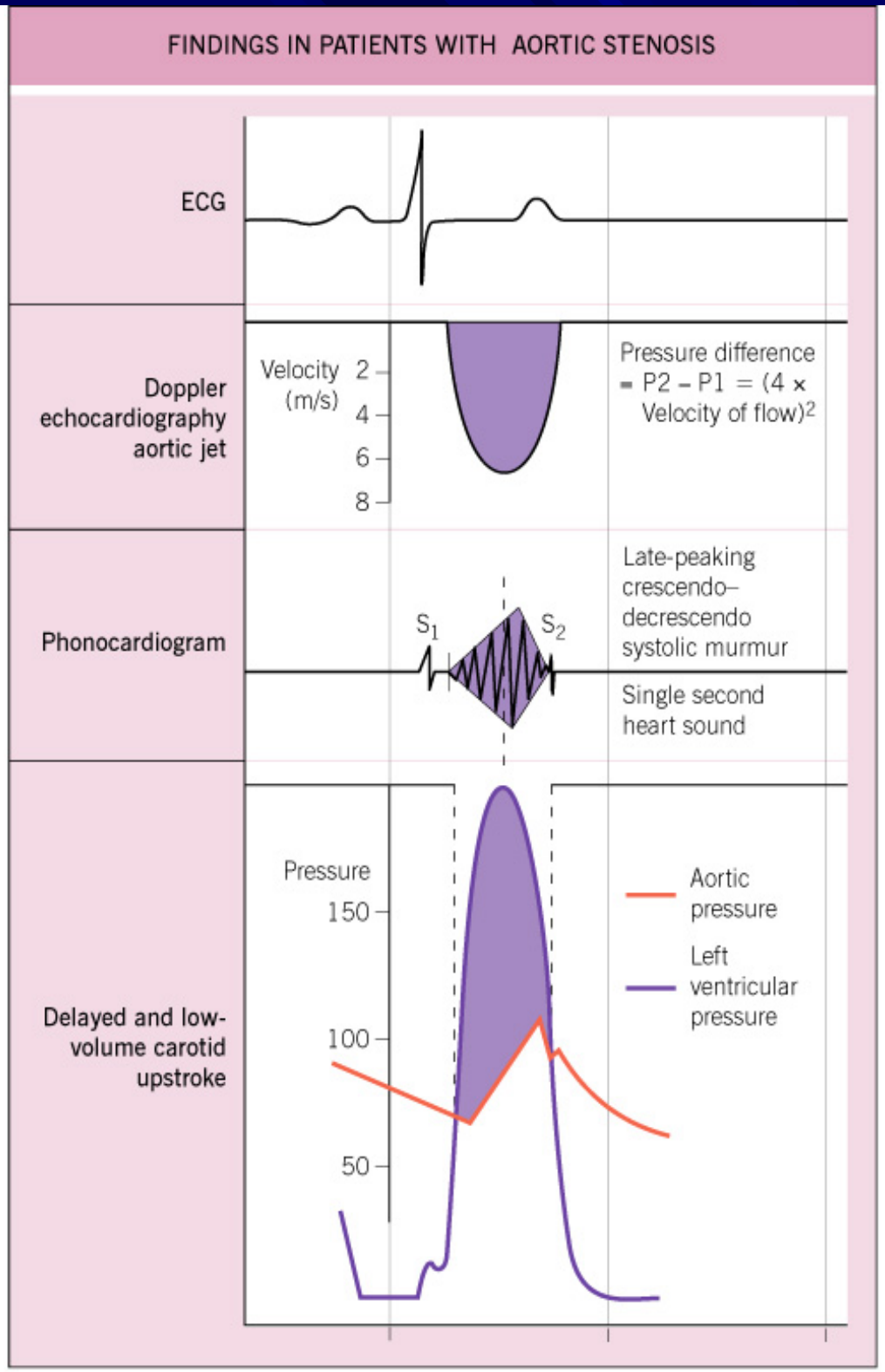

# Management of Asymptomatic Severe Aortic Stenosis

- Up to 33% remain asymptomatic for 5 years
- Without symptoms, prognosis is generally good
  - Risk of sudden death 1-2%/year
- Consider exercise testing under direct cardiologist supervision
  - Verify “asymptomatic”
  - Assess for fall in blood pressure

Pellikka PA, Sarano ME, Nishimura RA, et al. Outcome of 622 adults with asymptomatic, hemodynamically significant aortic stenosis during prolonged follow-up. Circulation 2005;111:3290 –5.
Rafique AM, Biner S, Ray I, Forrester JS, Tolstrup K, Siegel RJ. Meta-analysis of prognostic value of stress testing in patients with asymptomatic severe aortic stenosis. Am J Cardiol. 2009 Oct 1;104(7):972-7.

# Does statin treatment affect AS?

- Retrospective studies show slowing of progression
- Prospective (atorvastatin) study showed no benefit in advanced calcific aortic stenosis
- Prospective (rosuvastatin) study showed slowing of progression in less severe aortic stenosis
- Ongoing prospective trial using ezetimide (Zetia)

Cowell SJ, Newby DE, Prescott RJ, et al: A randomized trial of intensive lipid-lowering therapy in calcific aortic stenosis. *N Engl J Med* 2005; 352:2389.
Moura LM, Ramos SF, Zamorano JL, et al: Rosuvastatin Affective Aortic Valve Endothelium to slow the progression of aortic stenosis. *J Am Coll Cardiol* 2007; 49:554.

# Case 1 management

- Exercised for 9 minutes on treadmill
  - Manual modified protocol
  - 6.8 METS
  - 83% maximum predicted heart rate
  - Good rise in blood pressure
  - Mild shortness of breath symptoms
- Started on Beta blocker

# Case 1 Plan

- Remains asymptomatic 1 year later
- Plan for clinical follow-up every 6 months
- If other heart surgery (CABG) indicated, valve will be replaced

# Case 2

- 48 year old male
- Heart murmur appreciated on physical examination
- Mild shortness of breath with exertion
  - Climbing 3 flights of stairs
  - No Chest pain
- Overweight, quit smoking recently
- DM, HTN, HLP

# Echocardiogram

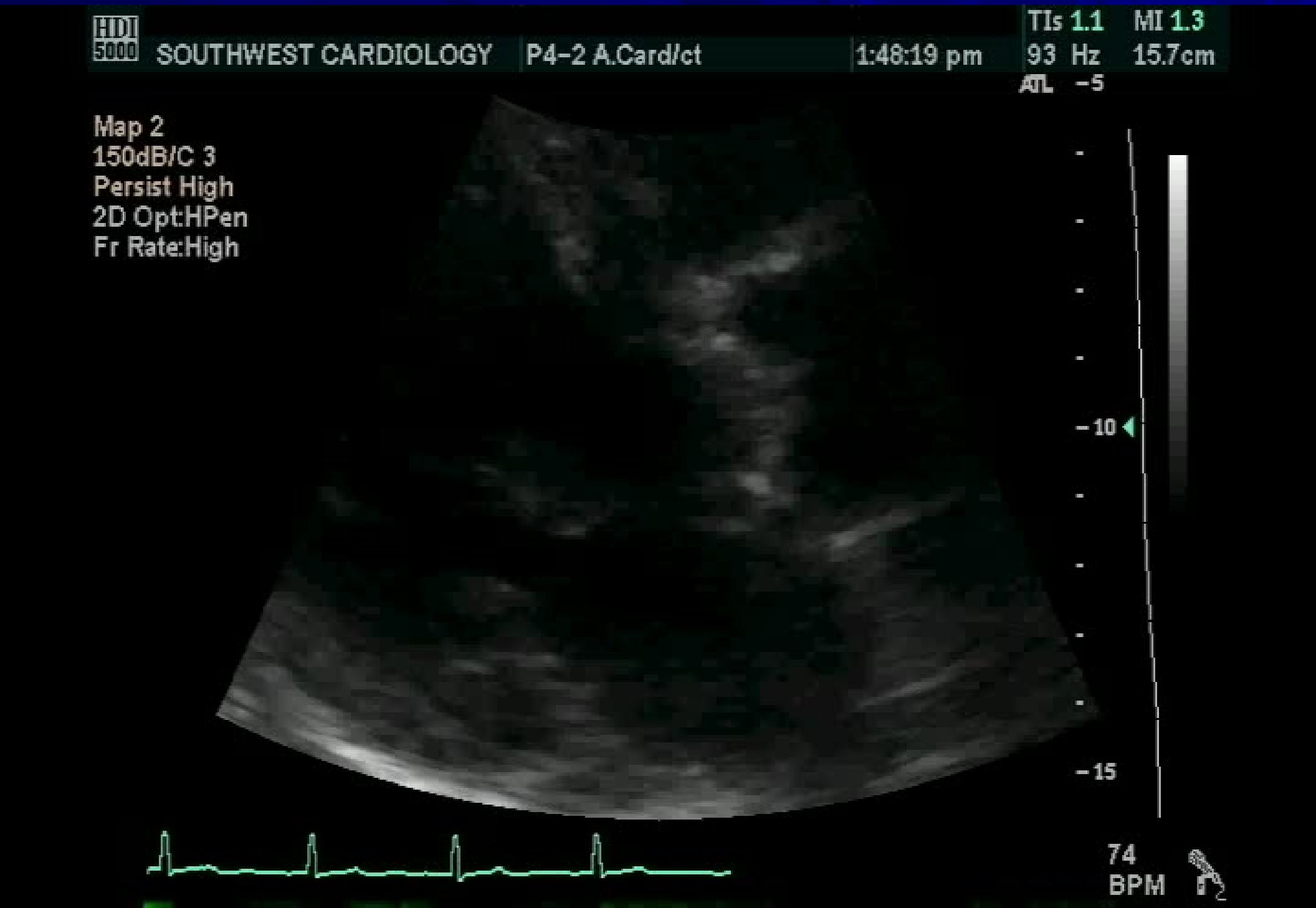

# A closer look at the aortic valve

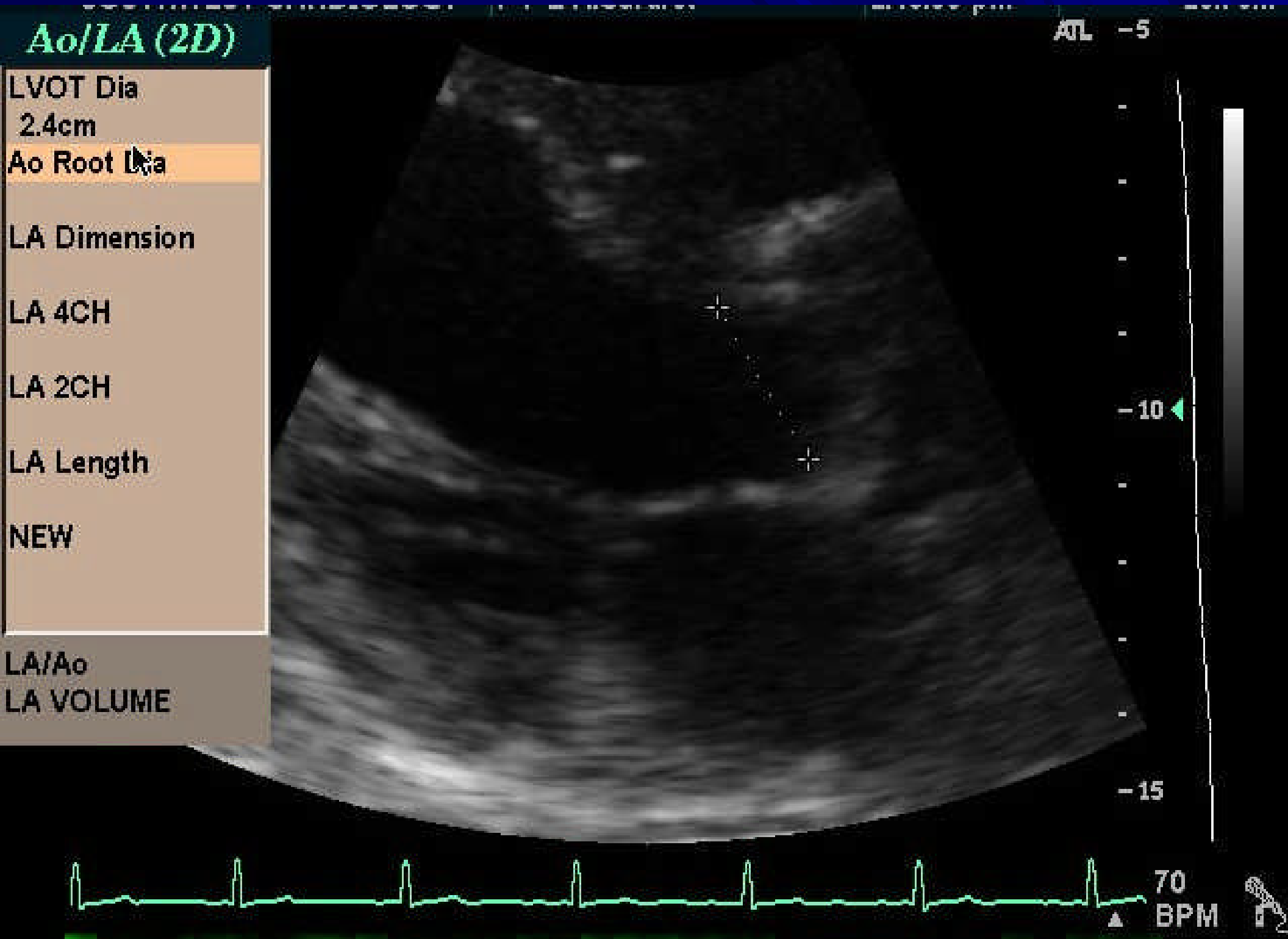

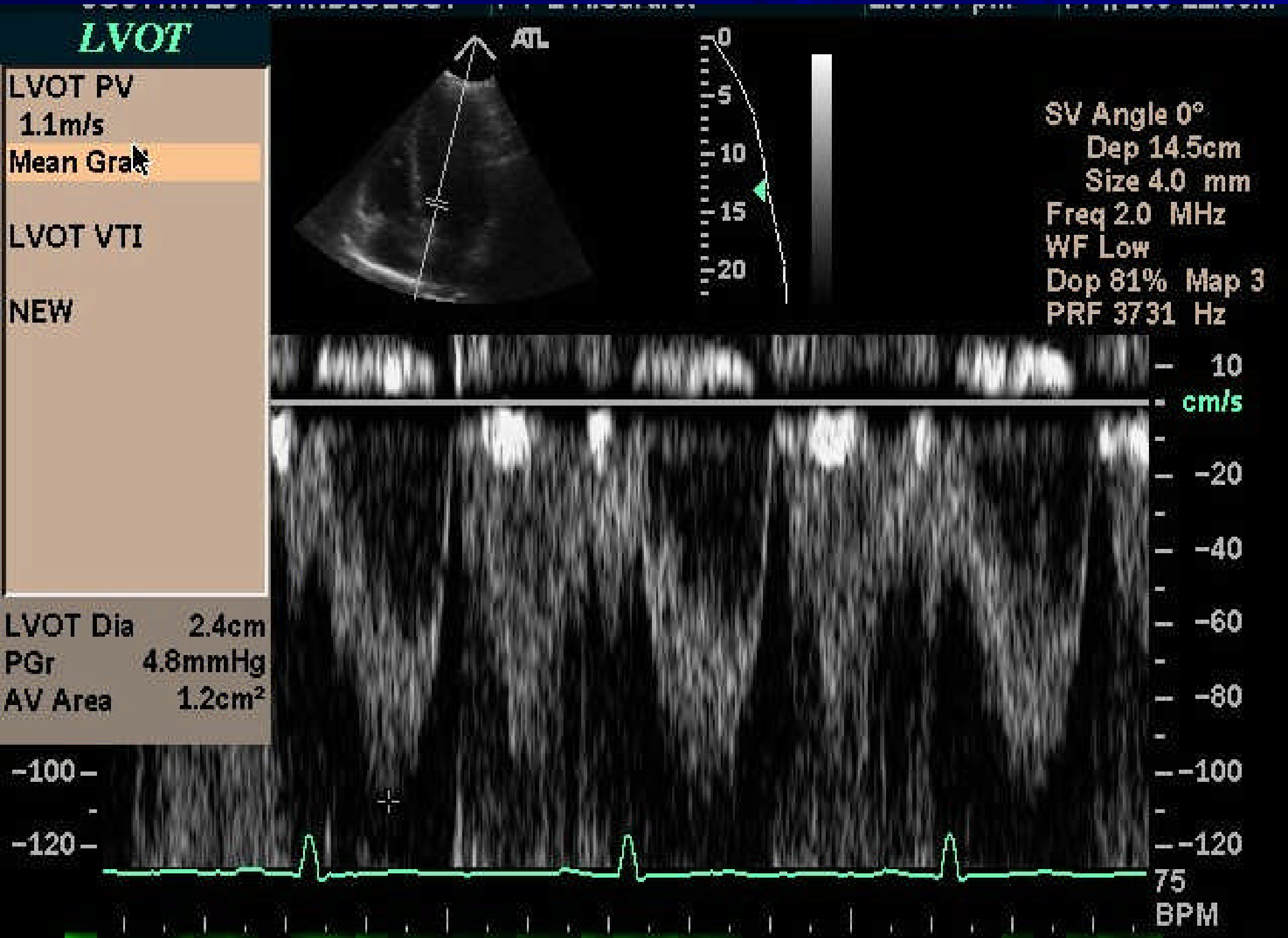

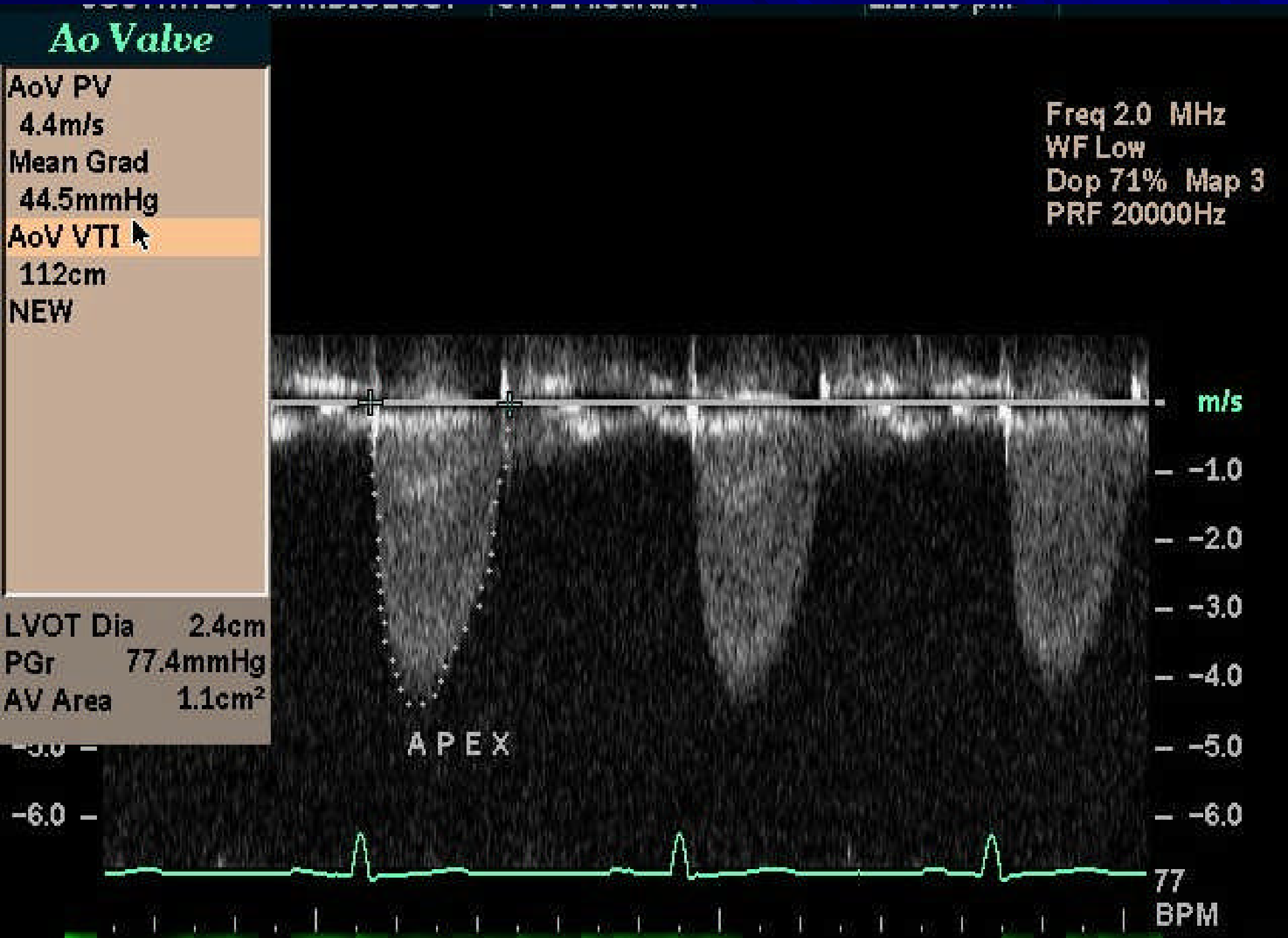

# Bicuspid Aortic Valve

- Moderate to severe aortic stenosis
  - Aortic valve area 1.1 $cm^2$
  - Mean pressure gradient 44.5 mmHg
  - Peak velocity 4.4 m/s
- Mild aortic valve regurgitation
- Dilated of aortic root (4.3 cm)

# Bicuspid aortic valve

- 1-2% Incidence in live births
- Male predominance (up to 80%)
- Association with disorders of aorta
  - Coarctation
  - Dilitation/aneurysm
  - Dissection
- Symptomatic stenosis develops around age 50
- Familial form with autosomal dominant inheritance (NOTCH1 gene mutation)

Carabello BA, Paulus WJ. Aortic stenosis. Lancet. 2009 Mar 14;373(9667):956-66. Epub 2009 Feb 21.
Braunwald 8th ed.

# Management of Moderate Bicuspid Aortic Stenosis

- If there is aortic dilatation (>4.0cm)
  - Beta Blockers unless contraindicated
    - Moderate to severe regurgitation
  - Echo every year
  - Surgery if aortic root >5.0cm or >0.5cm/1 year
- Without aortic dilatation
  - No specific medical therapy
  - Echo every 1-2 years or if clinical change

Bonow RO, Carabello BA, Chatterjee K, de Leon AC Jr, Faxon DP, Freed MD, Gaasch WH, Lytle BW, Nishimura RA, O'Gara PT, O'Rourke RA, Otto CM, Shah PM, Shanewise JS; American College of Cardiology/American Heart Association Task Force on Practice Guidelines. 2008 focused update incorporated into the ACC/AHA 2006 guidelines for the management of patients with valvular heart disease: a report of the American College of Cardiology/American Heart Association Task Force on Practice Guidelines (Writing Committee to revise the 1998 guidelines for the management of patients with valvular heart disease). Endorsed by the Society of Cardiovascular Anesthesiologists, Society for Cardiovascular Angiography and Interventions, and Society of Thoracic Surgeons. J Am Coll Cardiol. 2008 Sep 23;52(13):e1-142

# Case 2 plan of care

- On statin for hyperlipidemia
- Treatment of DM, HTN (ARB)
- Aspirin 81mg daily
- Followup office and echo in 6 months

# Another example of Bicuspid Aortic Valve

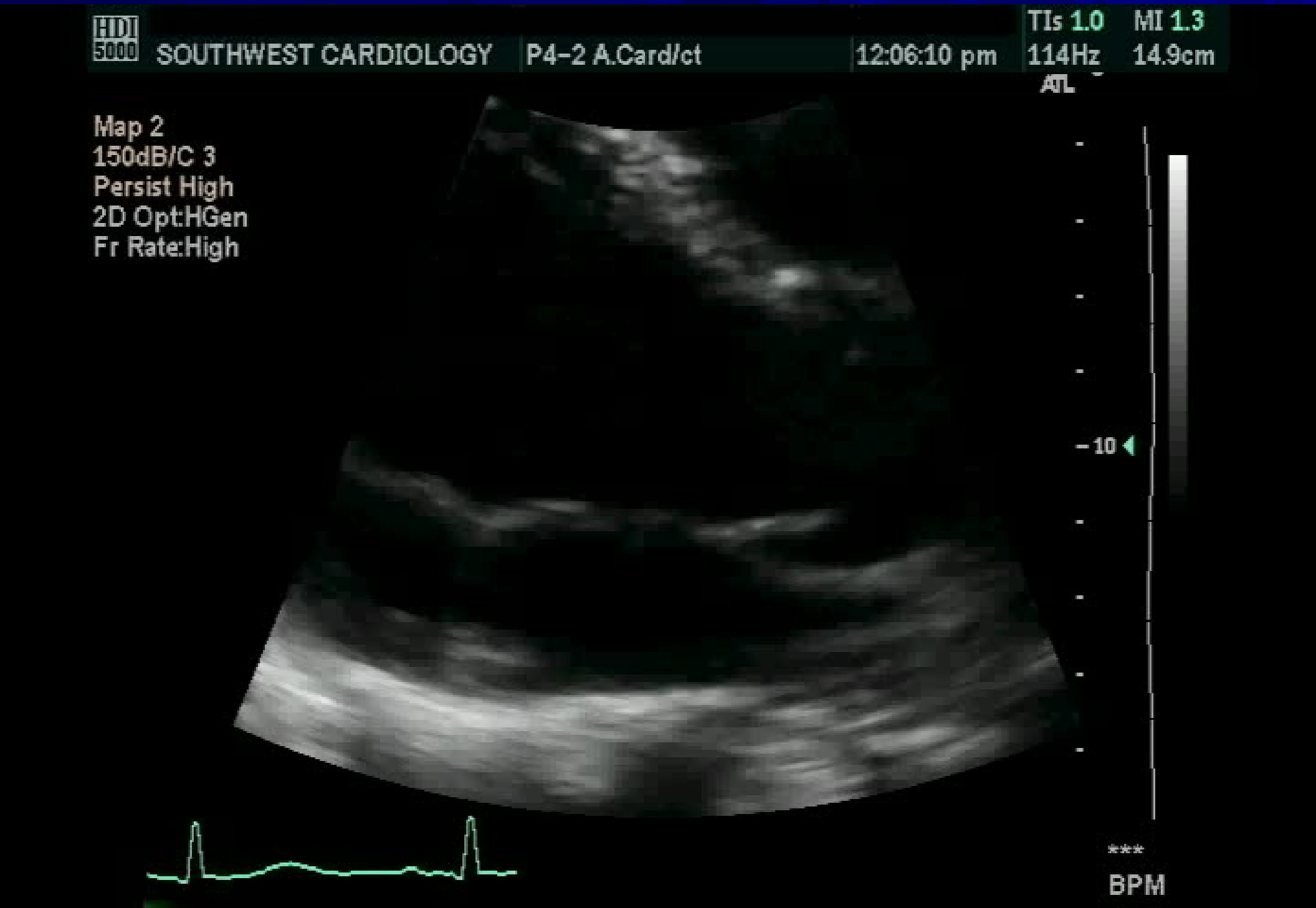

# Case 3

- 44 year old white male
- Referred for loud murmur
- Spouse started hearing his heart at night about 1 month ago
- Asymptomatic, physically active, able to climb stairs
- No smoking, DM, HTN
- 6/6 loud holodiastolic murmur

# Transthoracic Echo

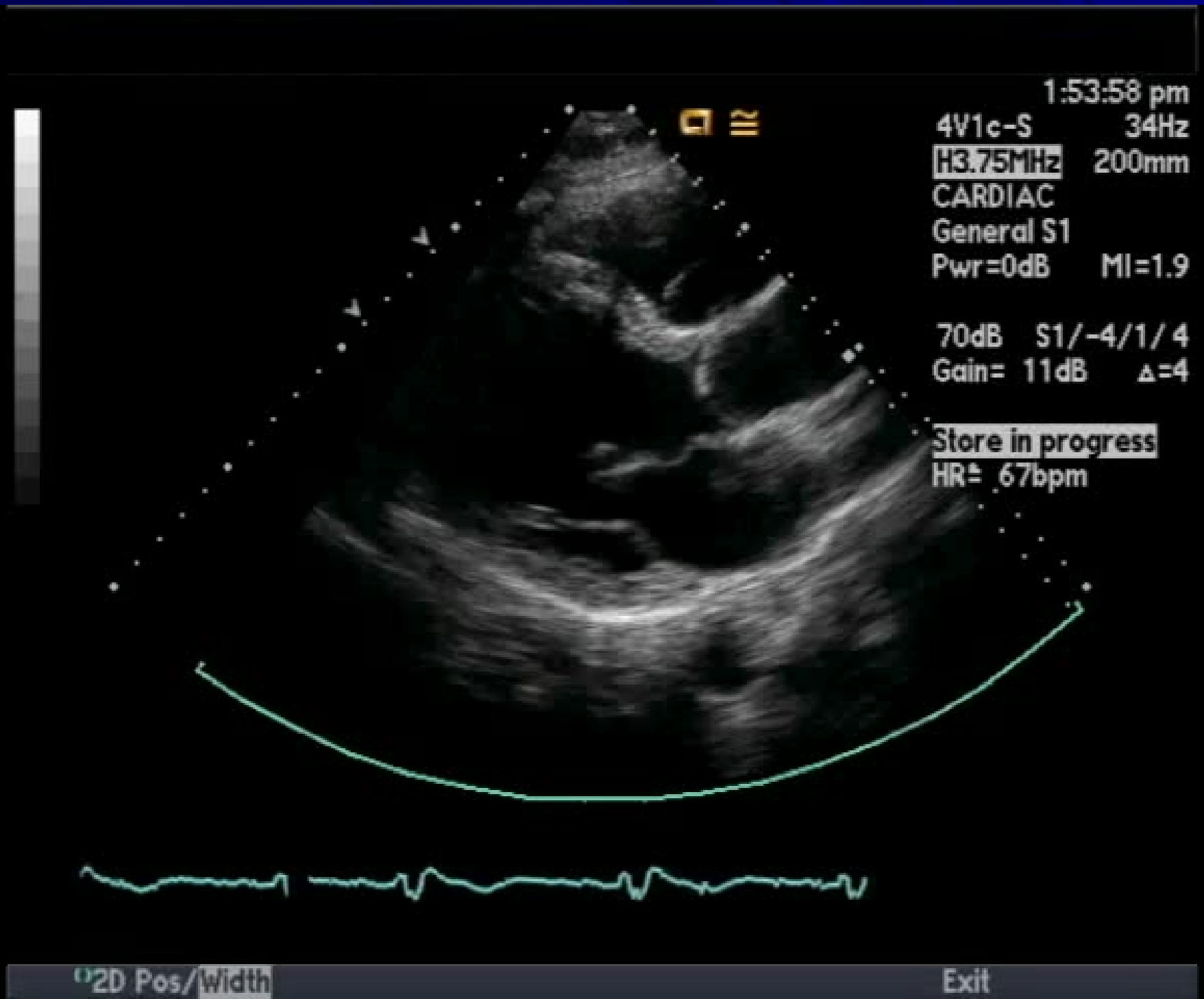

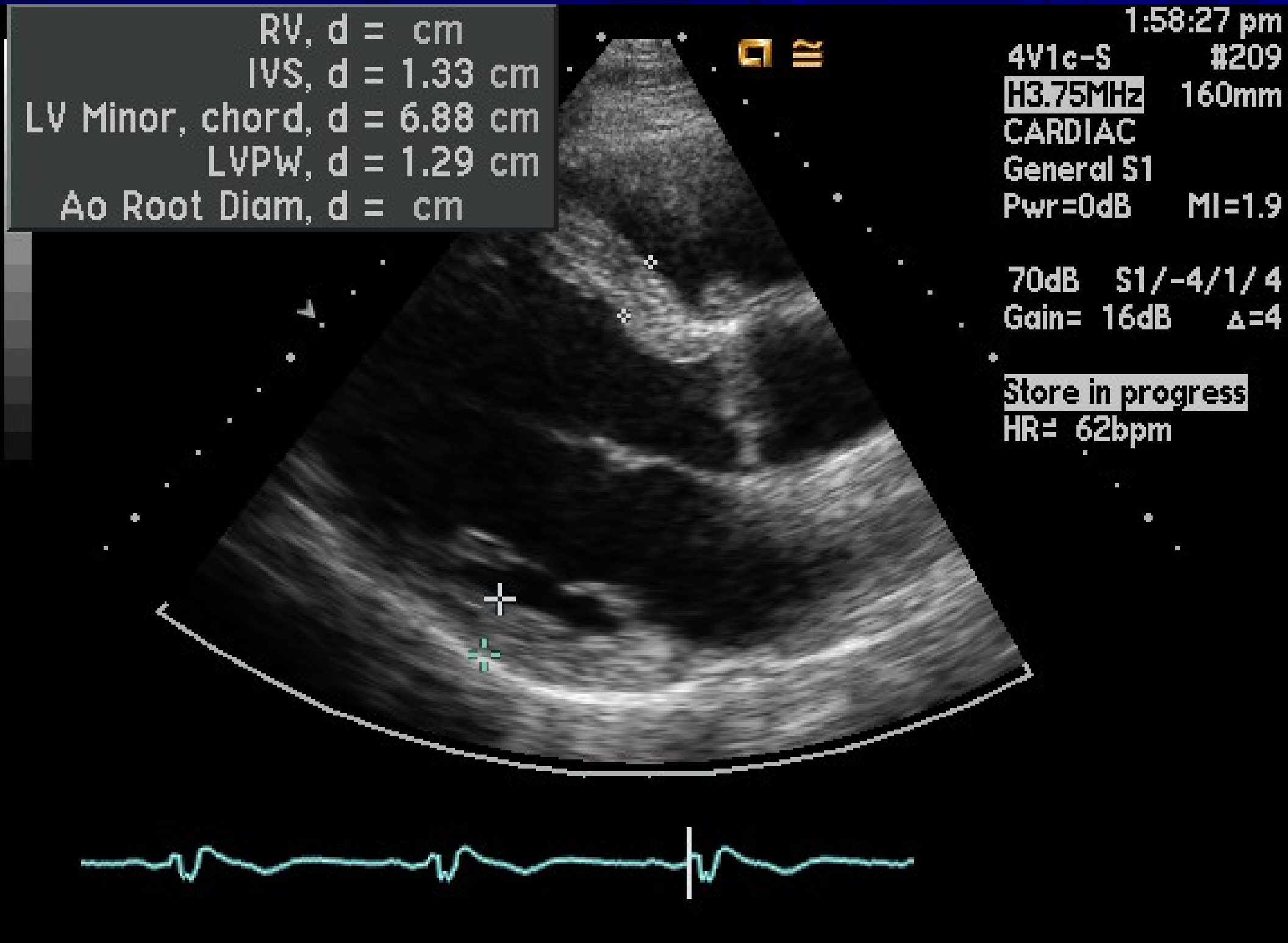

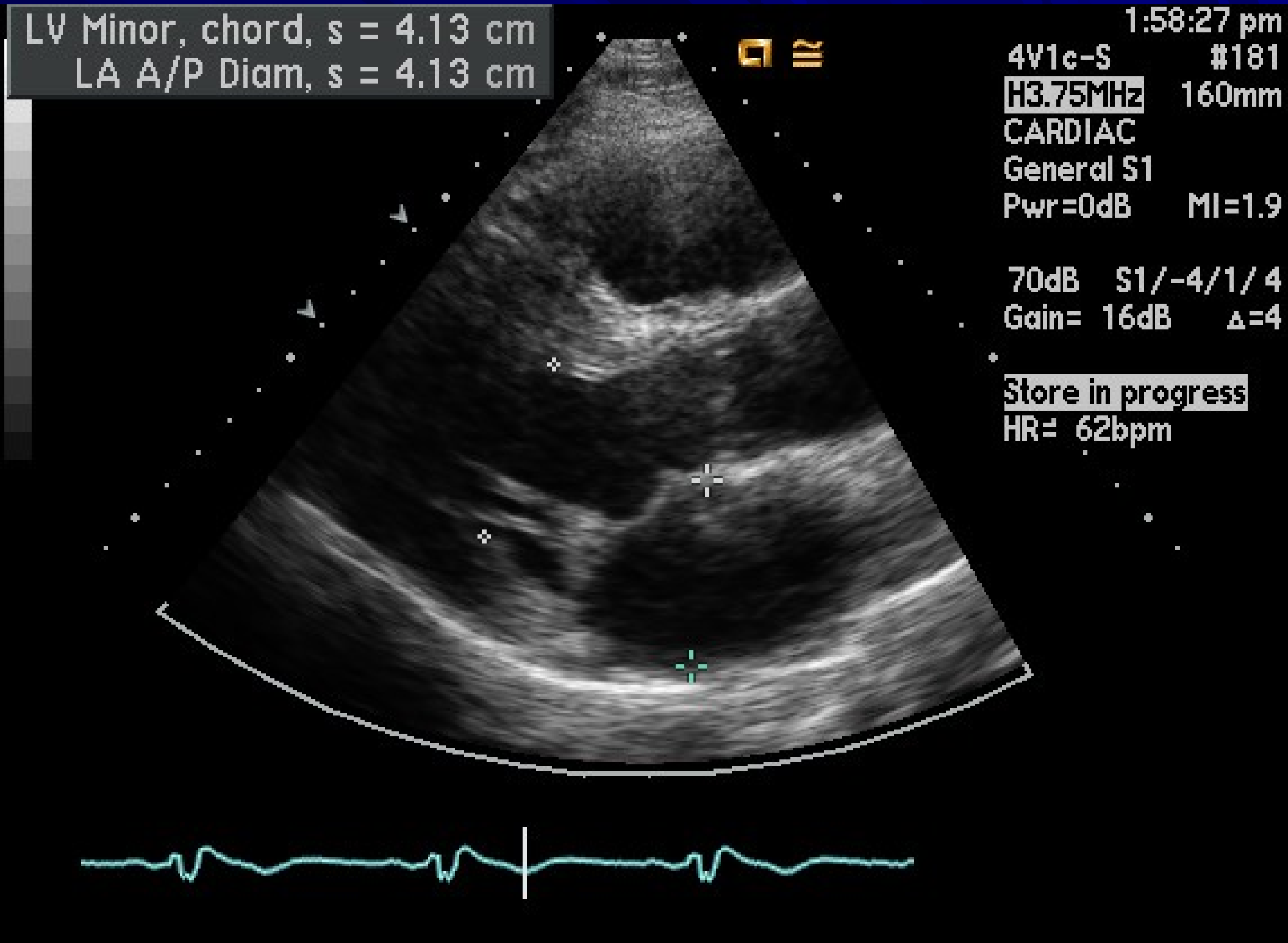

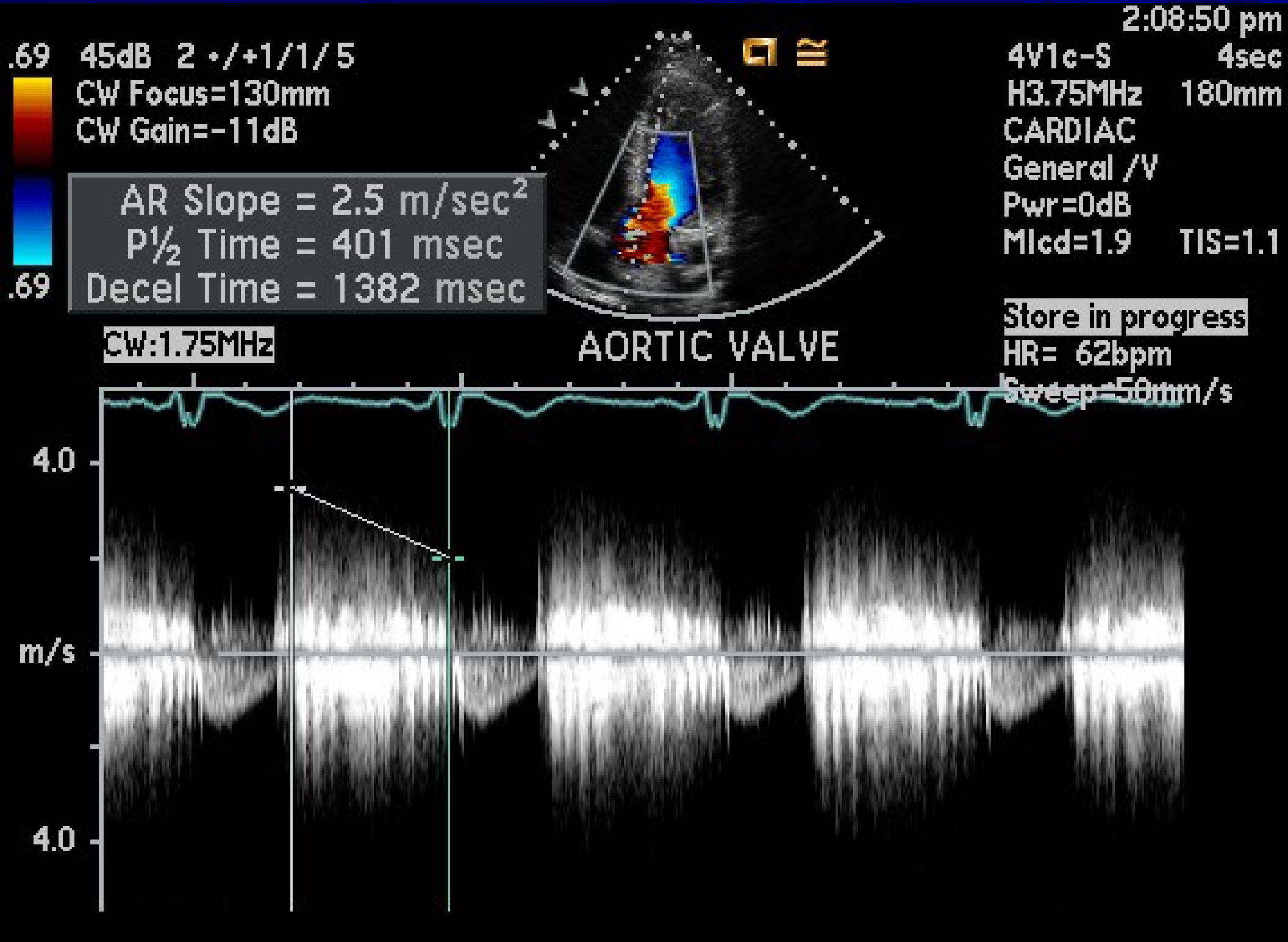

# Indications for Valve replacement in Aortic regurgitation

- Connective tissue disease with aortic root dilitation (25%)
- Congenital, including bicuspid (13%)
- Infective endocarditis (10%)
- Age-related calcific degeneration (7%)
- Other/Unknown/Idiopathic (35%)
  - Trauma, rheumatic, syphillis, aortic dissection, fenfluramine + phentermine, Antiphospholipid syndrome

Crawford & DiMarco, 2nd ed
Borer JS, Hochreiter C, Herrold EM, Supino P, Aschermann M, Wencker D, Devereux RB, Roman MJ, Szulc M, Kligfield P, Isom OW. Prediction of indications for valve replacement among asymptomatic or minimally symptomatic patients with chronic aortic regurgitation and normal left ventricular performance. Circulation. 1998 Feb 17;97(6):525-34.

# How to assess aortic regurgitation

- History
- Physical
- Echocardiogram
- Angiography
- MRI

# Echocardiographic evaluation of aortic regurgitation

- Color Doppler
  - Jet area
  - Jet height
  - PISA ERO
- Pressure ½ time
- Regurgitant fraction, volume
- Descending thoracic aortic flow reversal
- Left ventricular EF and dimensions
- No single criteria is perfect
- Eccentric jets are often <u>worse</u> than calculated/estimated

# Color doppler

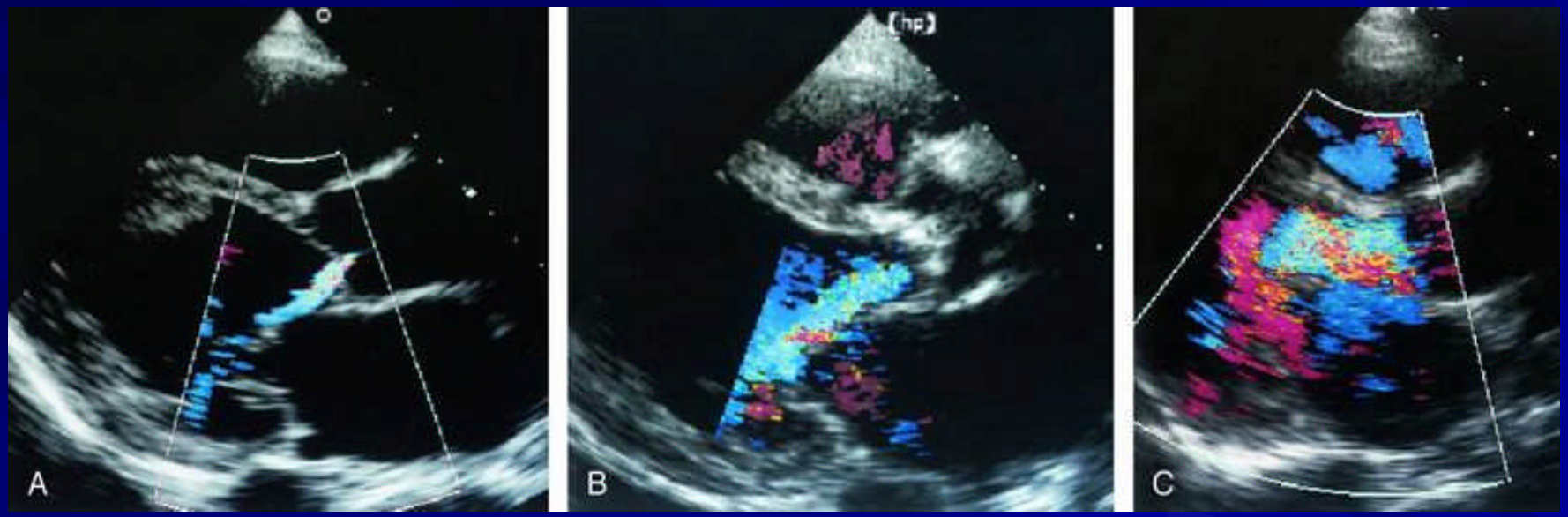


Mild Moderate Severe

- Visual inspection
- Also Jet area and jet height

Feigenbaum 6th ed

# Pressure ½ time

- Measurement of time it takes for aortic pressure to equalize to (½) left ventricular pressure
- Variable thresholds in literature!
  - <300ms consistent with severe regurgitation
  - 300-500ms moderate
  - >500ms mild

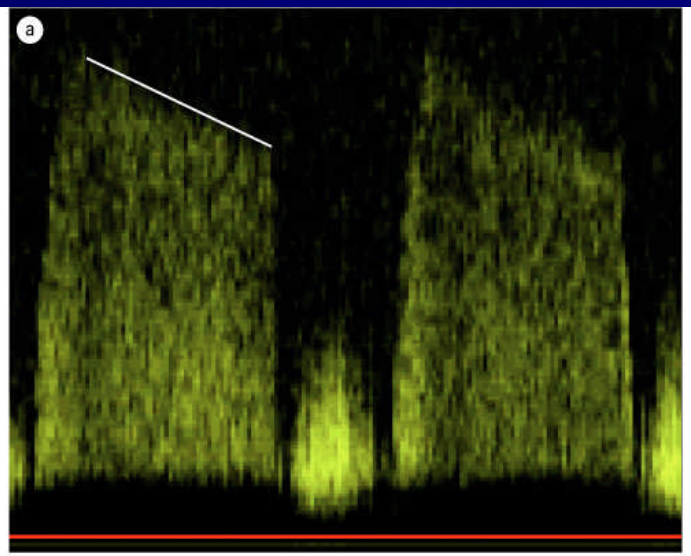




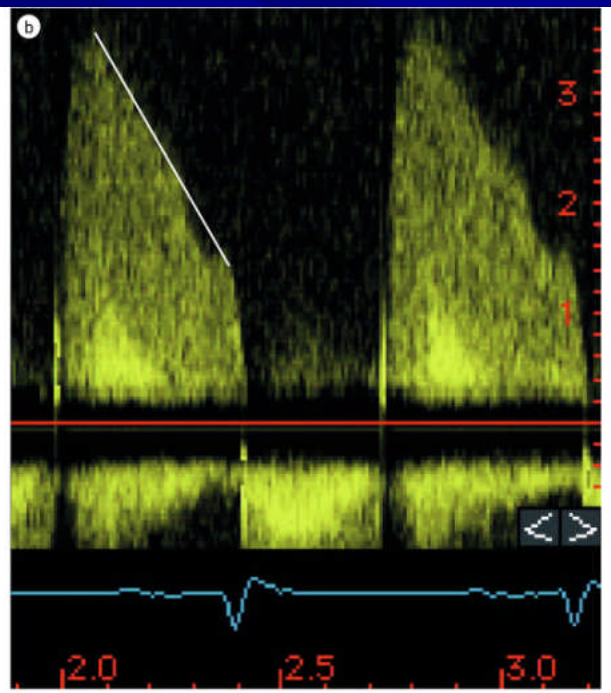

# Flow reversal in descending thoracic aorta

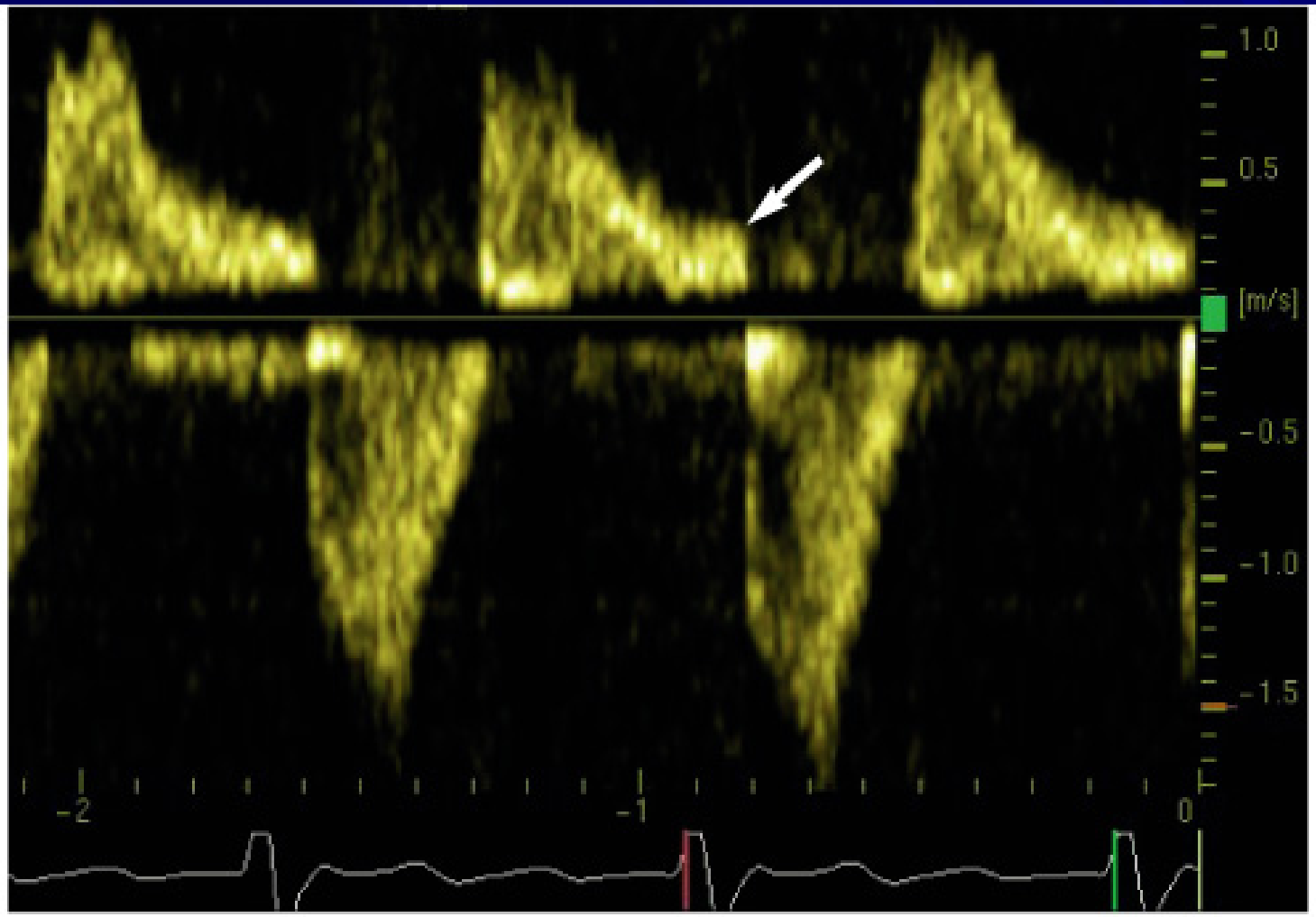

# Transesophageal Echo

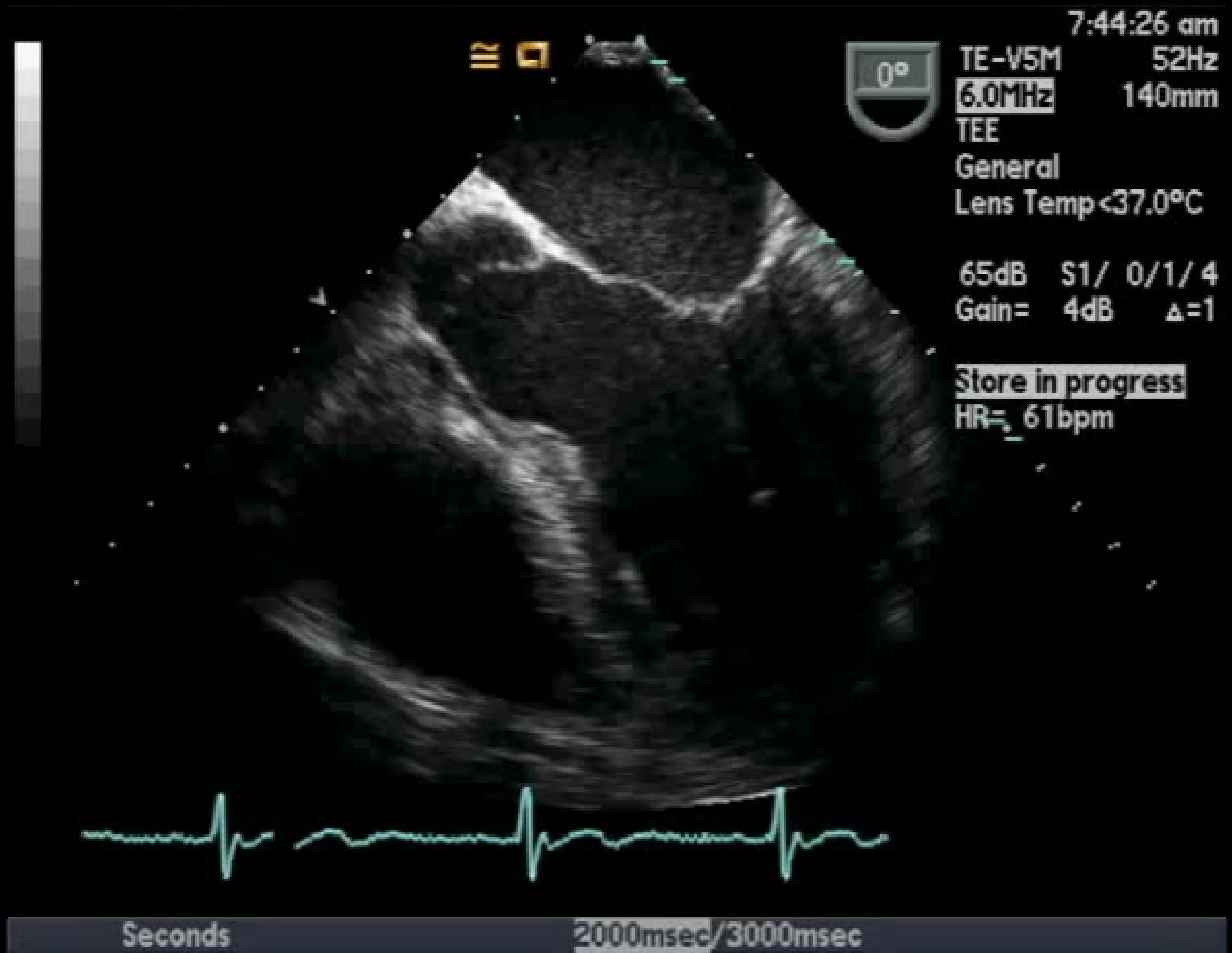

# Case 3 management

- Severe posteriorly eccentric aortic regurgitation
- LV diastolic dimension 6.9cm
- EF 60-65%

- No clear etiology
- Blood cultures obtained
  - 2 of 2 initially positive gram + cocci
  - 1 of 4 subsequently positive gram + cocci
  - Initially admitted, treated with IV antibiotics
  - Blood cultures staph, all different species
  - Antibiotics stopped, no symptoms

# Criteria for Surgery?

- Asymptomatic Severe Aortic regurgitation
  - EF <50%
  - Systolic dimension >5.5cm
  - Diastolic dimension >7.5cm
- Guidelines are complicated, but become more vigilant about surveillance when
  - Systolic dimension >5.0cm
  - Diastolic dimension >7.0cm

# Issues not addressed in guidelines

- Noncoronary cusp prolapse with severe eccentric jet hitting anterior leaflet of the mitral valve
  - ? Possibility to distort Mitral valve architecture
- Unclear etiology
- Lifestyle
  - Both patient and spouse hear the murmur

# Referred for elective surgery

- Mechanical or bioprosthetic valve?
- Intraoperatively, torn noncoronary cusp noted
- Overall stable postoperative course

# Case 4

- Male in mid 40's
- History of automobile accident with orthopedic trauma
- Several years afterward, noted to have murmur
- Echo showed aortic regurgitation
- Overall asymptomatic
- Does not want to take medications

# Echo 8 years later…

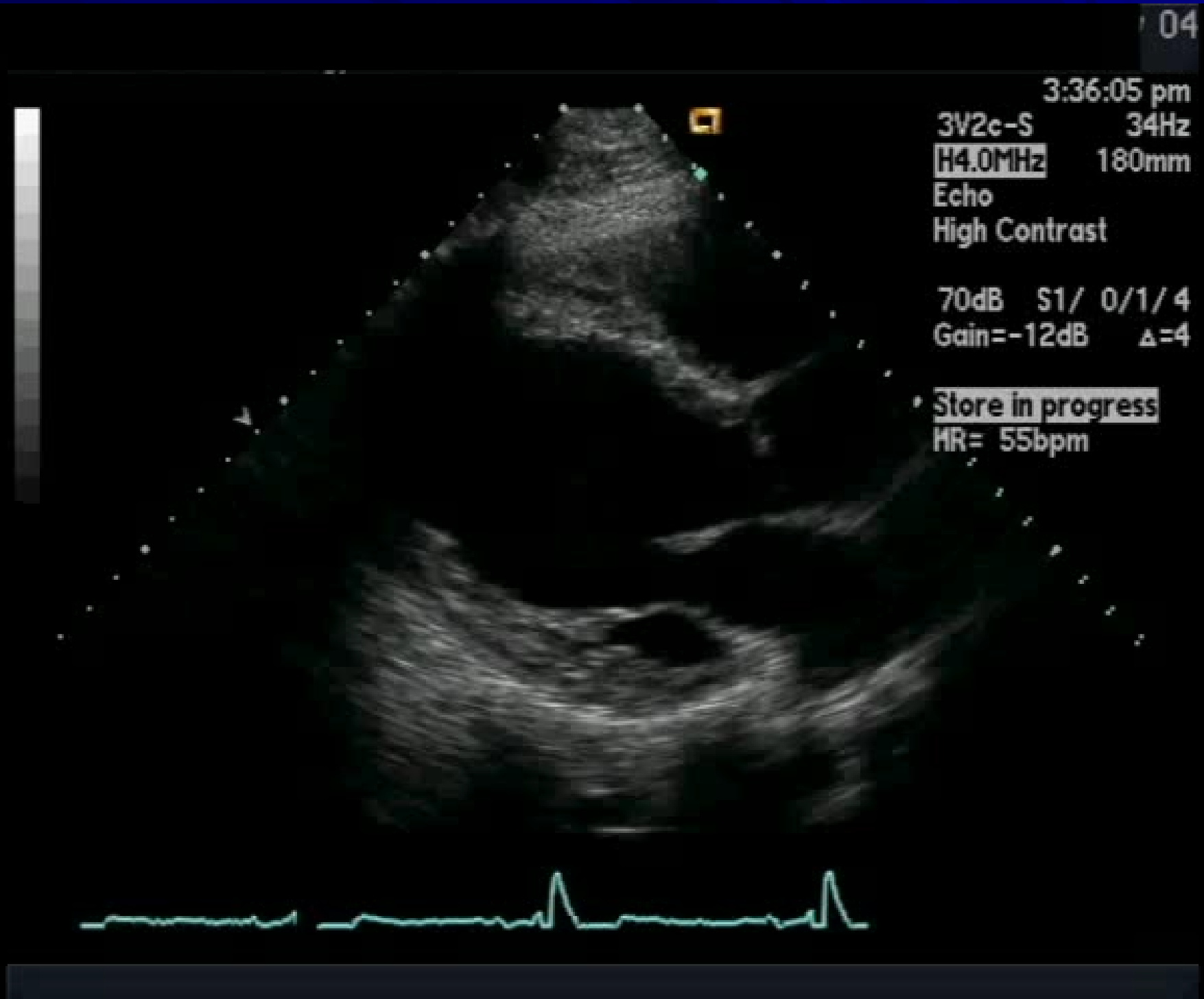

# Management

- LV diastolic dimension 7.6cm
- EF 55-60%
- Class 2A indication for surgery by guidelines

- Vasodilator therapy (Nifedipine, ACE inhibitors) are a Class 2B indication

- Pt declines surgery and medications
- 6-12 month clinical and echo followup

Bonow RO, Carabello BA, Chatterjee K, de Leon AC Jr, Faxon DP, Freed MD, Gaasch WH, Lytle BW, Nishimura RA, O'Gara PT, O'Rourke RA, Otto CM, Shah PM, Shanewise JS; American College of Cardiology/American Heart Association Task Force on Practice Guidelines. 2008 focused update incorporated into the ACC/AHA 2006 guidelines for the management of patients with valvular heart disease: a report of the American College of Cardiology/American Heart Association Task Force on Practice Guidelines (Writing Committee to revise the 1998 guidelines for the management of patients with valvular heart disease). Endorsed by the Society of Cardiovascular Anesthesiologists, Society for Cardiovascular Angiography and Interventions, and Society of Thoracic Surgeons. J Am Coll Cardiol. 2008 Sep 23;52(13):e1-142

# 5 years later after last echo

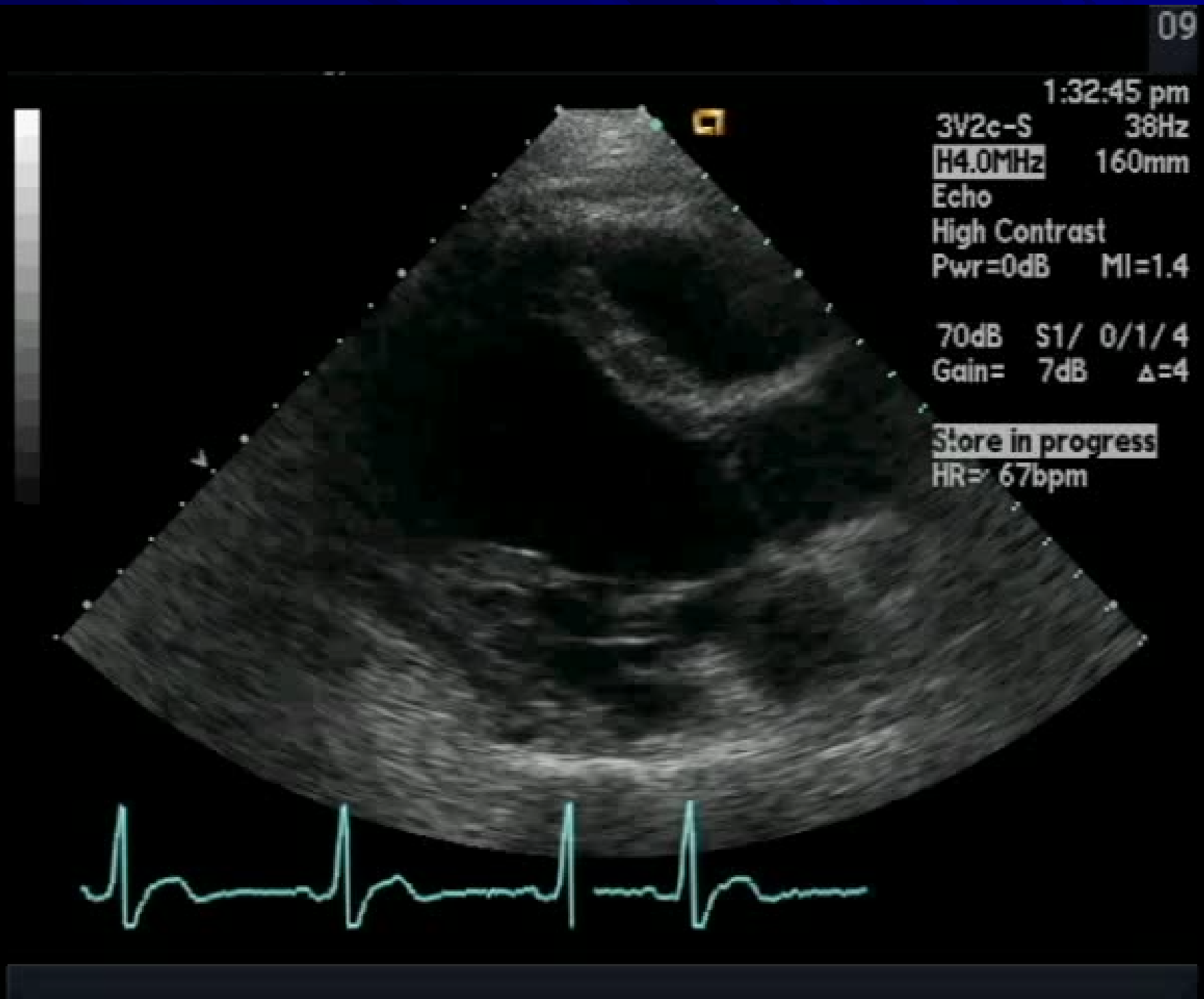

# As time passes…

- Initial
- 5 Years Later

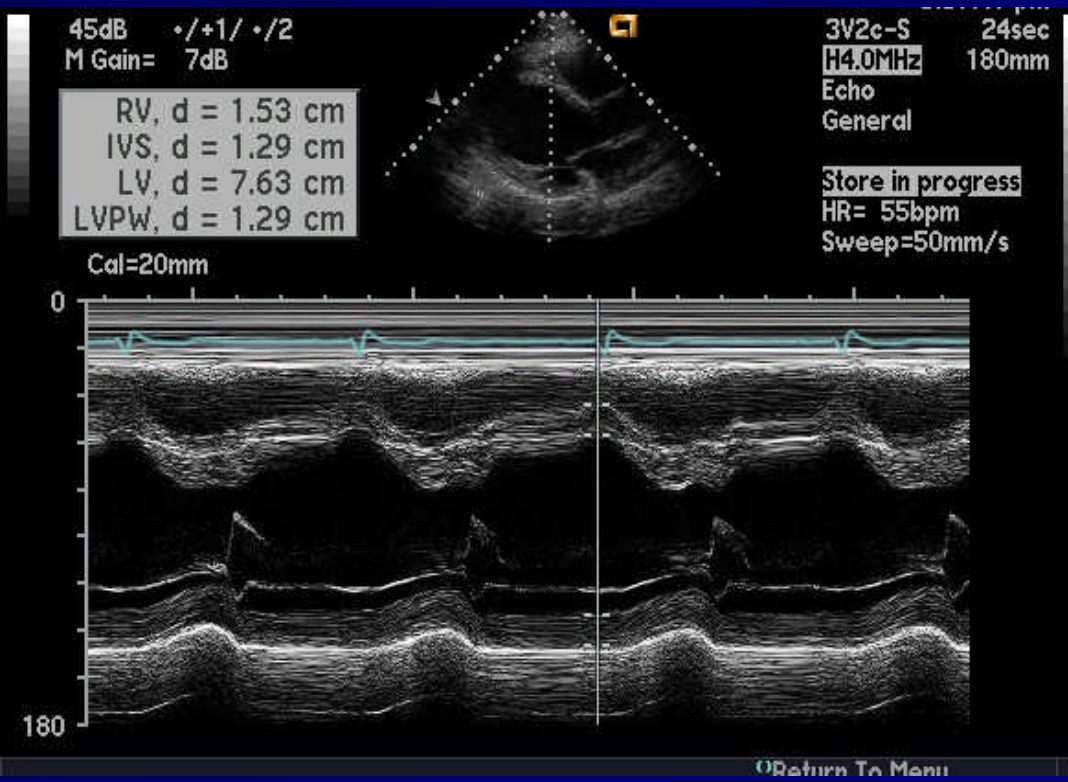


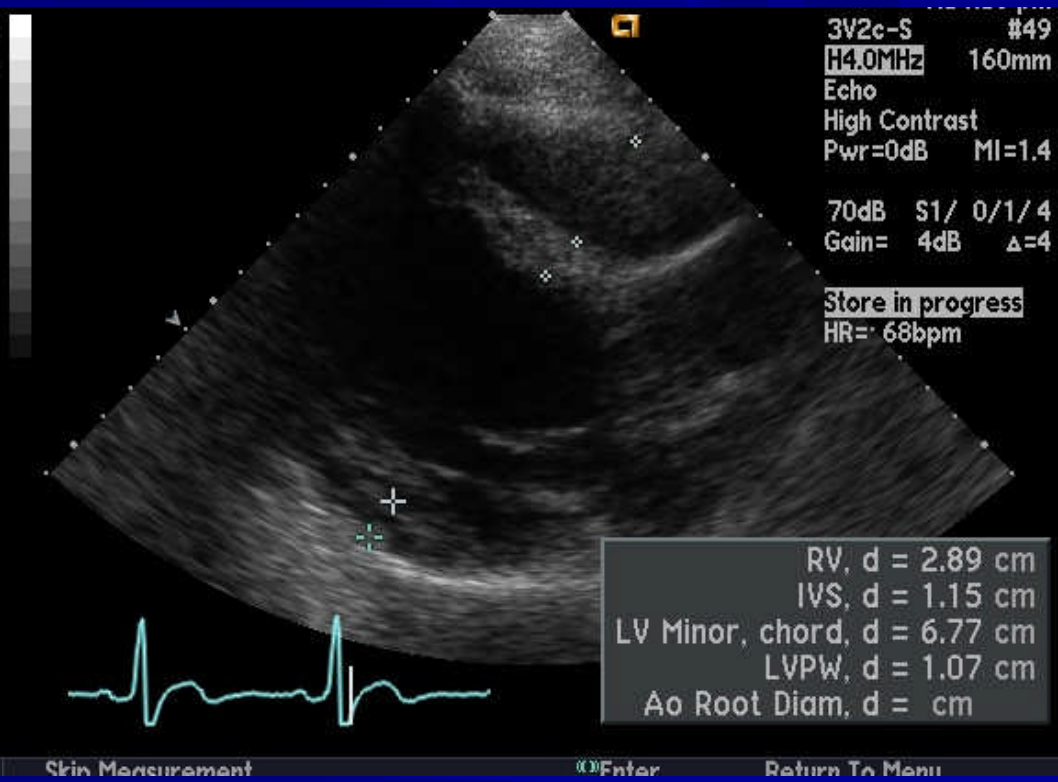


LVH decreases
LV diastolic dimension decreases

# As time passes…

- Initial
- 5 Years Later

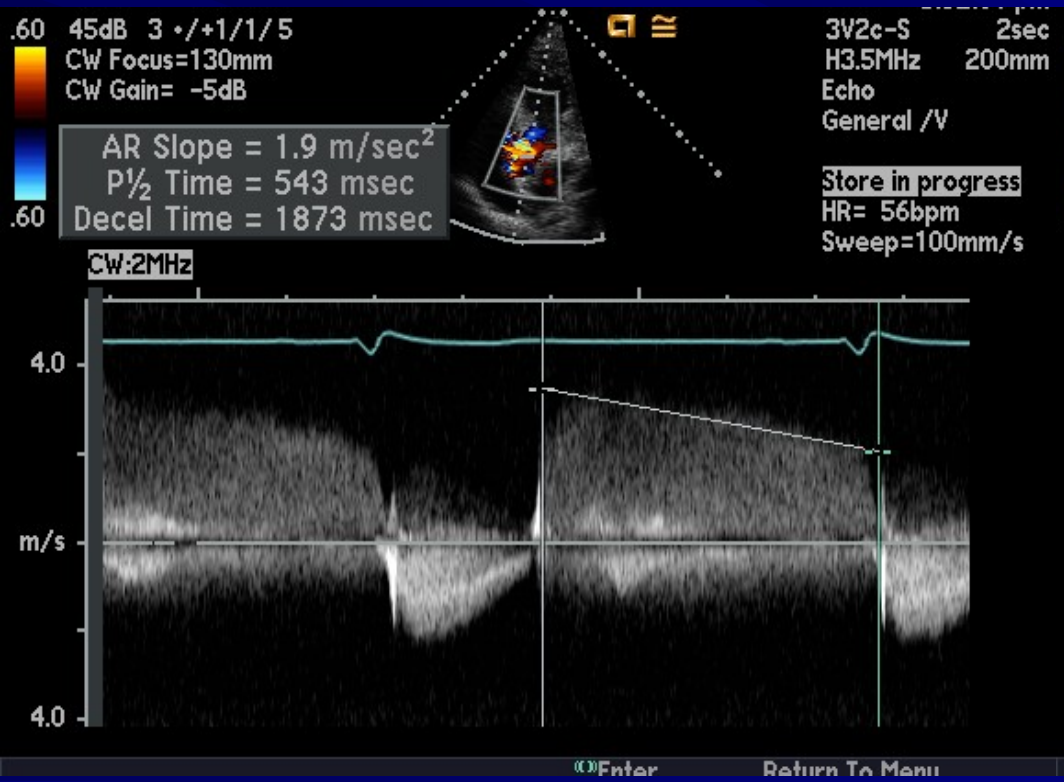


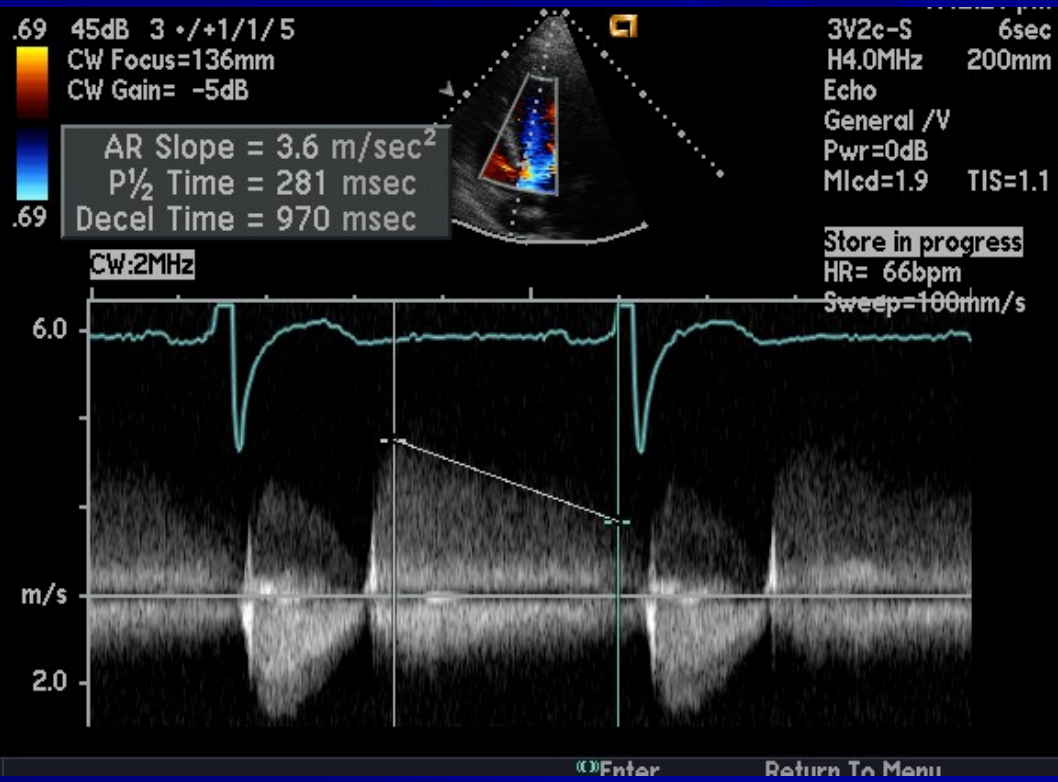


Pressure ½ Time decreases
Correlating with worse regurgitation

# As time passes…

- Initial
- 5 Years Later

M-mode

| | Diastole | Systole | |
|---|---|---|---|
| RV | 1.53 | | cm |
| IVS | 1.29 | | cm |
| LV | 7.63 | 4.02 | cm |
| LVPW | 1.29 | | cm |
| Ao Diam | 3.62 | | cm |
| LA Diam | | 5.14 | cm |
| AoV Cusp Sep | | 2.49 | cm |
| LV % FS | | 47.3 | % |
| IVS/LVPW | | 1.00 | |

M-mode

| | ASE | ASEcorr | |
|---|---|---|---|
| LV Mass | 644.9 | | g |

| | Diastole | Systole | |
|---|---|---|---|
| LV Vol | 310.0 | 70.8 | ml |
| LV SV | | 239.2 | ml |
| LV EF | | 77.2 | % |
| LV CO | | 13.15 | l/min |
| HR | | 55 | bpm |

Page Up | Page Down | Image | Expand

M-mode

| | Diastole | Systole | |
|---|---|---|---|
| Ao Diam | 3.67 | | cm |
| LA Diam | | 4.61 | cm |
| AoV Cusp Sep | | 2.07 | cm |
| MV EPSS | | 1.29 | cm |

M-mode

2D Dimensions PLAX

| | Diastole | Systole | |
|---|---|---|---|
| RV | 2.89 | | cm |
| IVS | 1.15 | | cm |
| LV Minor, chord | 6.77 | 4.24 | cm |
| LVPW | 1.07 | | cm |

| | | |
|---|---|---|
| LV % FS | 37.4 | % |

| | Diastole | Systole | |
|---|---|---|---|
| Ao Root Diam | 1.21 | | cm |

Page Up | Page Down | Image | Expand

# Variable natural history

- Asymptomatic patients with normal LV function
  - <6%/year have symptoms and/or LV dysfunction
  - <3.5%/year progress to asymptomatic LV dysfunction
  - <0.2%/year have sudden cardiac death
- Asymptomatic patients with LV dysfunction
  - >25%/year progress to have symptoms
- Symptomatic Severe Aortic Regurgitation
  - >10%/year mortality rate

Bonow RO, Carabello BA, Chatterjee K, de Leon AC Jr, Faxon DP, Freed MD, Gaasch WH, Lytle BW, Nishimura RA, O'Gara PT, O'Rourke RA, Otto CM, Shah PM, Shanewise JS; American College of Cardiology/American Heart Association Task Force on Practice Guidelines. 2008 focused update incorporated into the ACC/AHA 2006 guidelines for the management of patients with valvular heart disease: a report of the American College of Cardiology/American Heart Association Task Force on Practice Guidelines (Writing Committee to revise the 1998 guidelines for the management of patients with valvular heart disease). Endorsed by the Society of Cardiovascular Anesthesiologists, Society for Cardiovascular Angiography and Interventions, and Society of Thoracic Surgeons. J Am Coll Cardiol. 2008 Sep 23;52(13):e1-142

# Conclusion

- Case illustrations of decision making for
  - Asymptomatic severe aortic stenosis
  - Moderate bicuspid aortic stenosis with aortic root dilatation
  - Asymptomatic severe aortic regurgitation
- Symptoms + Severe AS or AR = Surgery
- No clear medical management
  - Consider Beta blockers for aortic root dilatation
  - Statins for mild-moderate aortic stenosis?

# References

Bonow RO, Carabello BA, Chatterjee K, de Leon AC Jr, Faxon DP, Freed MD, Gaasch WH, Lytle BW, Nishimura RA, O'Gara PT, O'Rourke RA, Otto CM, Shah PM, Shanewise JS; American College of Cardiology/American Heart Association Task Force on Practice Guidelines. 2008 focused update incorporated into the ACC/AHA 2006 guidelines for the management of patients with valvular heart disease: a report of the American College of Cardiology/American Heart Association Task Force on Practice Guidelines (Writing Committee to revise the 1998 guidelines for the management of patients with valvular heart disease). Endorsed by the Society of Cardiovascular Anesthesiologists, Society for Cardiovascular Angiography and Interventions, and Society of Thoracic Surgeons. J Am Coll Cardiol. 2008 Sep 23;52(13):e1-142.

Borer JS, Hochreiter C, Herrold EM, Supino P, Aschermann M, Wencker D, Devereux RB, Roman MJ, Szulc M, Kligfield P, Isom OW. Prediction of indications for valve replacement among asymptomatic or minimally symptomatic patients with chronic aortic regurgitation and normal left ventricular performance. Circulation. 1998 Feb 17;97(6):525-34.

Cowell SJ, Newby DE, Prescott RJ, et al: A randomized trial of intensive lipid-lowering therapy in calcific aortic stenosis. *N Engl J Med* 2005; 352:2389.

Moura LM, Ramos SF, Zamorano JL, et al: Rosuvastatin Affective Aortic Valve Endothelium to slow the progression of aortic stenosis. *J Am Coll Cardiol* 2007; 49:554.

Pellikka PA, Sarano ME, Nishimura RA, et al. Outcome of 622 adults with asymptomatic, hemodynamically significant aortic stenosis during prolonged follow-up. Circulation 2005;111:3290 –5.

Rafique AM, Biner S, Ray I, Forrester JS, Tolstrup K, Siegel RJ. Meta-analysis of prognostic value of stress testing in patients with asymptomatic severe aortic stenosis. Am J Cardiol. 2009 Oct 1;104(7):972-7.